

Hospital Universitario Politécnico La Fe

Presentación de un caso clínico.

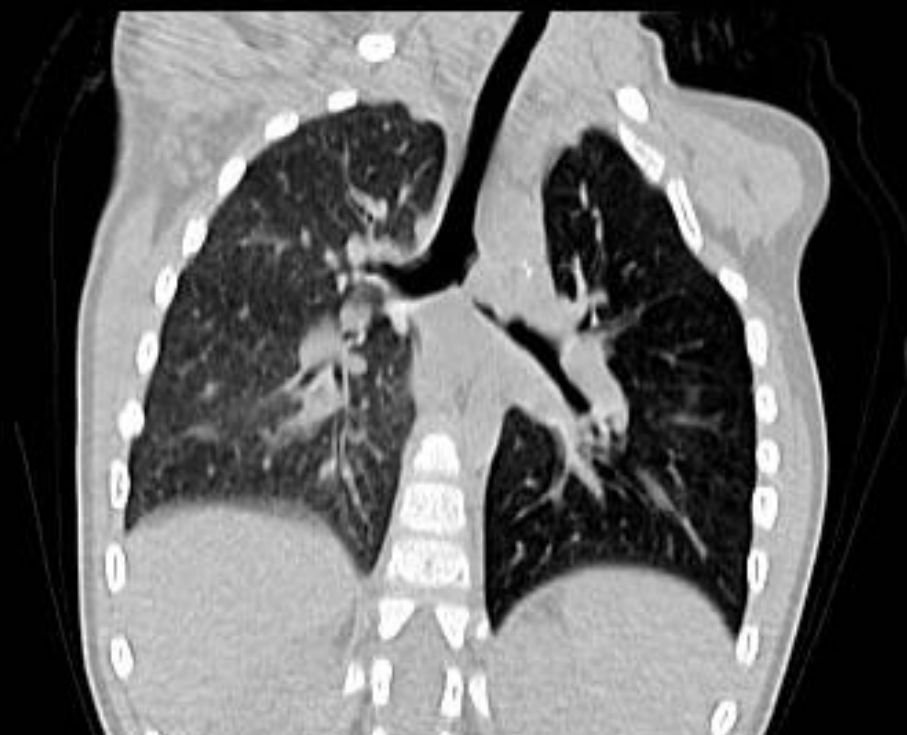

Latouche María Fernanda.
Servicio de Anatomía Patológica.

PID:6289866
22/06/2006
003Y
F

02/03/2010
02:04:18
SE:1000
IM:1

R
P
S



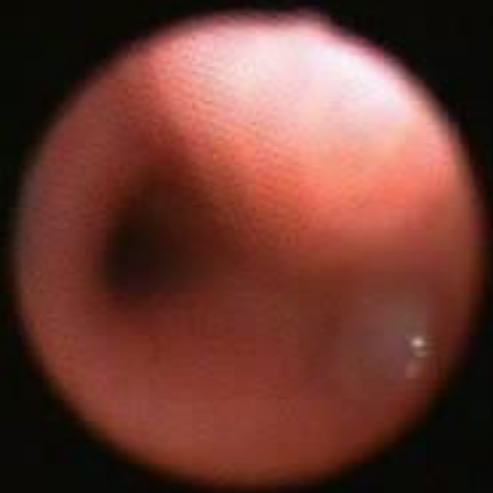L
A
I

E.R.E.S.A.
Station:CTS1_OC0

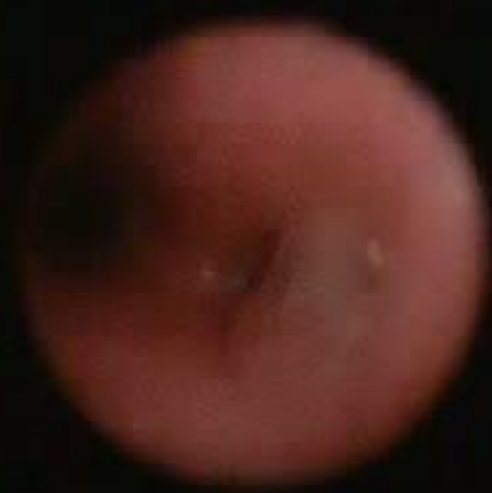Cambio de formato multiplanar
IP TAC TORAX

Datos Clínicos

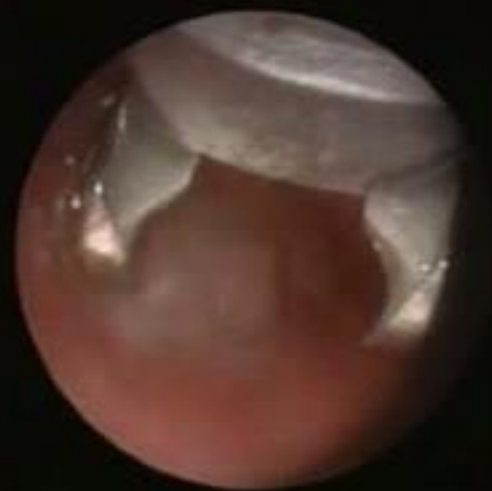Paciente de 3
años de edad.



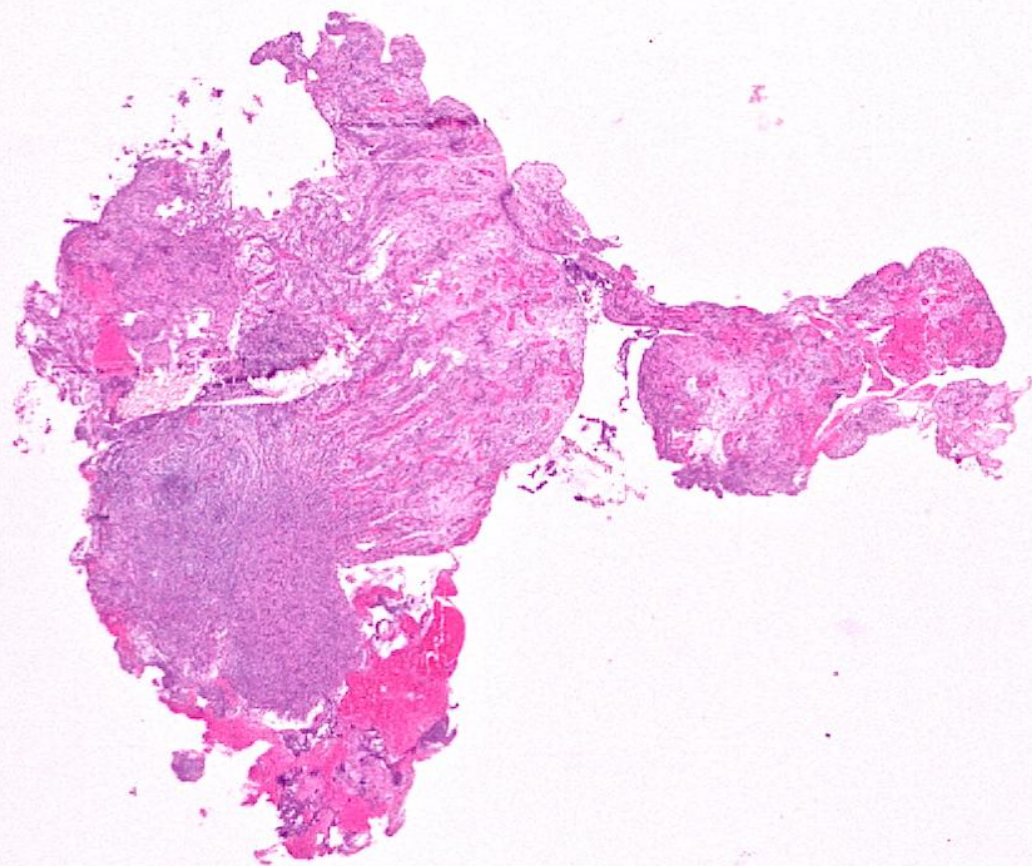
Obstrucción del BPI

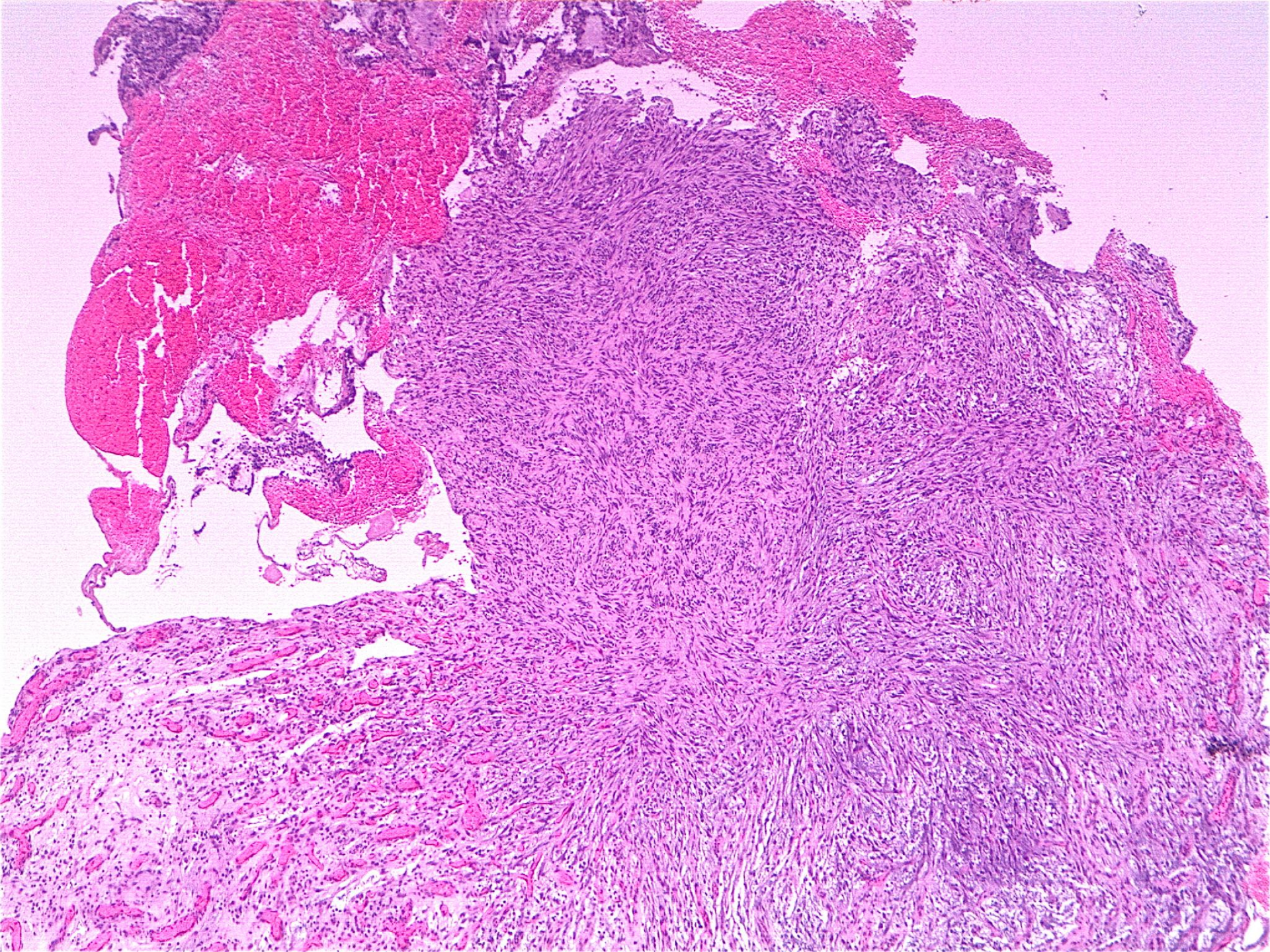


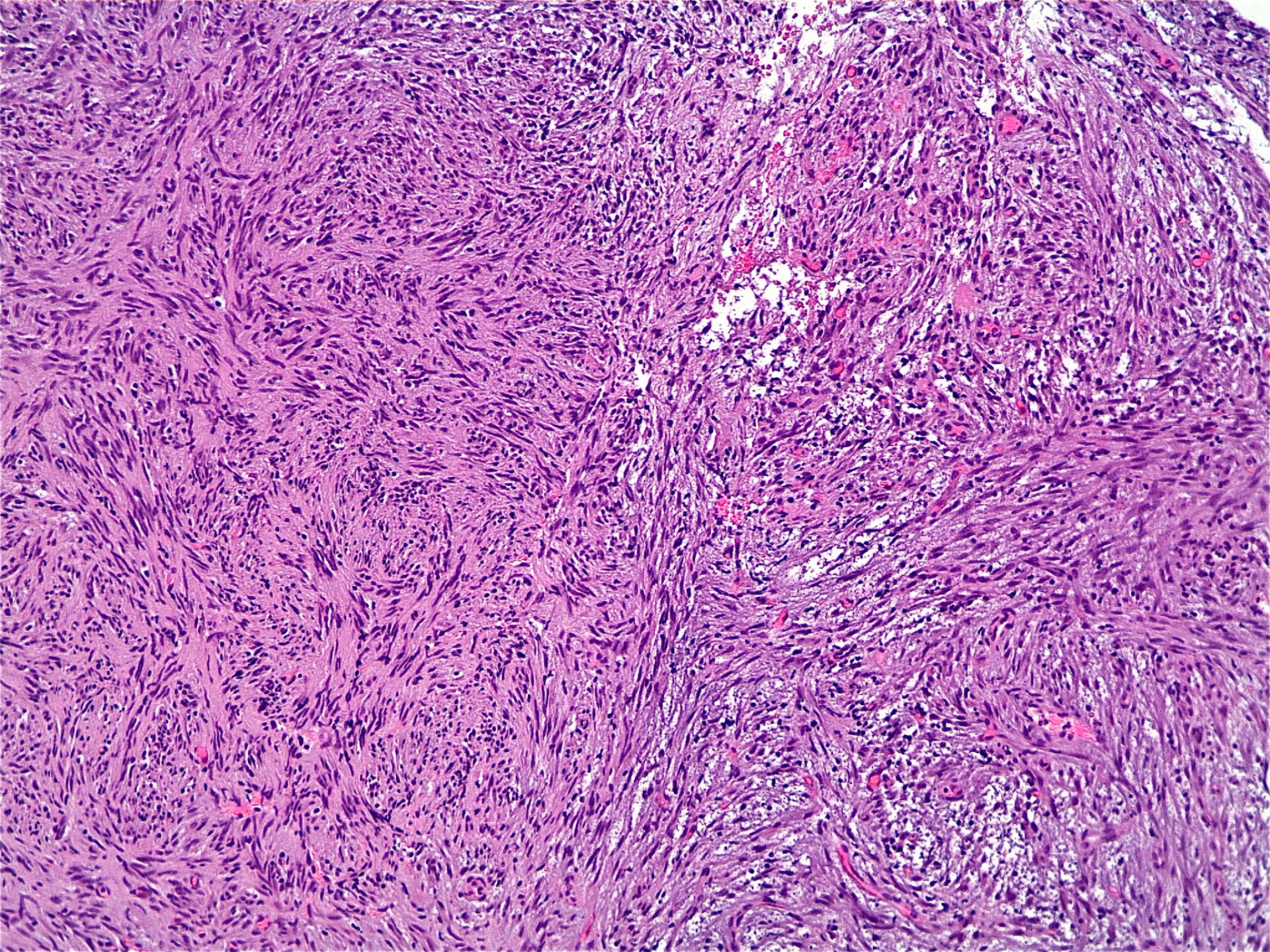
FIBROBRONCOSCOPIA

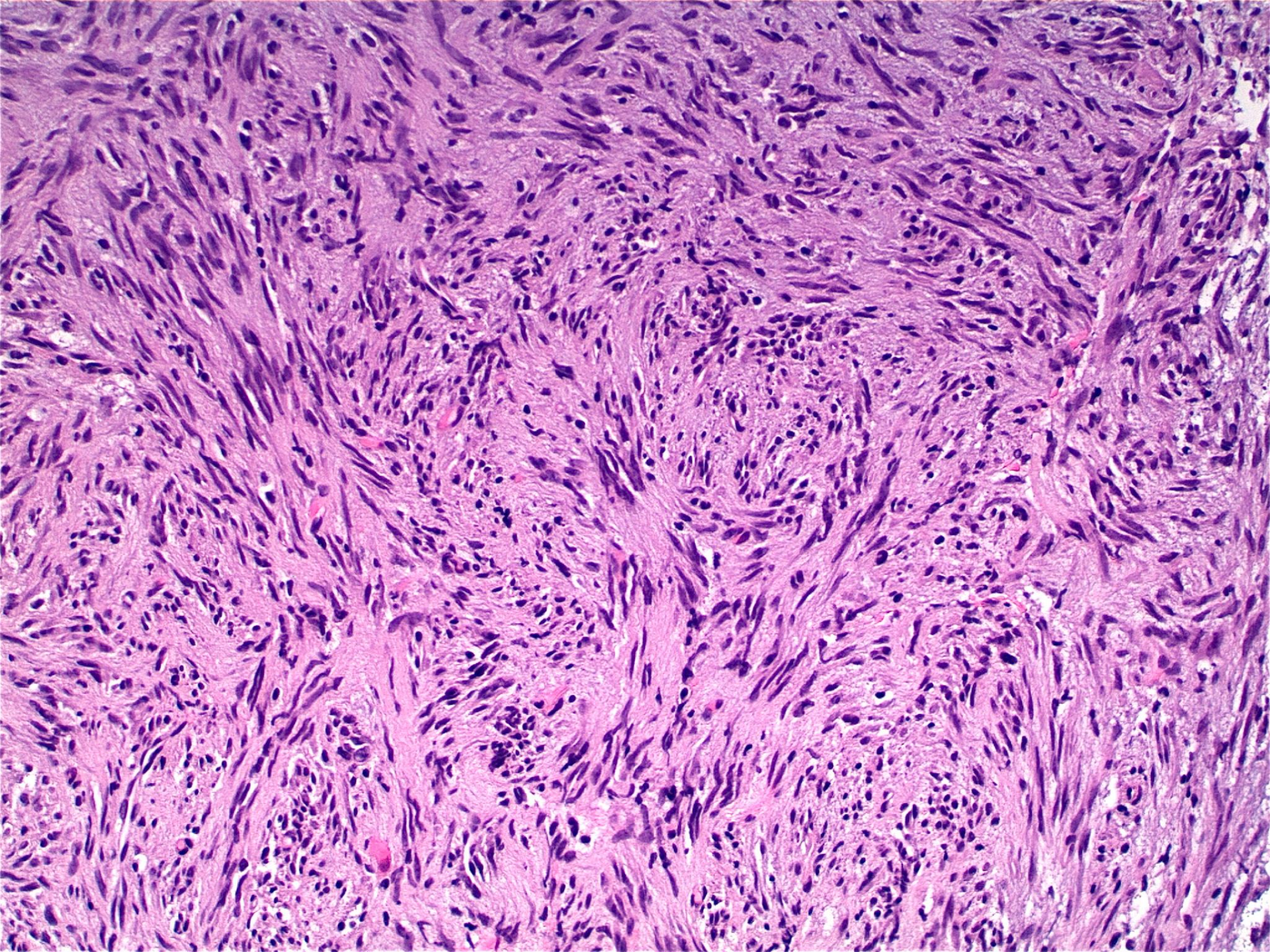


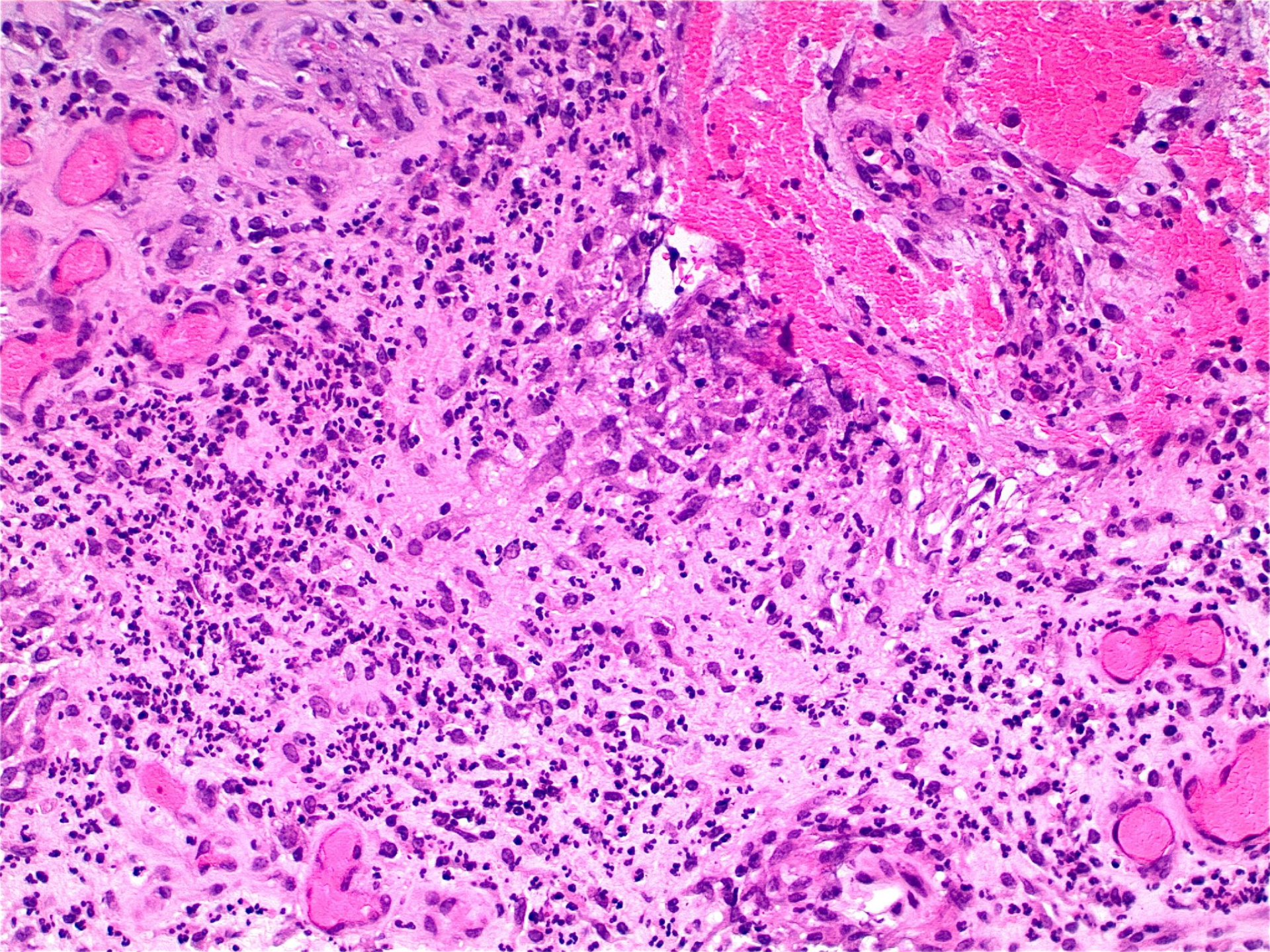
BIOPSIA

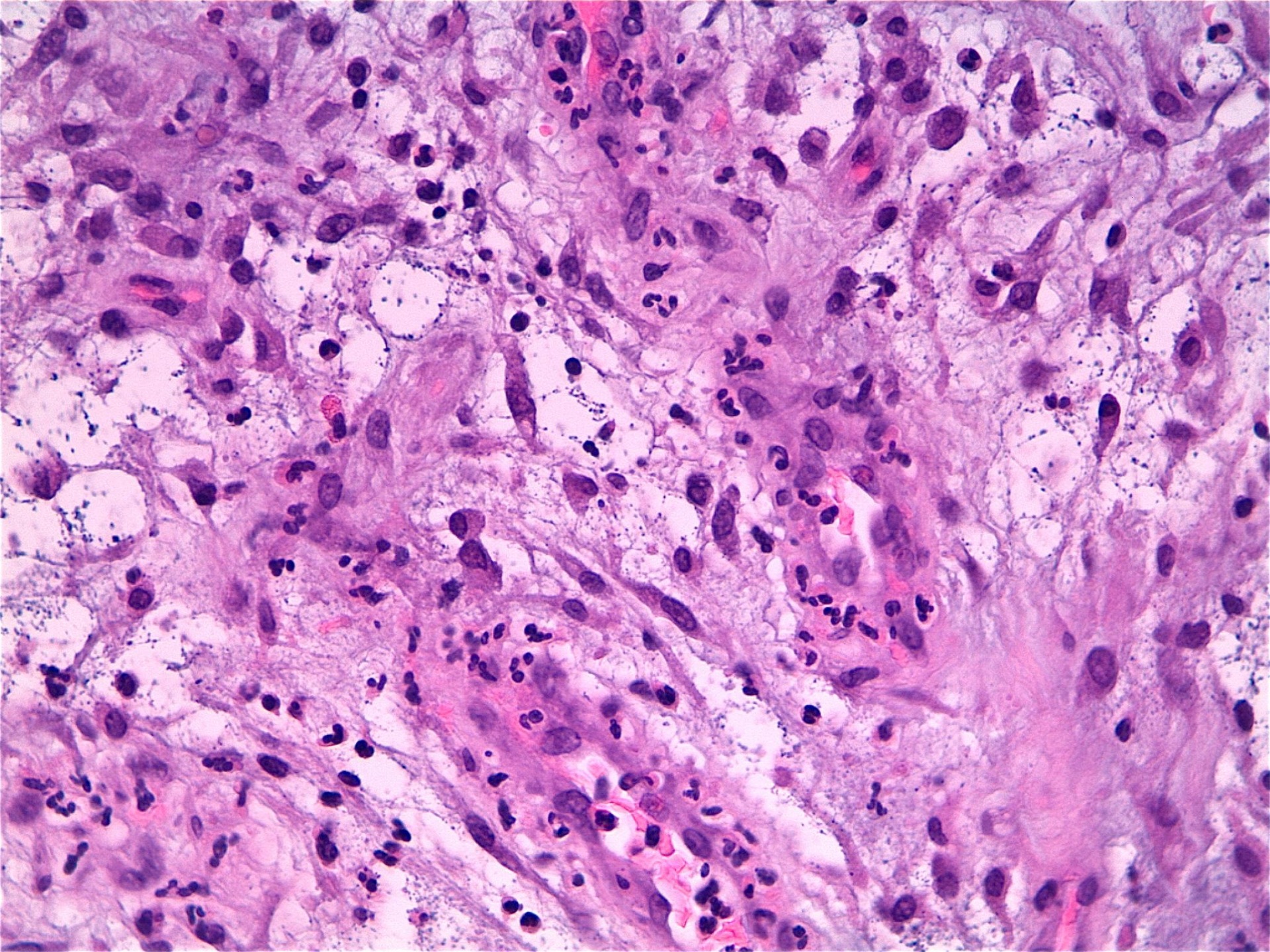


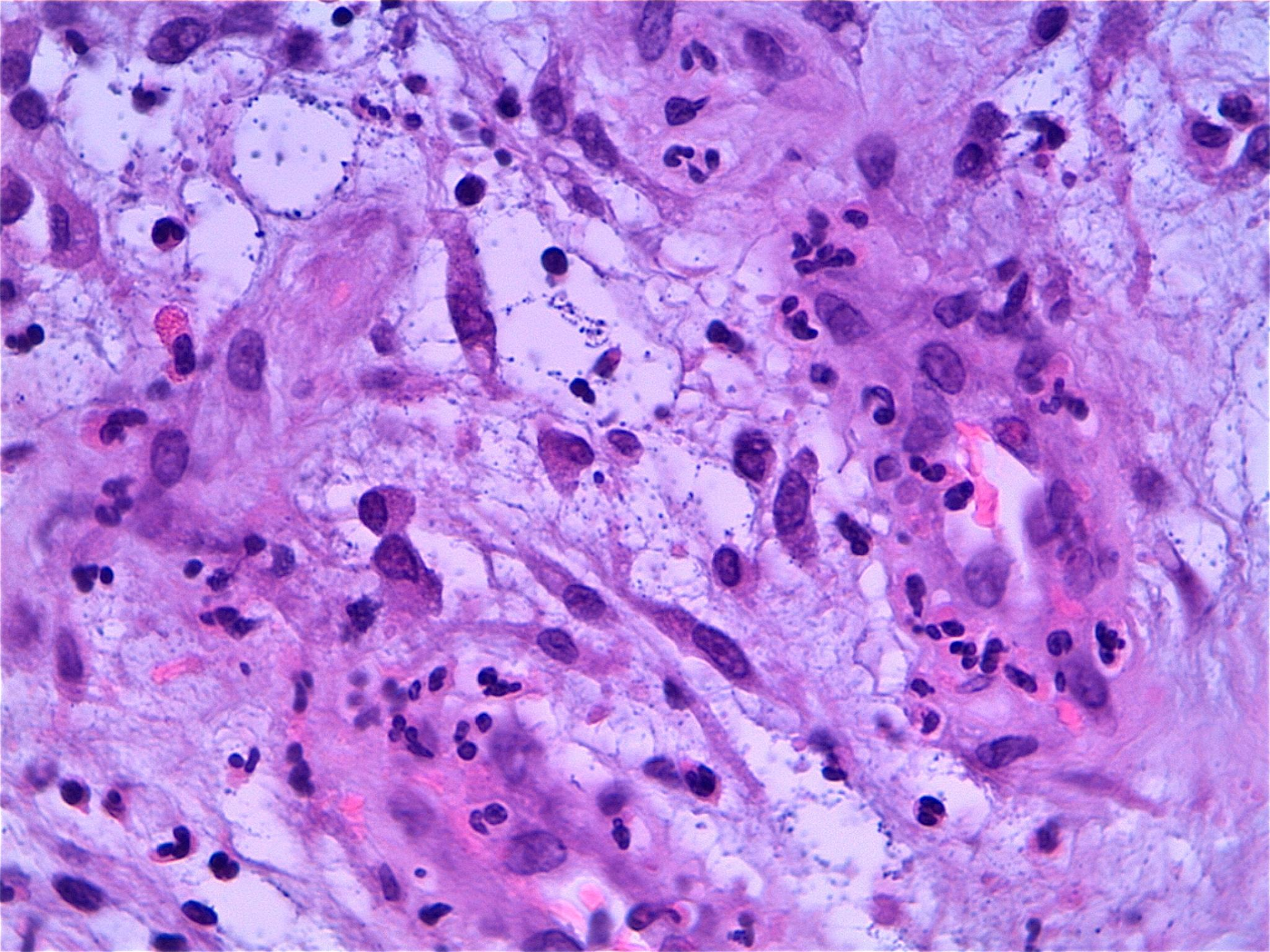


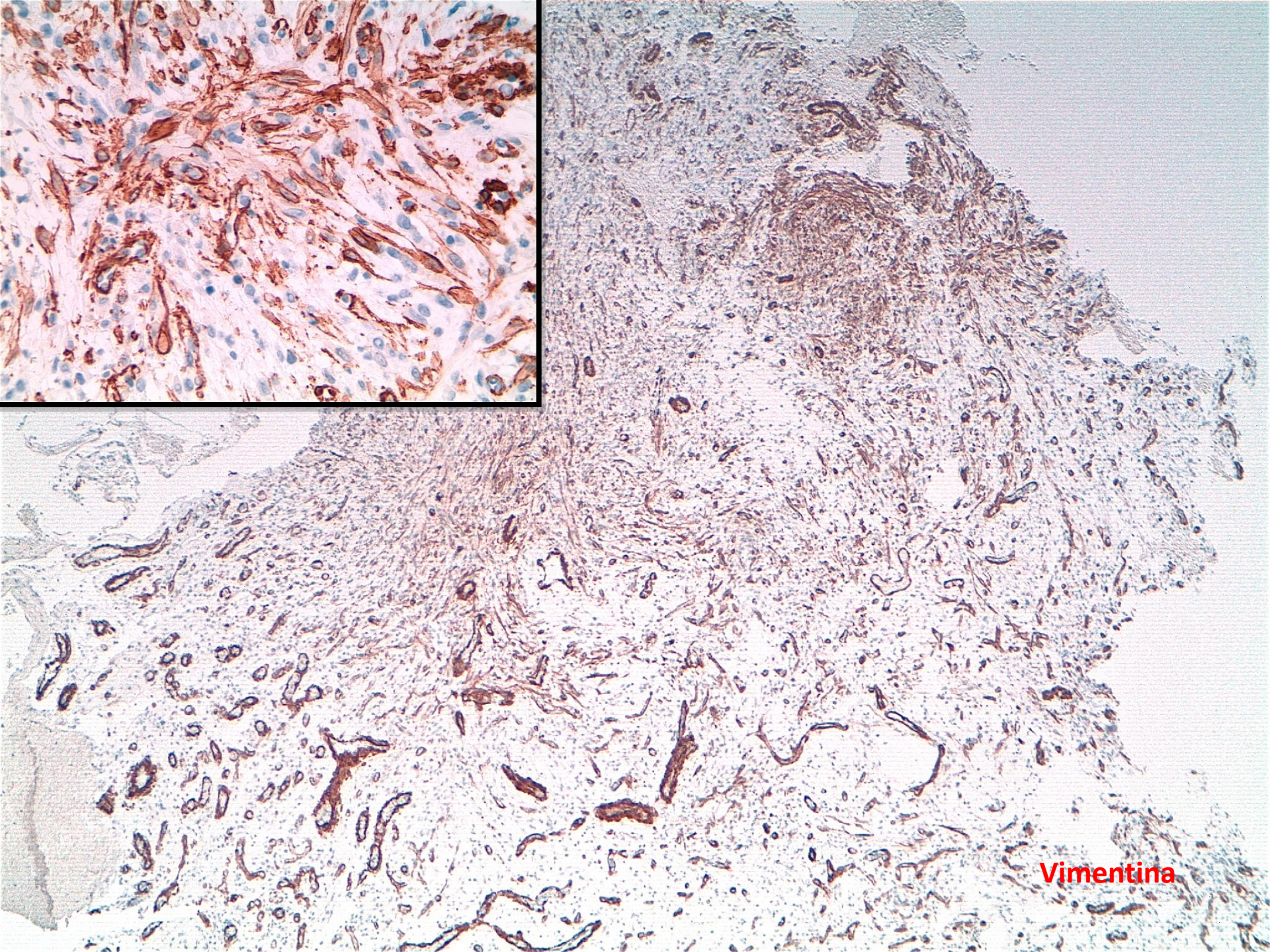
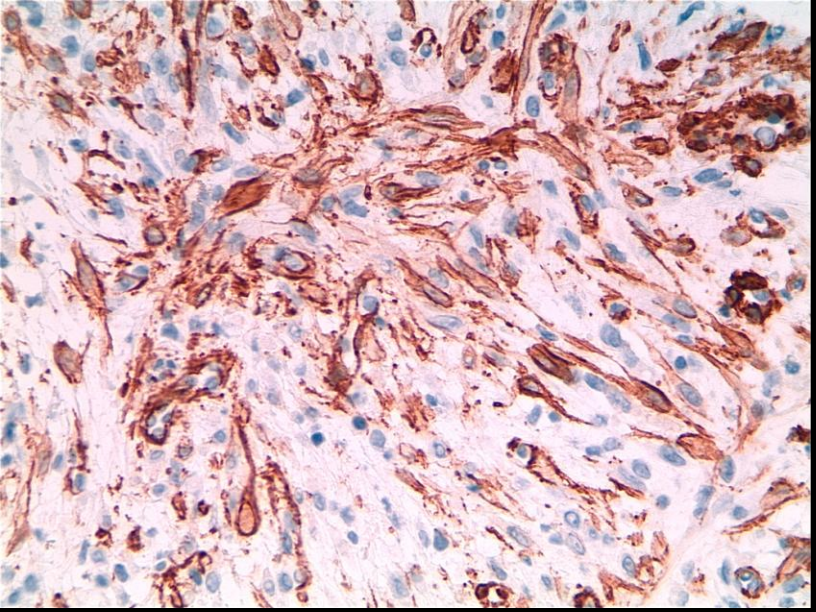




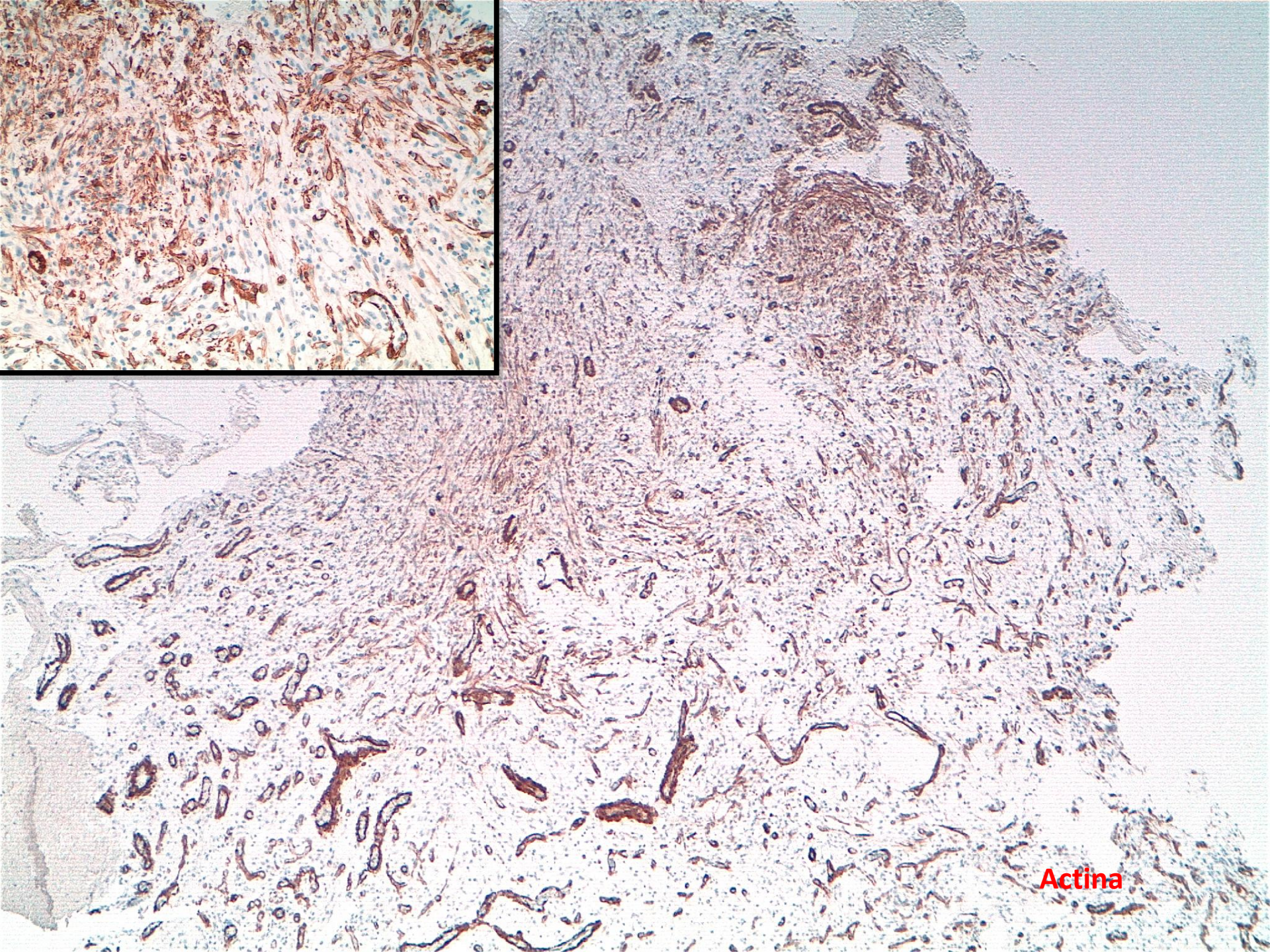
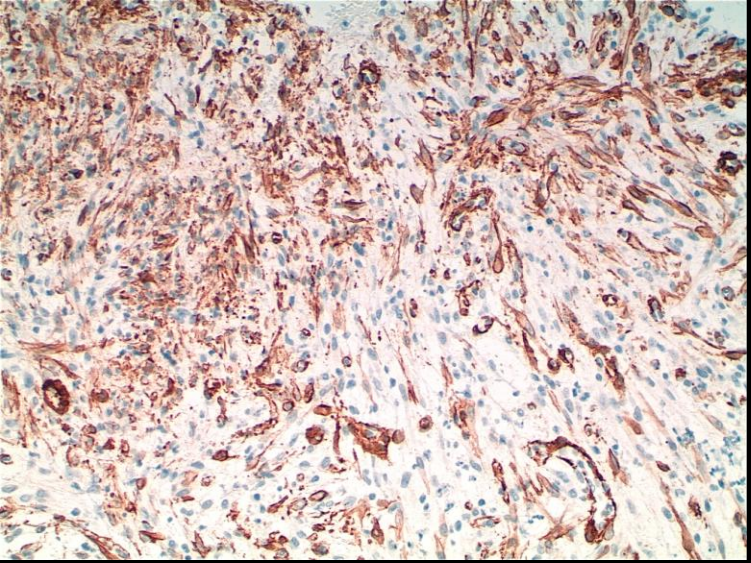




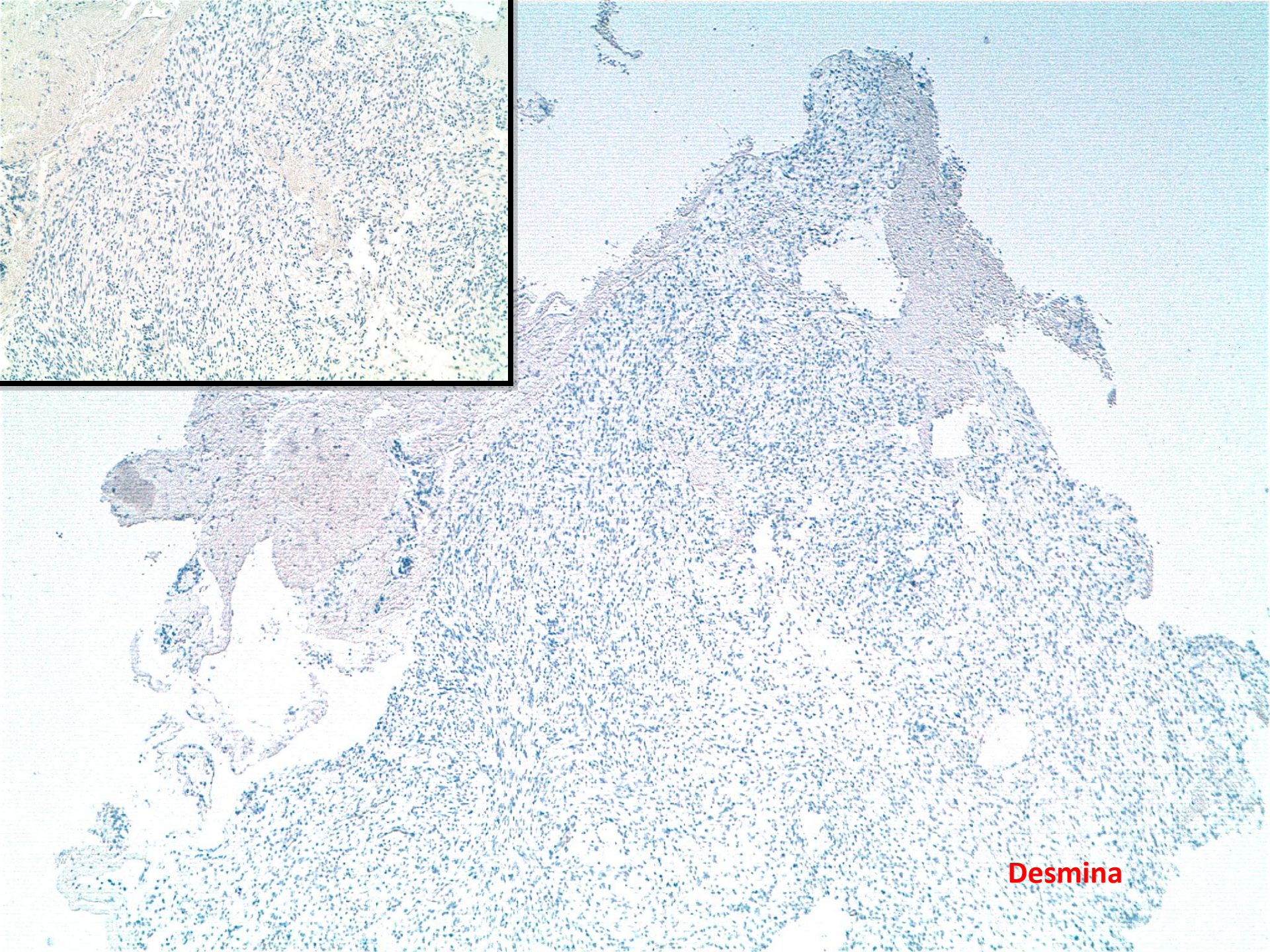
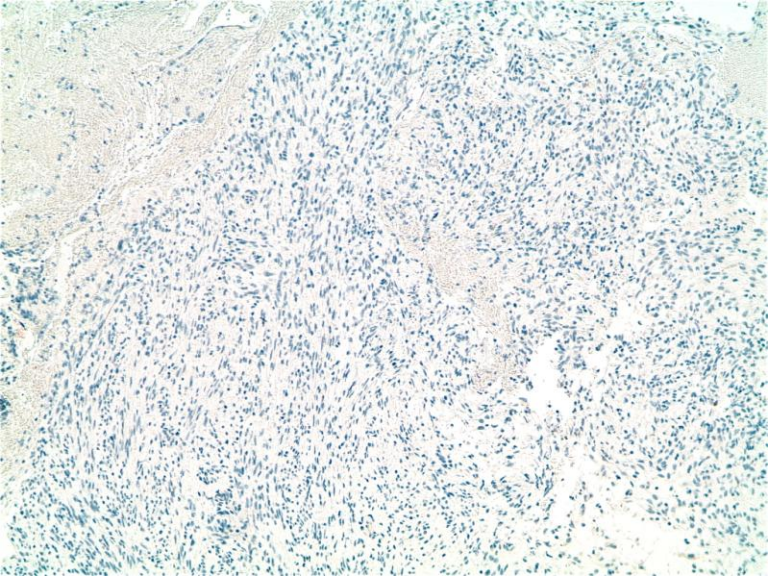




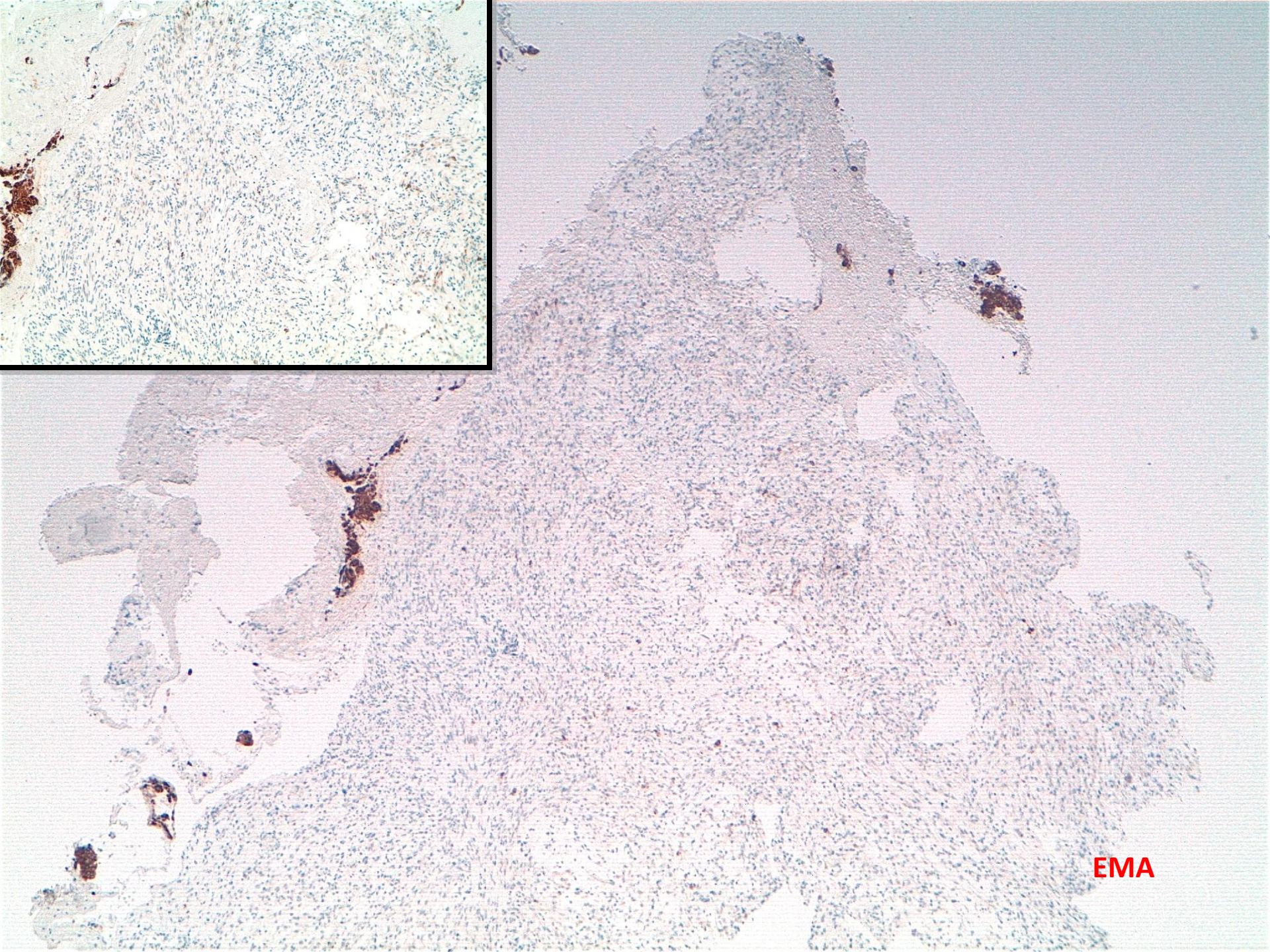
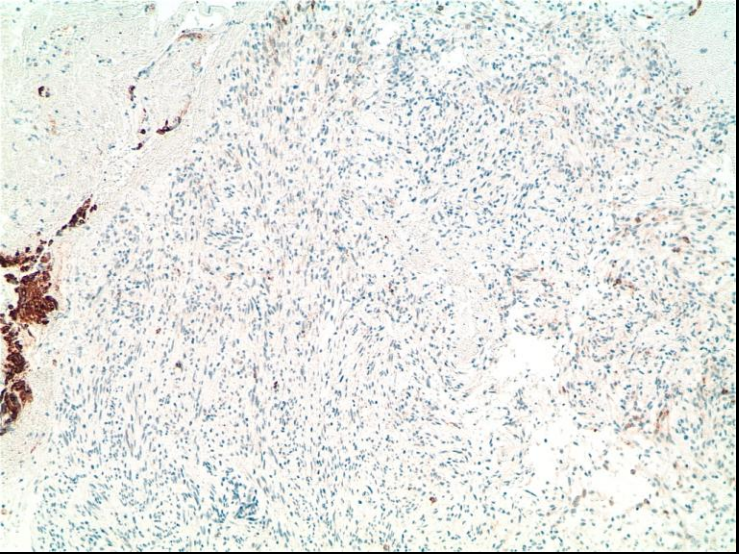
Vimentina



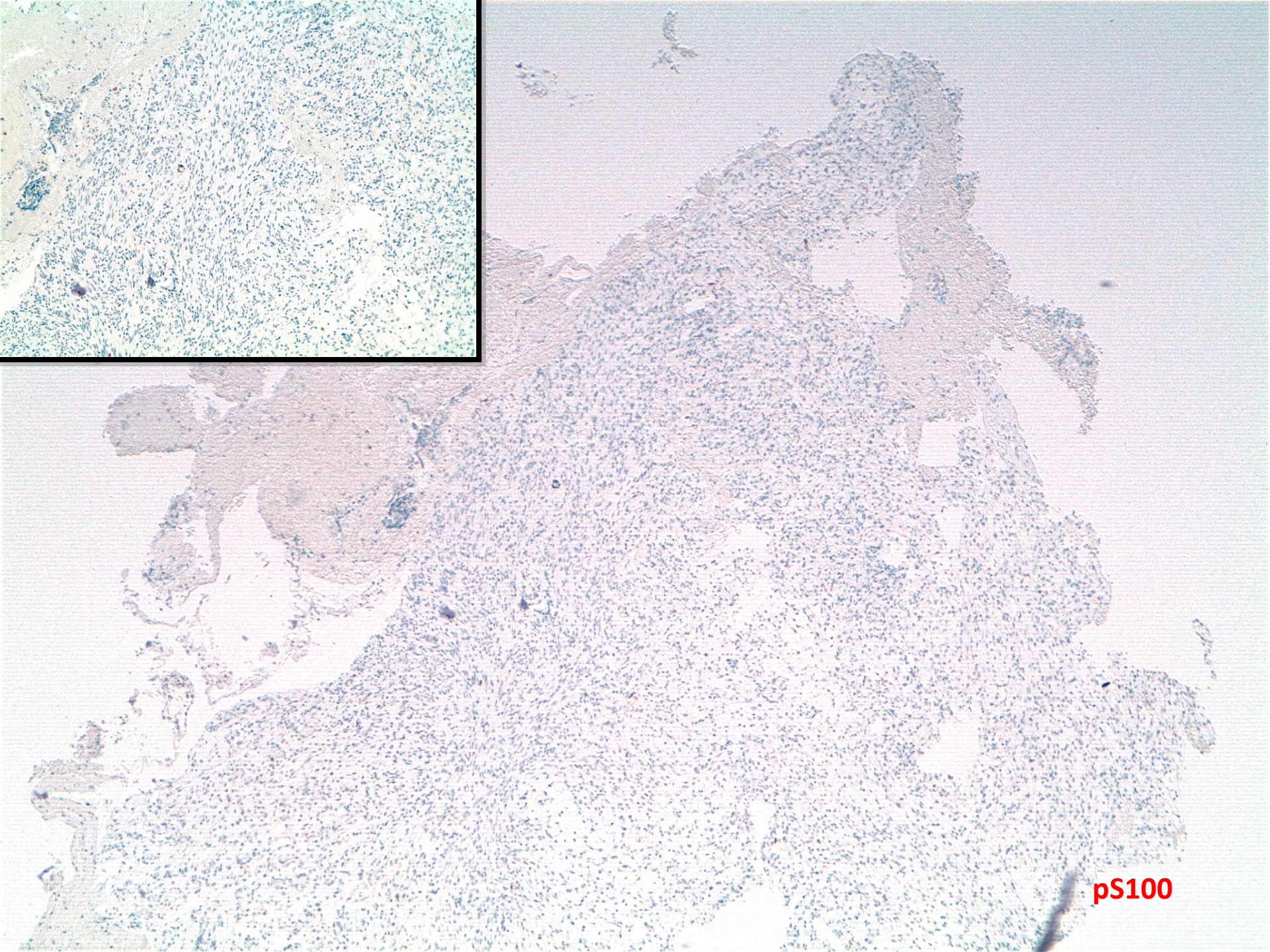
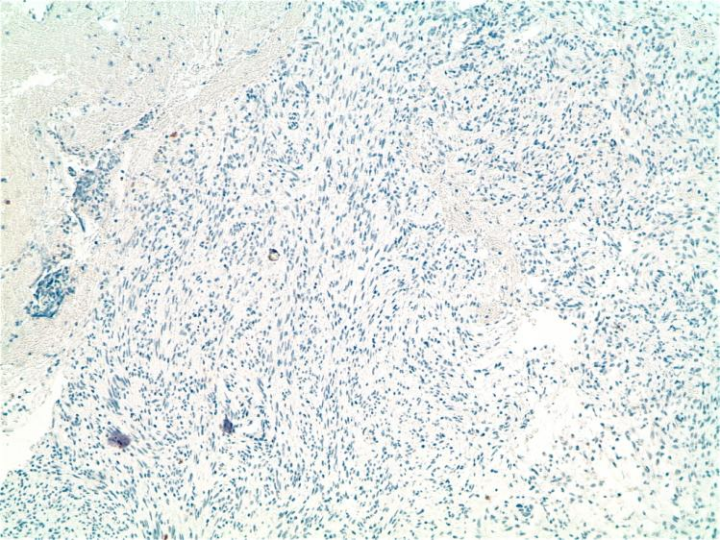
Actina



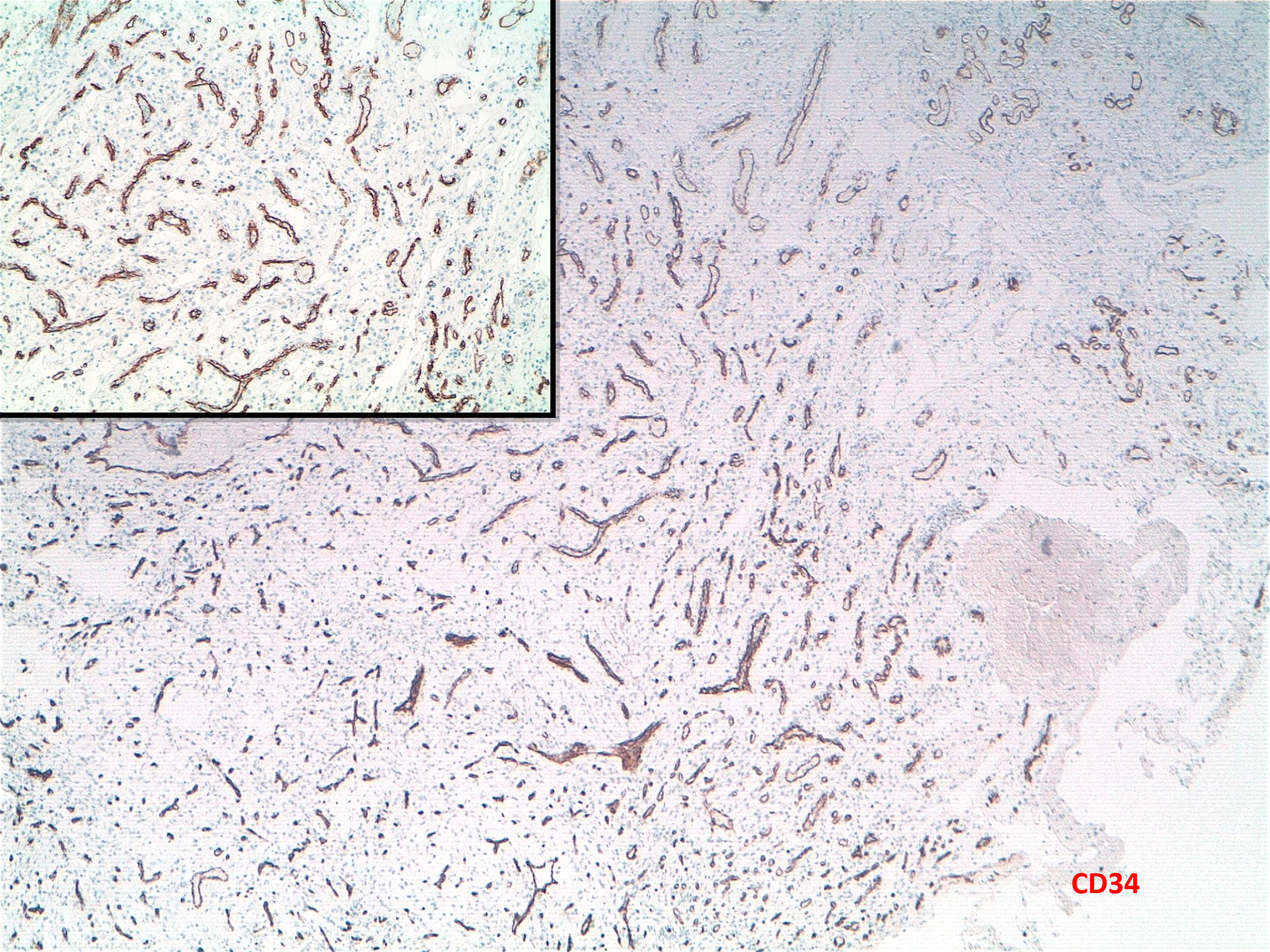
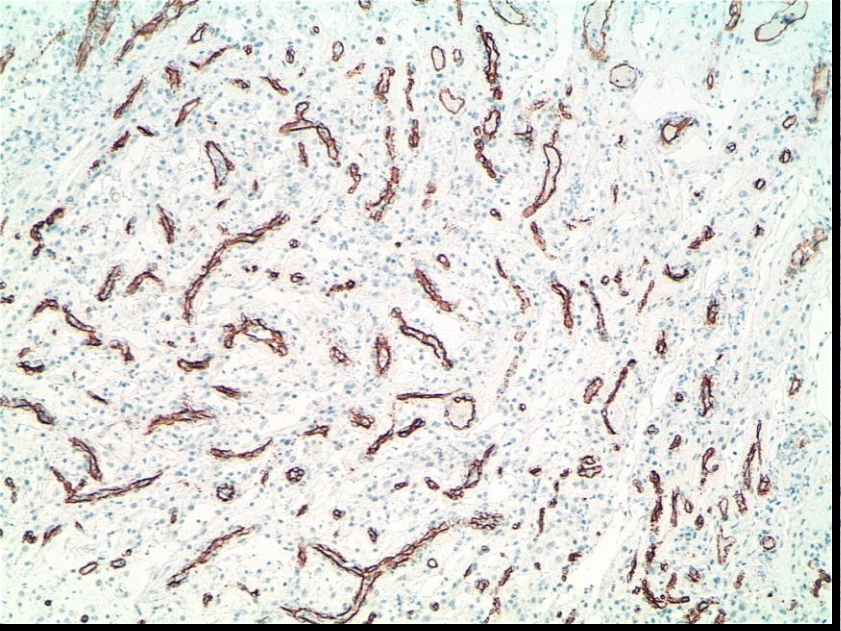
Desmina



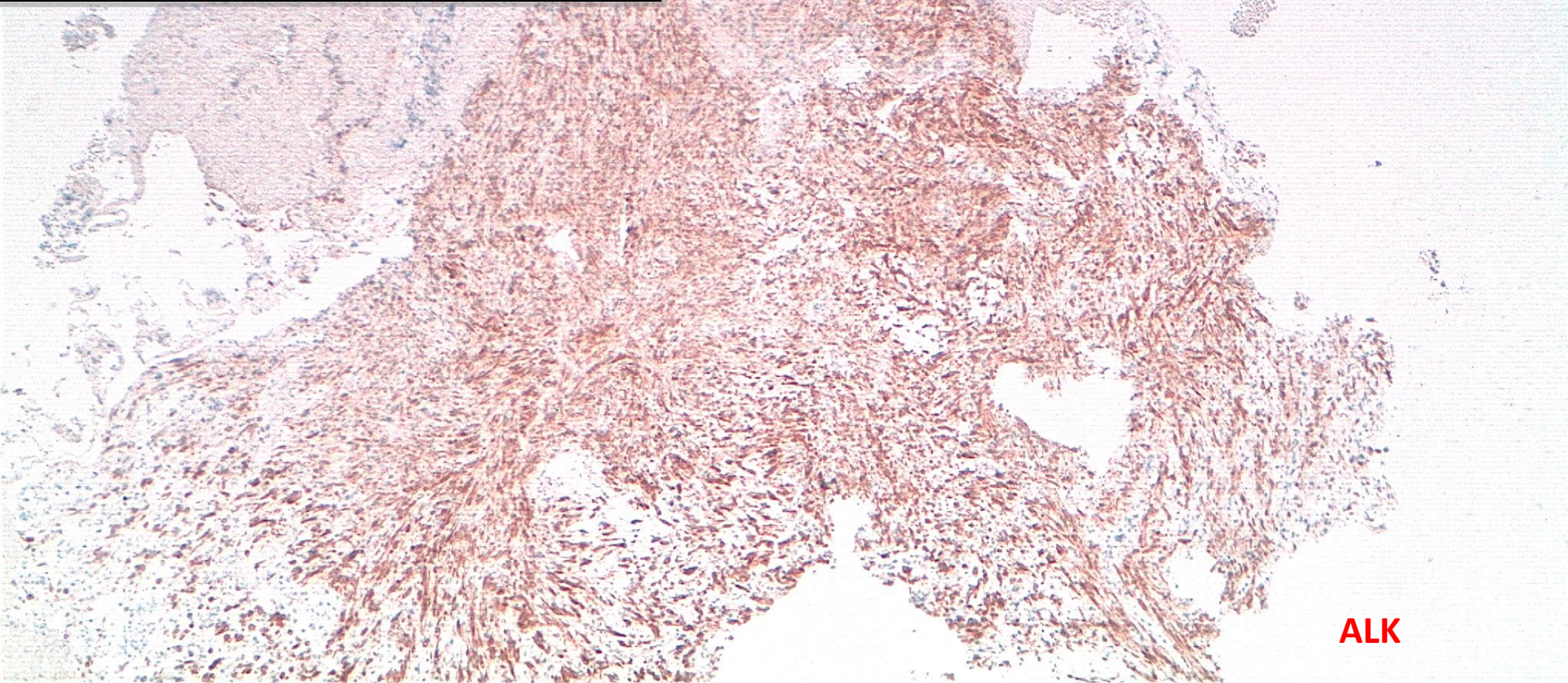
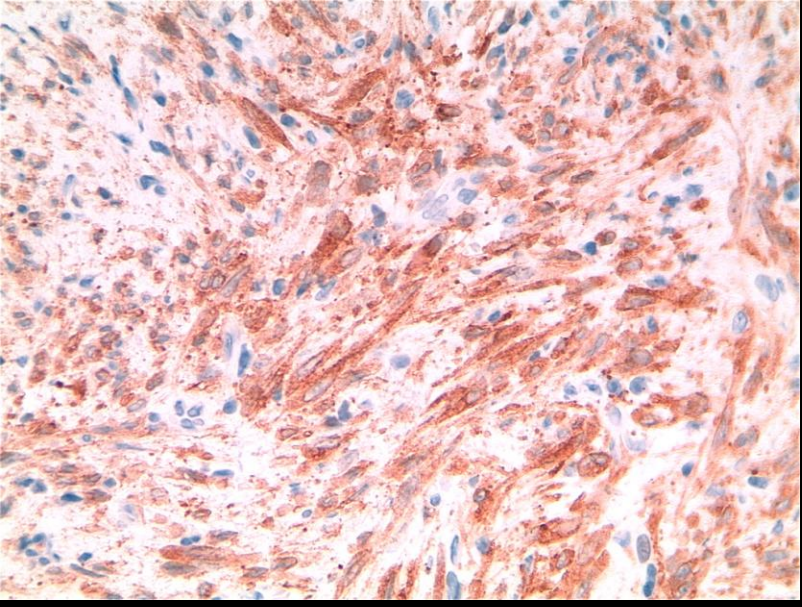
EMA



pS100



CD34



ALK

Tumor miofibroblástico
inflamatorio endobronquial.