Caso 10

Cristina Alenda
Hospital General Universitario de Alicante
SEAP Vinaroz, diciembre 2003

Varón de 79 años

Nódulo palpable en mama izquierda

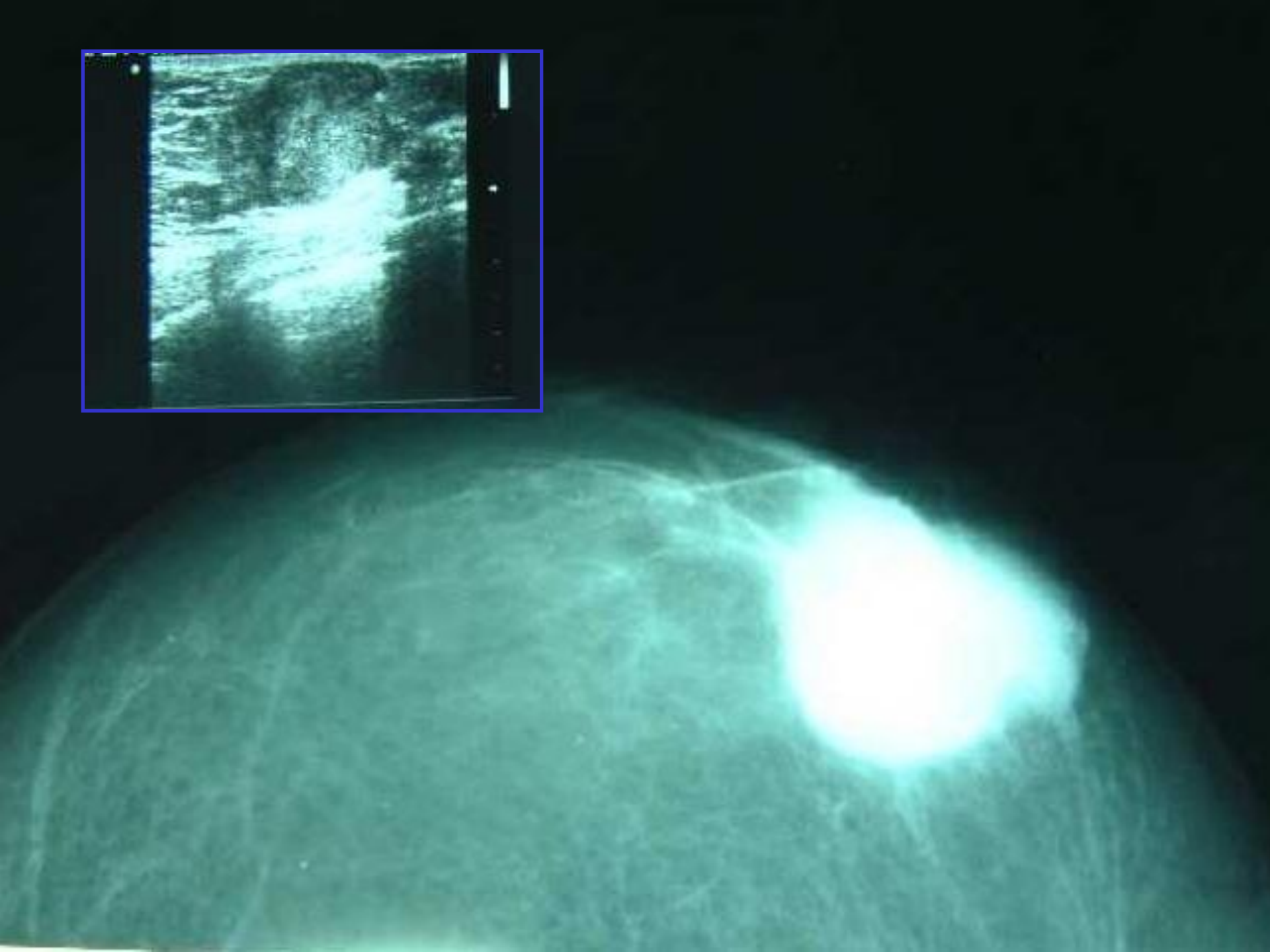

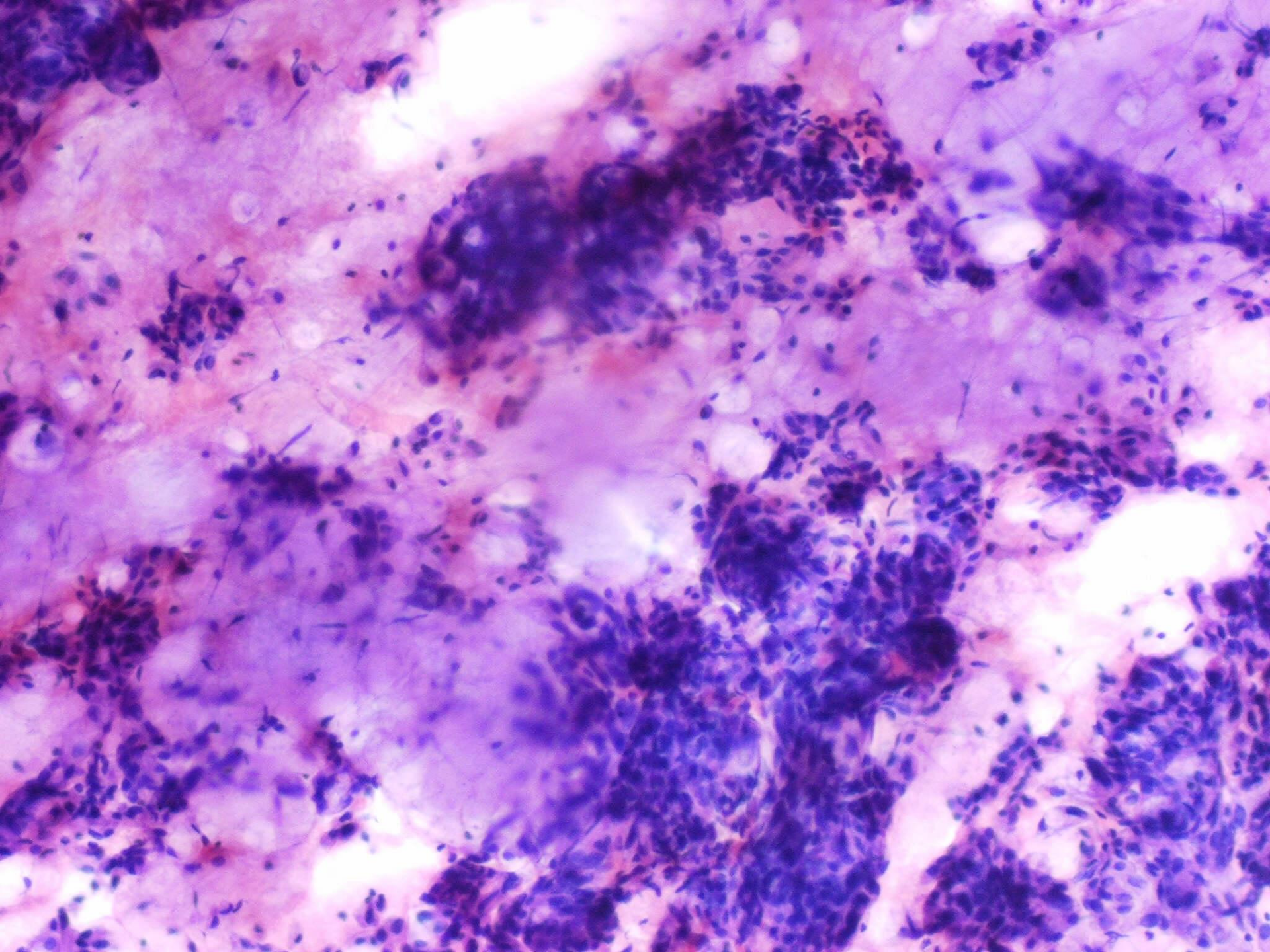

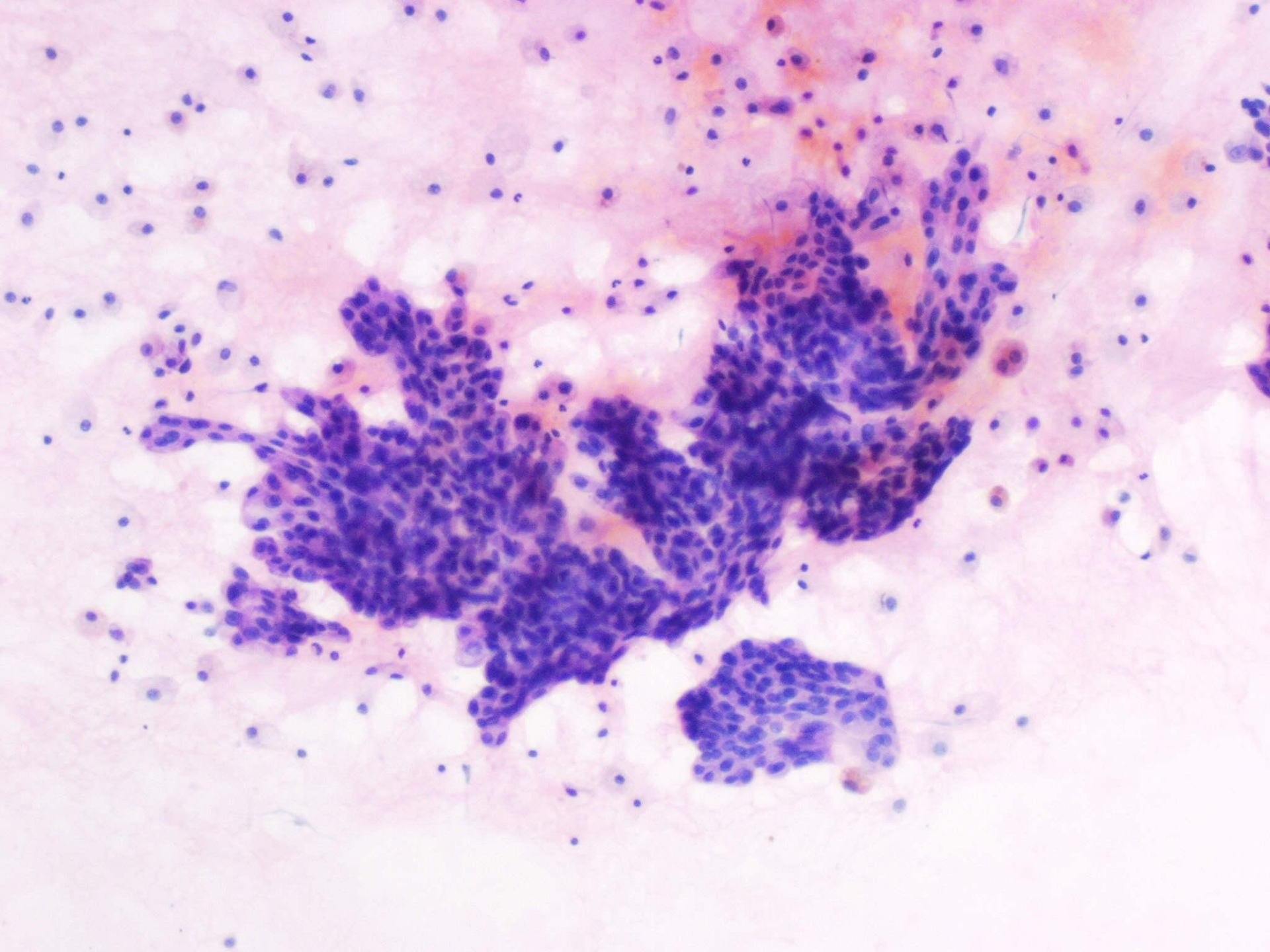

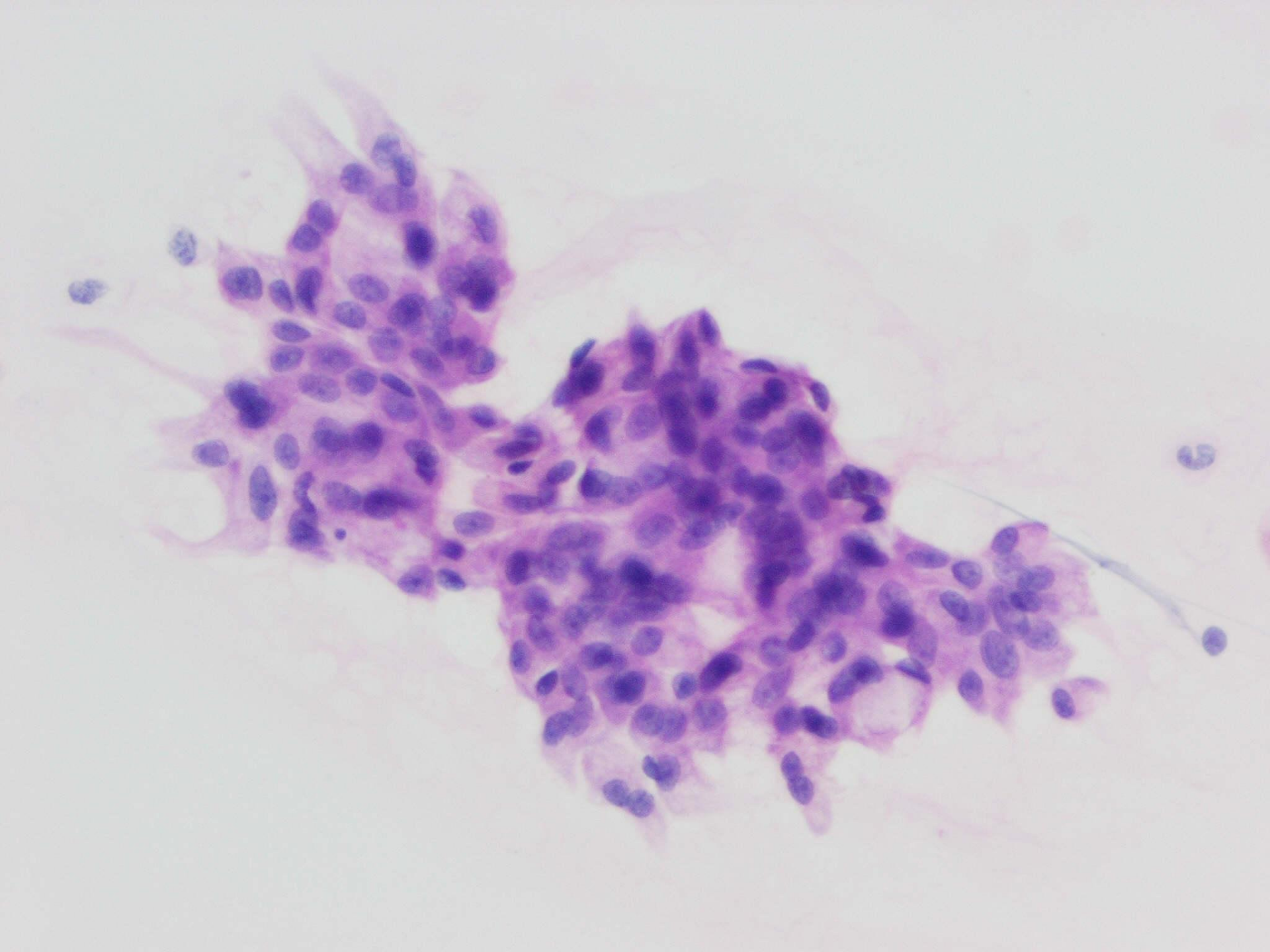

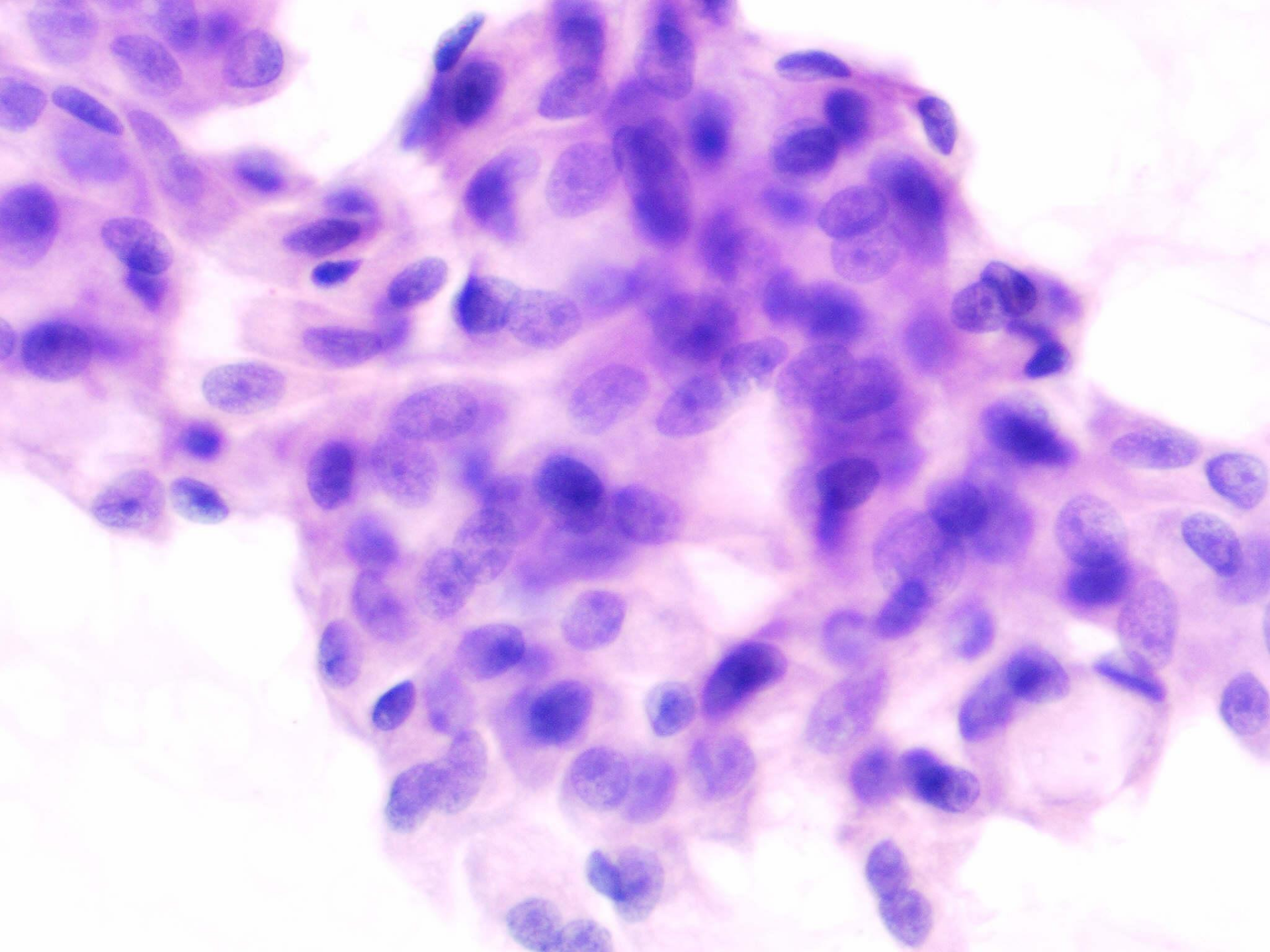

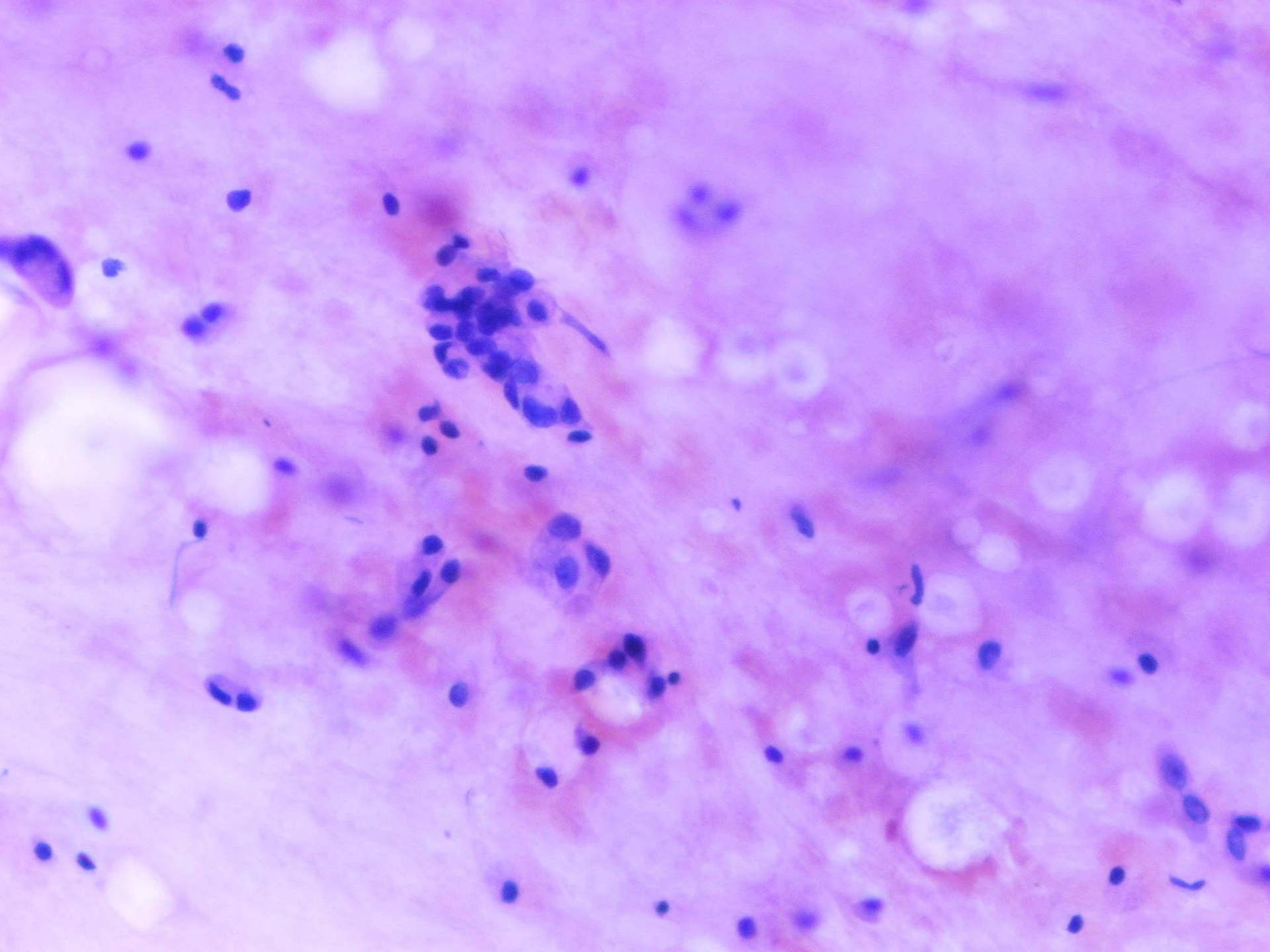

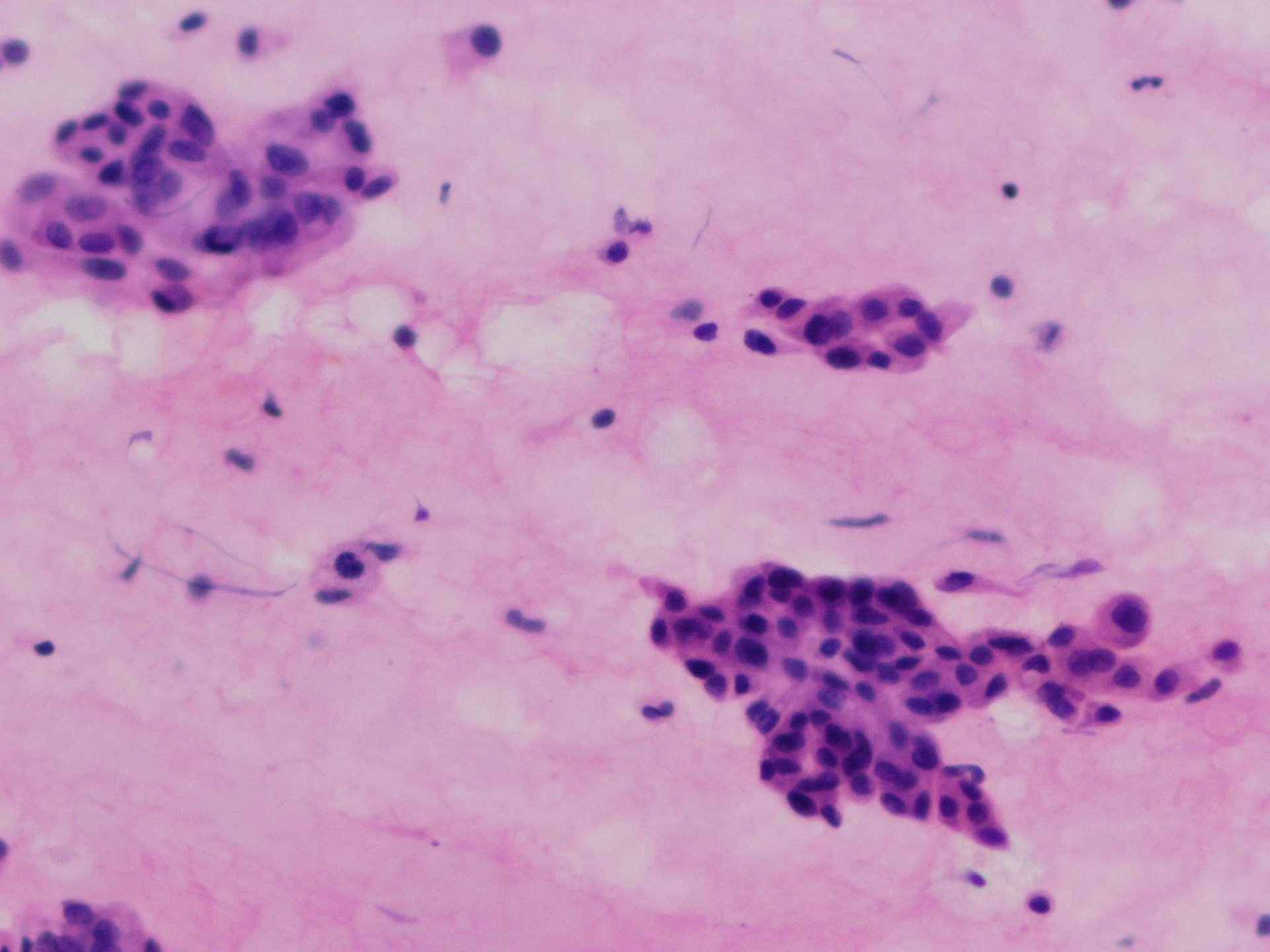

Proliferación epitelial.
Se recomienda extirpación.

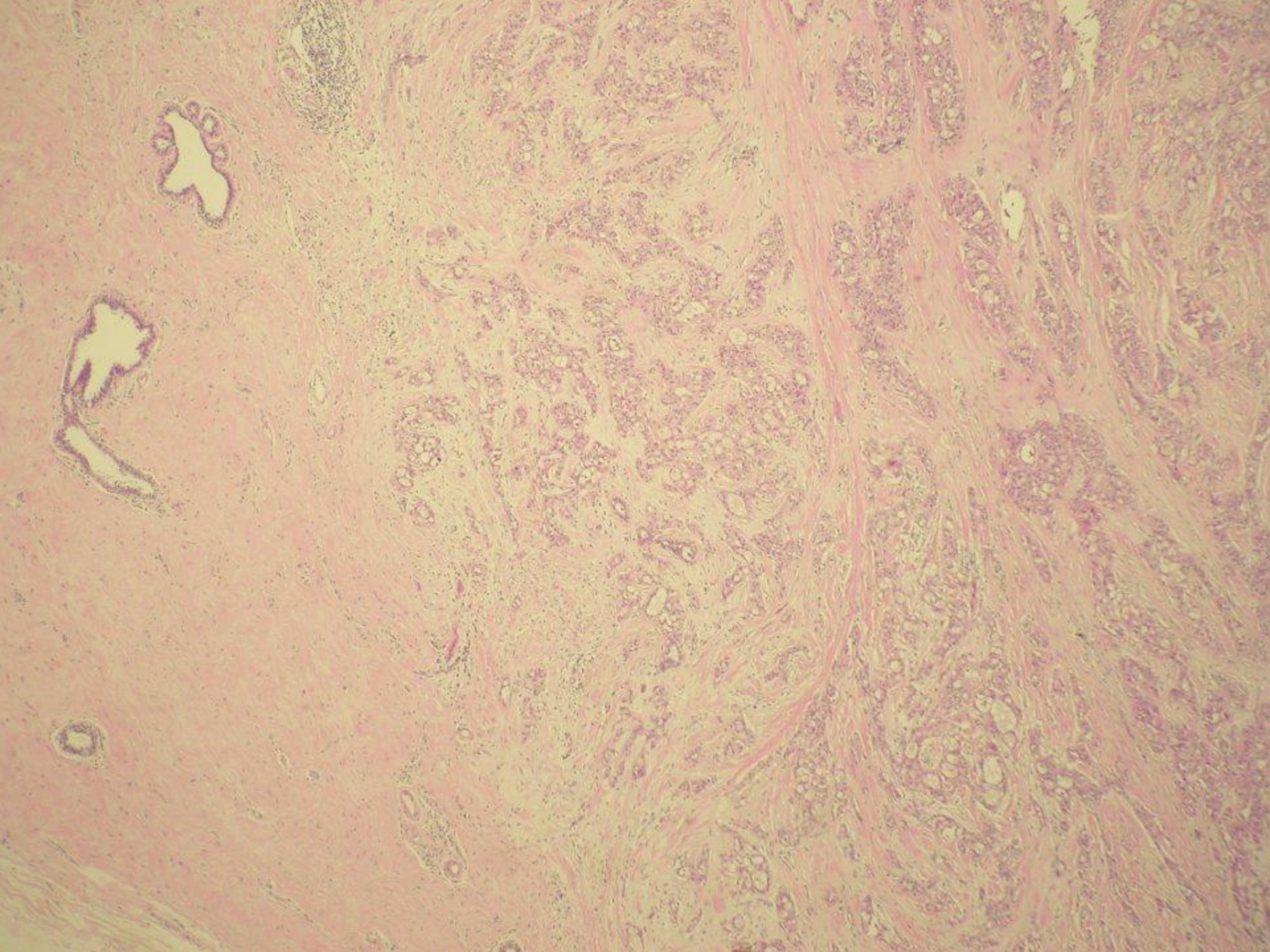

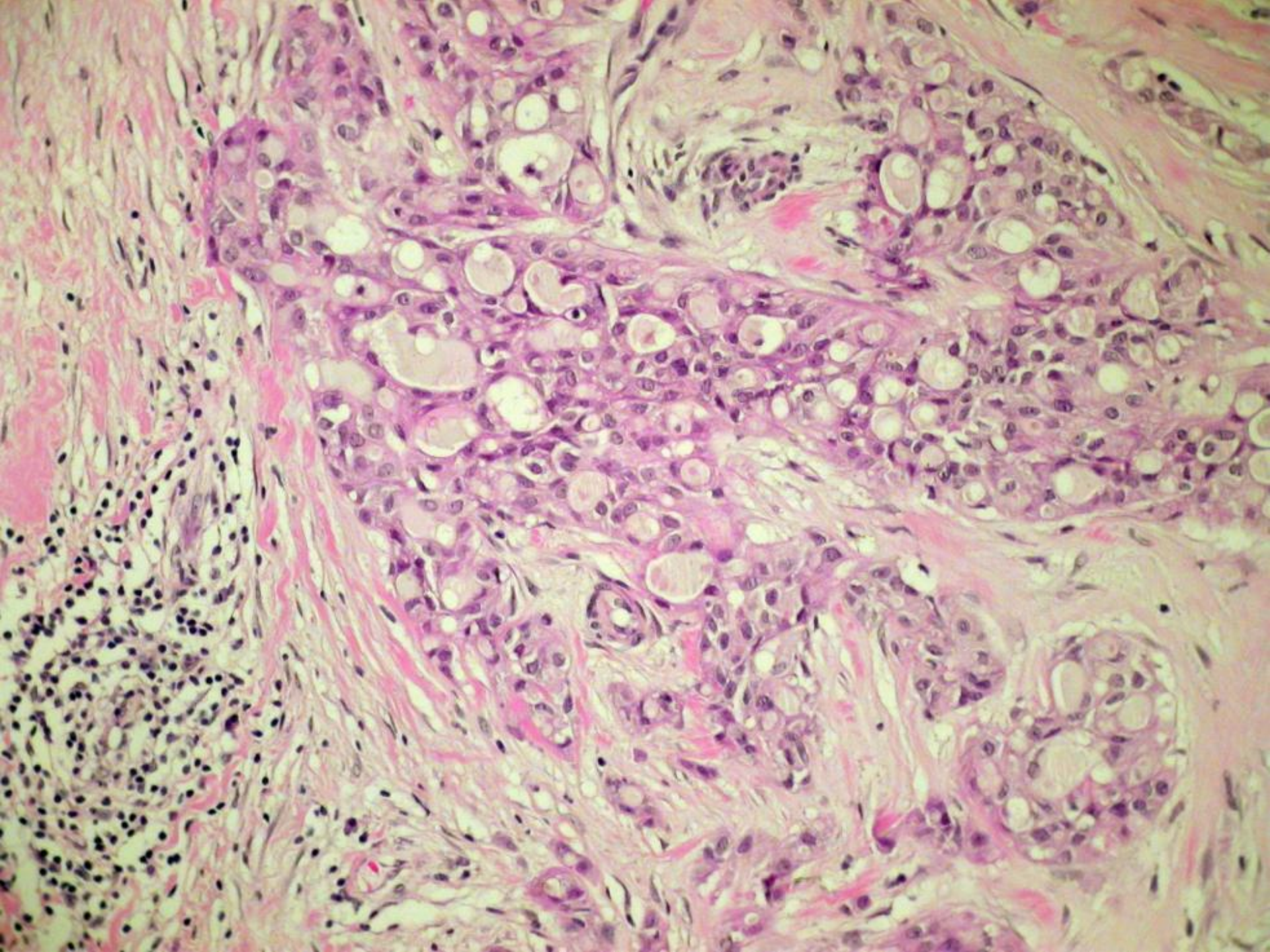

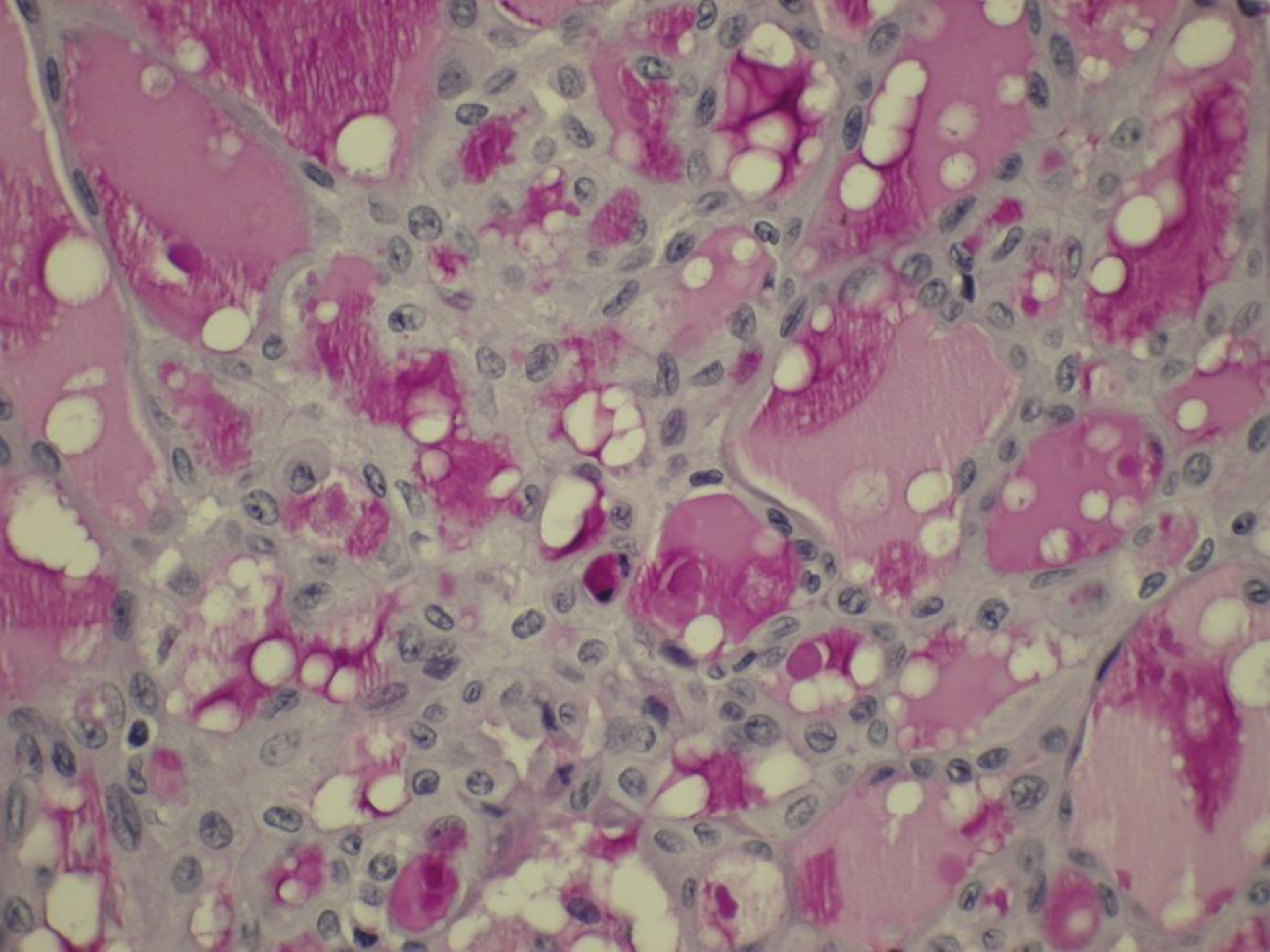

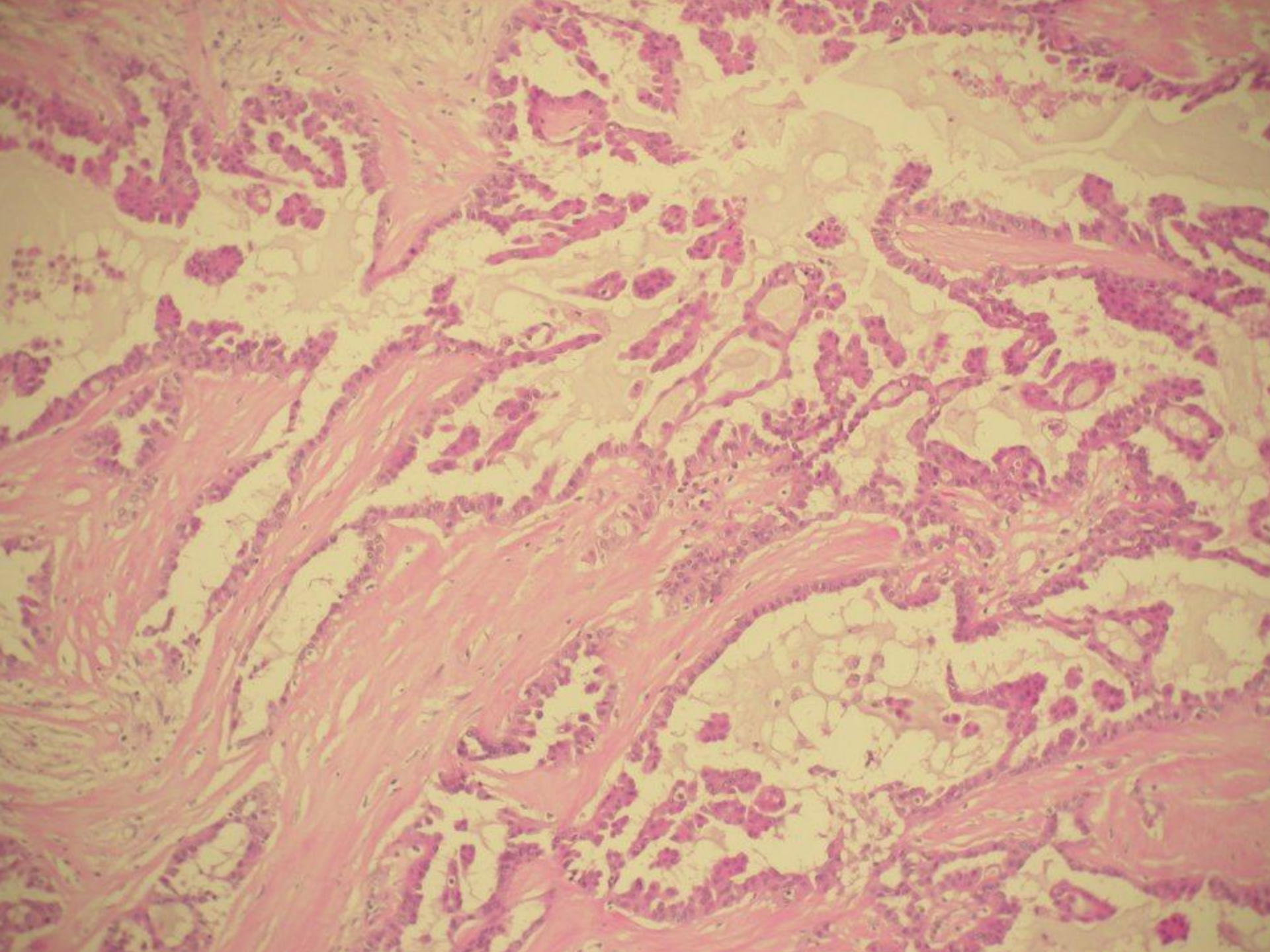

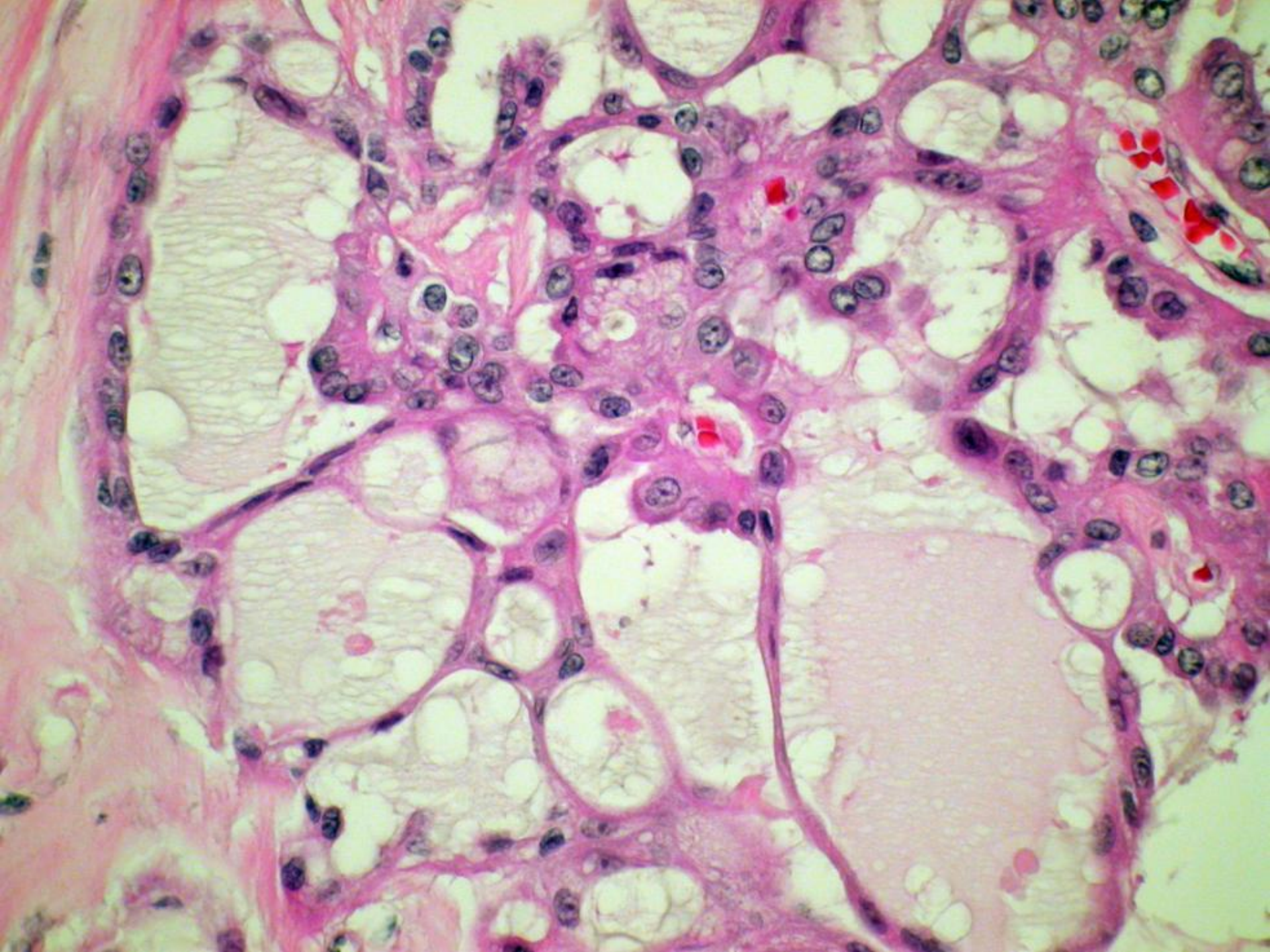

Carcinoma secretor (3 cm).
Linfadenectomía axilar negativa.

Carcinoma secretor de mama

- 1966, McDivitt y Steward: 7 niñas 3-15 a.
- Variante rara de carcinoma (0,05%)
- 100 casos publicados

15 casos en hombres (3-66 a.)

1:6 hombre/mujer

Carcinoma secretor de mama. Características

Arquitectura sólida, microquística, ductal

Células con mínima atipia y muy escasa actividad mitótica

Material de secreción intra y extracelular

PAS + DR

Azul alcian +

IHQ +: CK, S100, CEA y lactoálbúmina

RH negativos

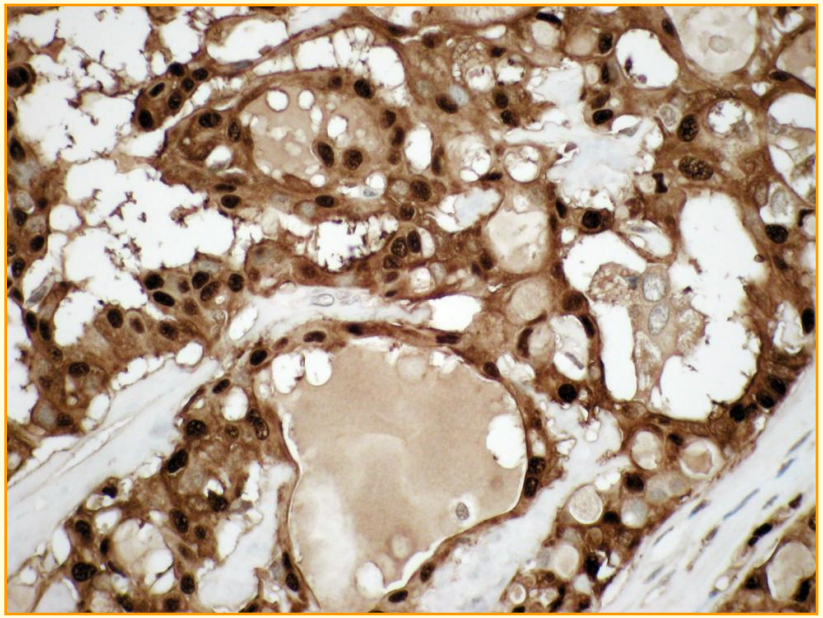

Carcinoma secretor de mama. Citología.

- Fondo tipo coloide.
- Celularidad dispersa y pequeños grupos regulares.
- Vacuolización citoplásmica y células en anillo de sello.

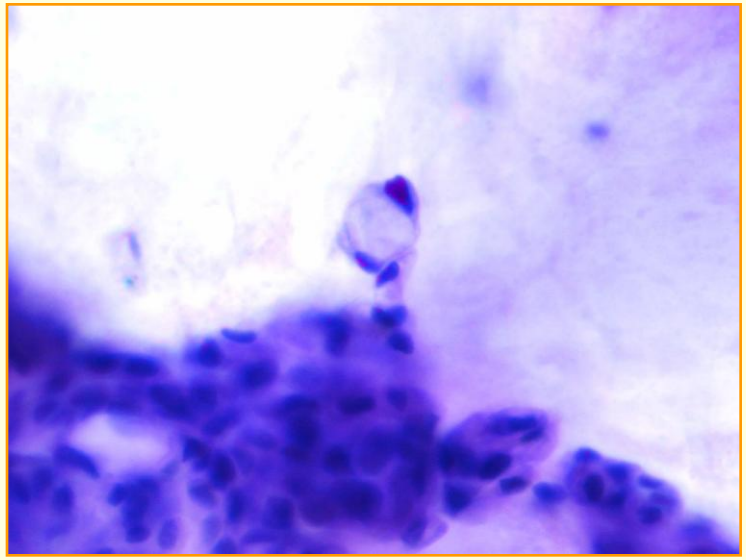

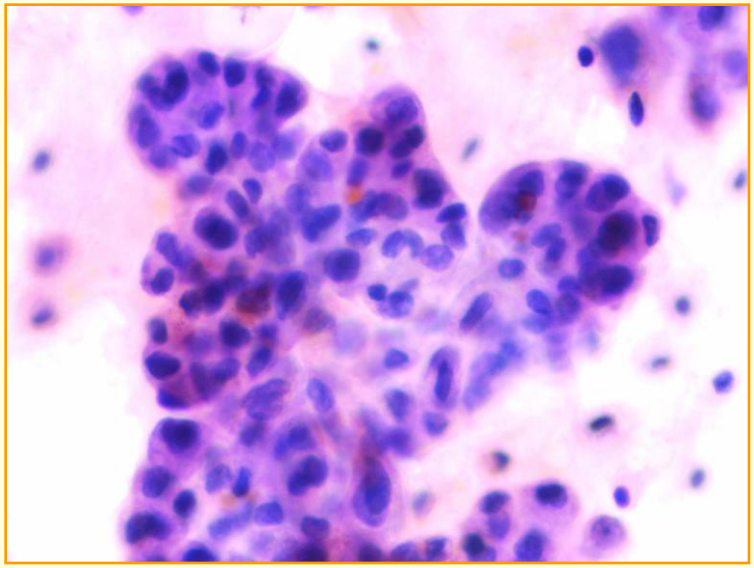

Carcinoma secretor de mama. Diagnóstico diferencial citológico.

- Carcinoma ductal
- Carcinoma lobulillar
- Carcinoma rico en lípidos
- Carcinoma rico en glucógeno
- Carcinoma mucinoso
- Carcinoma de células en anillo de sello.

Carcinoma secretor de mama. Pronóstico.

- Comportamiento biológico, mejor que el CDI
- 3/10 casos masculinos con LA, metástasis
- Mastectomía con linfadenectomía (G centinela)