Linfadenopatía generalizada en paciente varón de 37 años

Marrero Afonso, Jorge S; García Hernández, S; Álvarez-Argüelles H.; Salido Ruiz, E.
Hospital Universitario de Canarias

Caso clínico

- Varón 37 años.
- Natural de Venezuela.
- NAMC.
- Fiebre 1 mes, pérdida de peso y debilidad generalizada.
- Analítica:
    - Hb: 11.8 g/dL.
    - VCM: 90.5 fL.
    - Leucocitos: 2.41 x 10E3/mm3.
    - Neutrófilos: 1410/mm3.
    - Linfocitos: 0.68x10E3/mm3.
    - Serología: VHB y VHC negativo.
- TC: linfadenitis laterocervicales y axilares bilaterales, mediastínicas, abdominales y retroperitoneales.
- PET-TC: captación patológica.

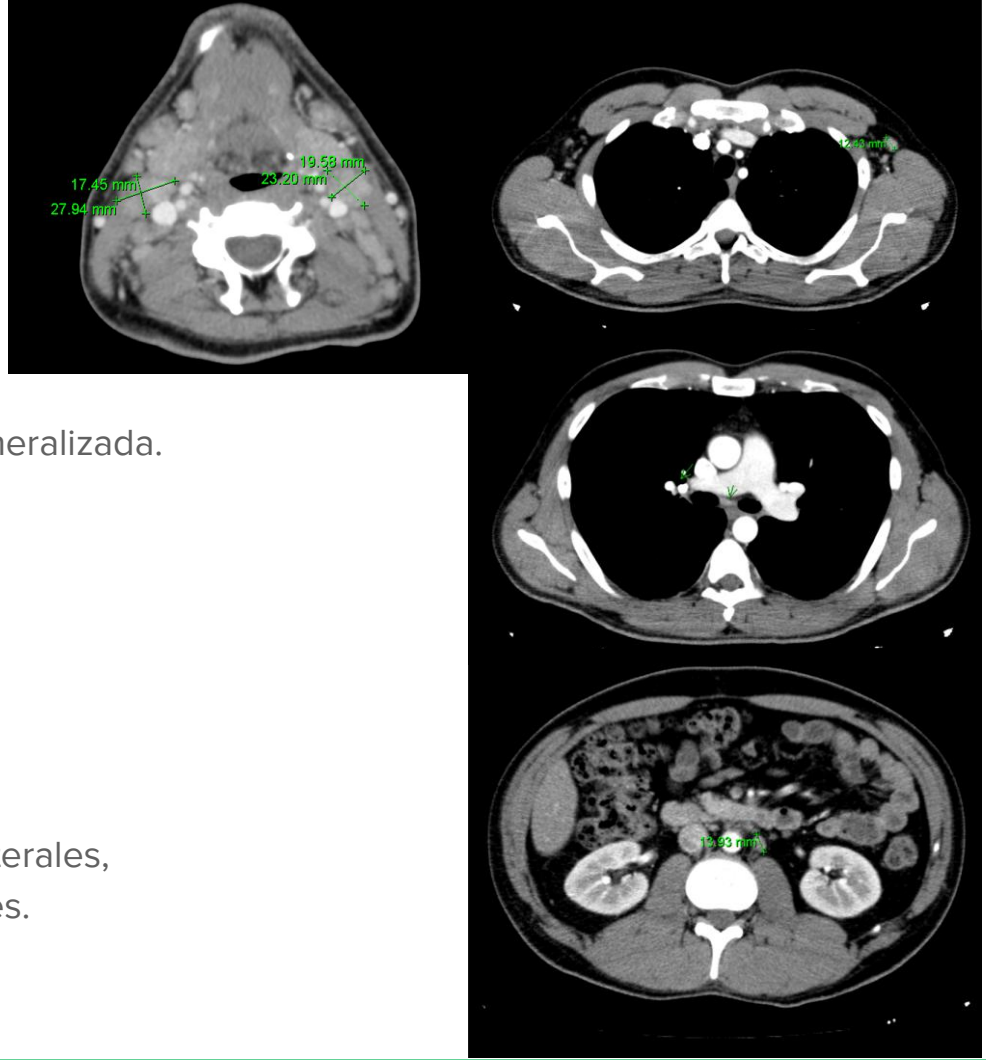

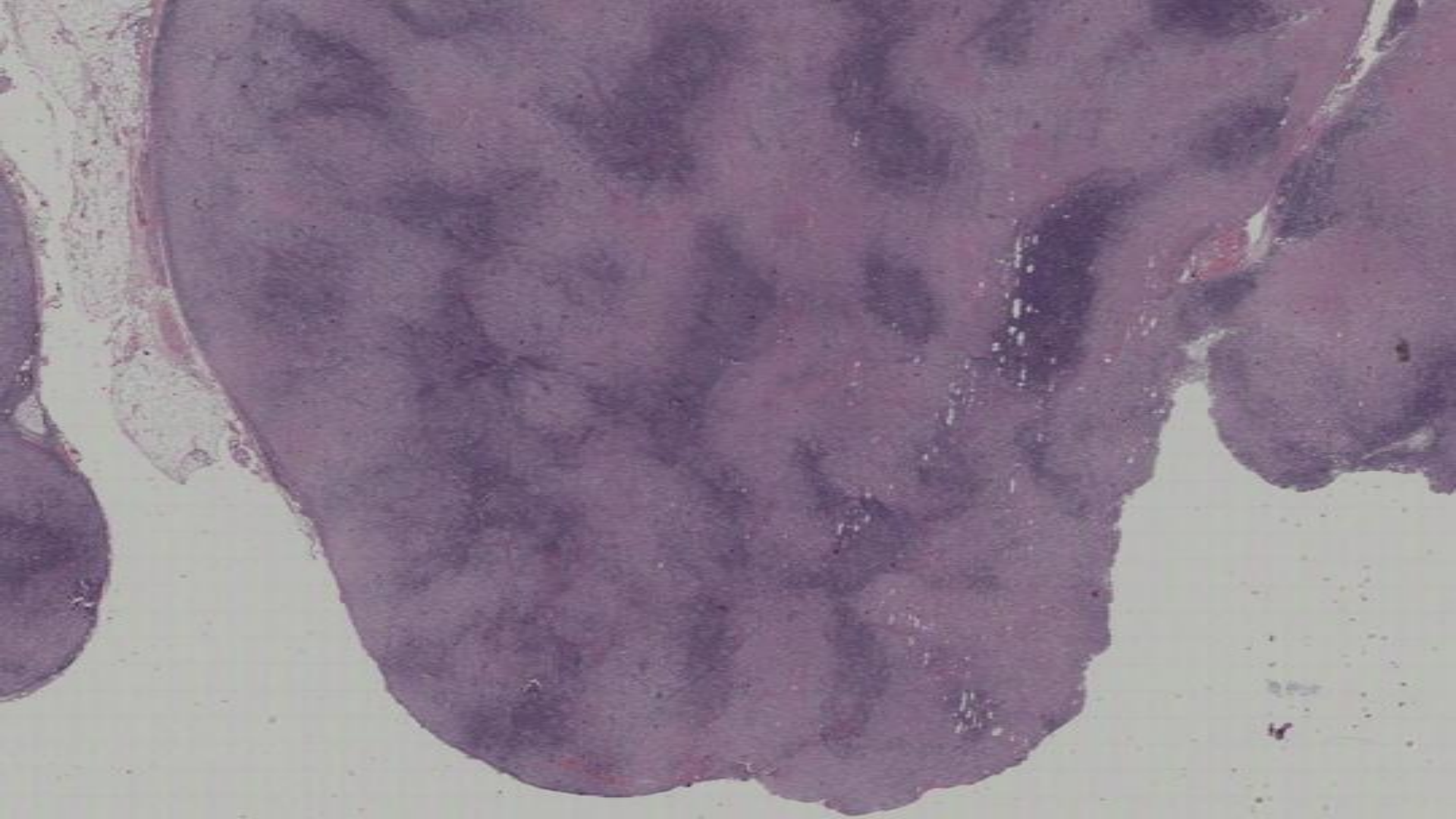

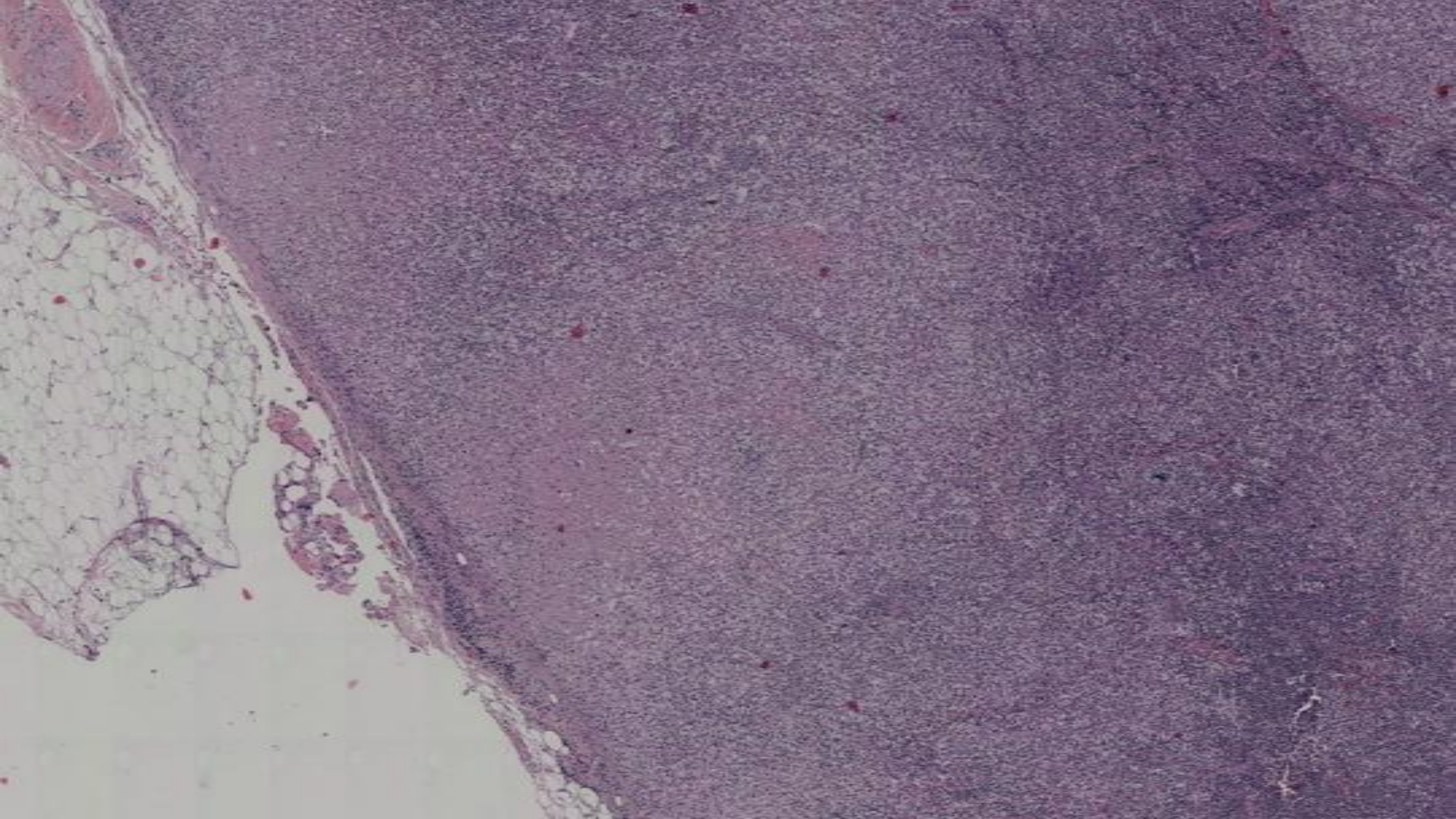

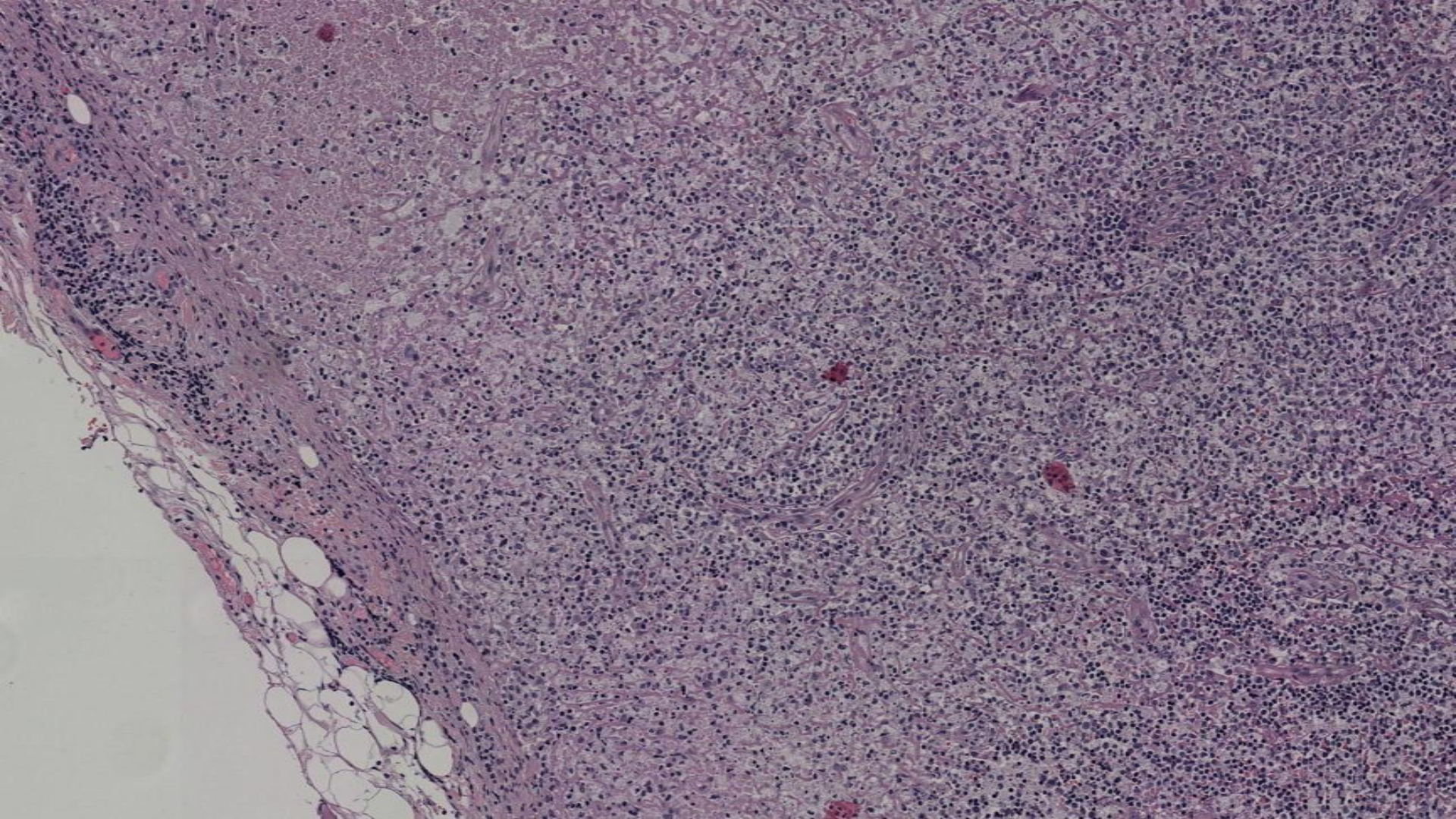

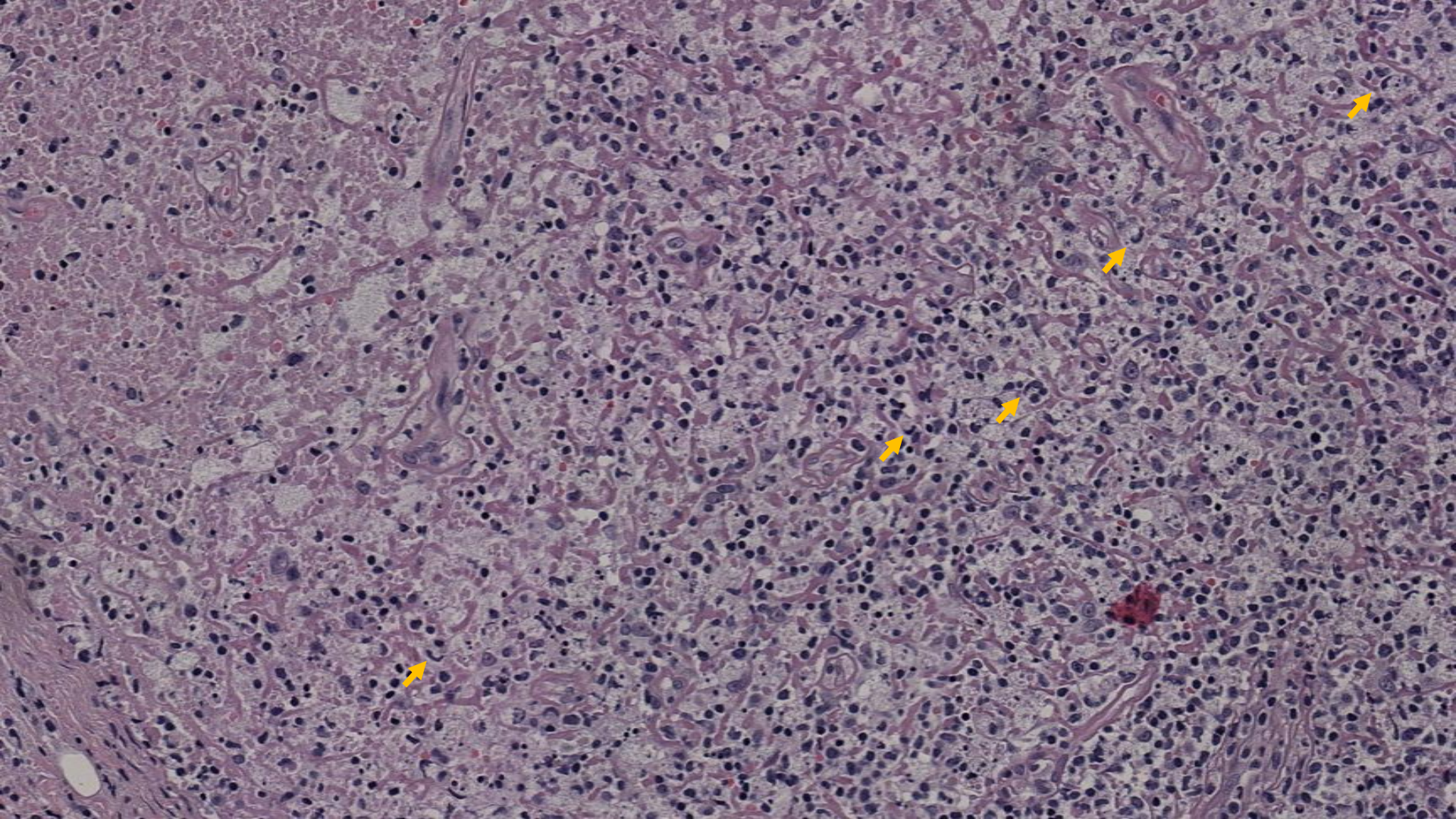

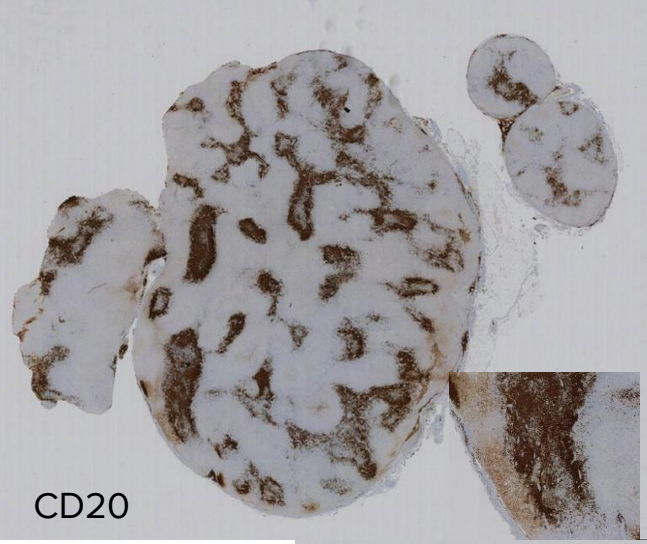
CD20

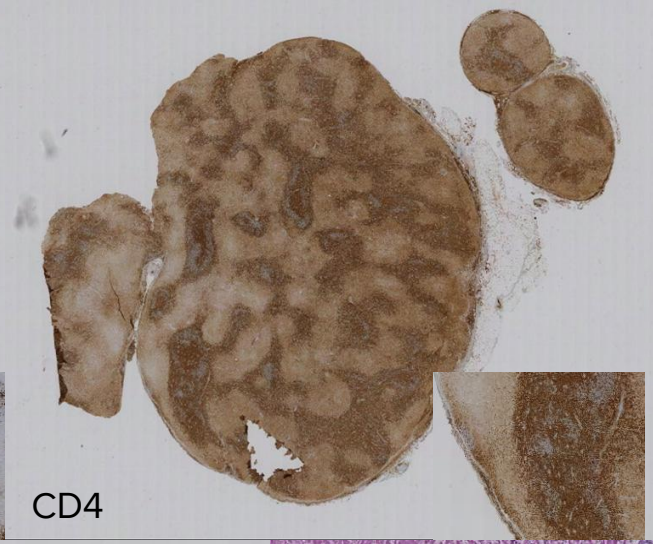
CD4

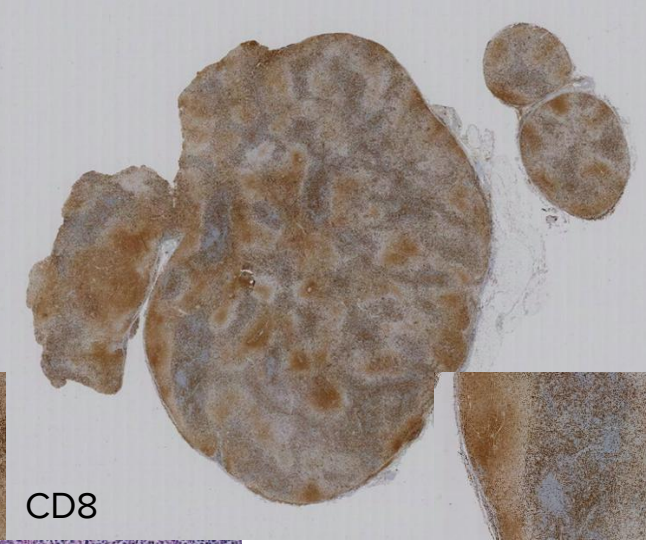
CD8

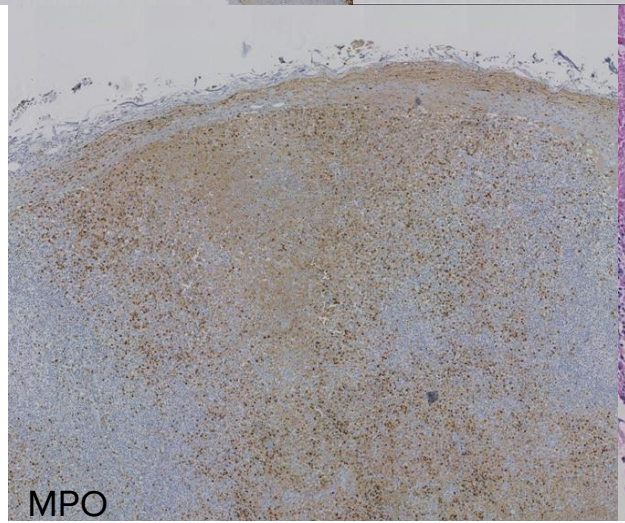
MPO

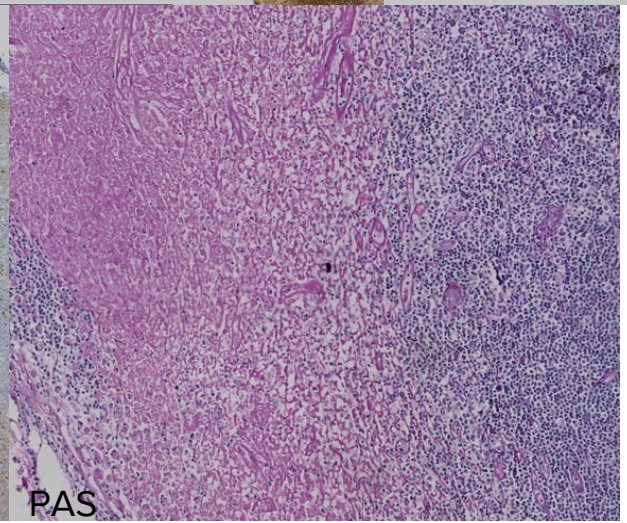
PAS

Linfadenitis necrotizante compatible con Enfermedad de Kikuchi-Fujimoto

Enfermedad de Kikuchi-Fujimoto

- Etiología: desconocida.
- Clínica:
  - Generalmente mujeres y jóvenes (<30 años y 4:1).
  - Fiebre 1 semana.
  - Síntomas de vía aérea superior.
  - Pápulas y úlceras cutáneas.
  - Manifestaciones infrecuentes:
    - Pérdida de peso.
    - Sudoración nocturna.
    - Náuseas y vómitos.
    - Linfadenopatía generalizada.
    - Dolor articular.
    - Hepatoesplenomegalia.

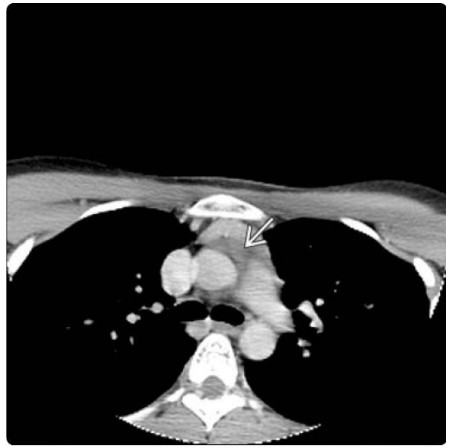

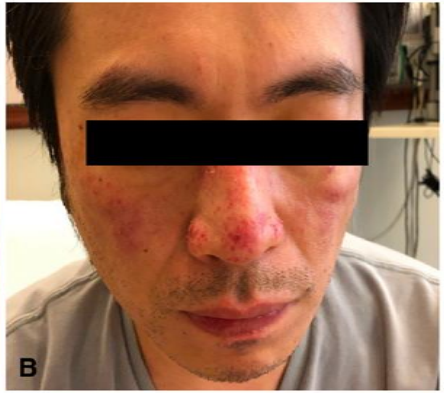

Anatomía patológica

- Manifestaciones ganglionares:
  - Afectación parcial o masiva.
  - Necrosis o apoptosis paracortical-pericapsular.
  - Sin granulocitos y pocas células plasmáticas.
  - Inmunoblastos numerosos.
  - Senos comprimidos o evidentes con histiocitosis.
  - Folículos hiperplásicos +- vasos trombosados.
  - Fases: proliferativa, necrótica y fagocítica.

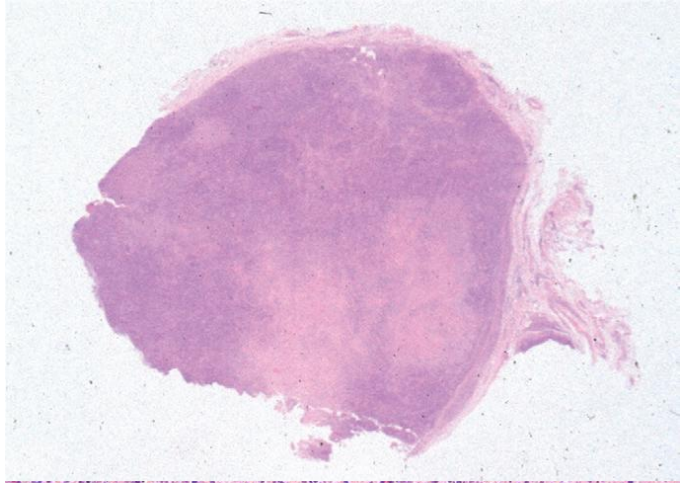

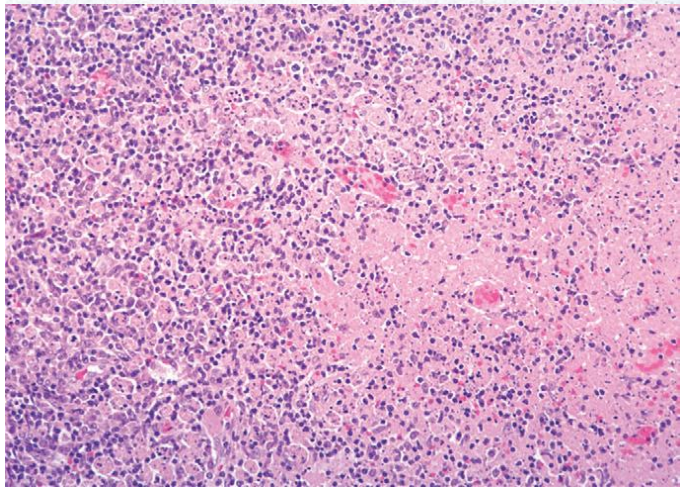

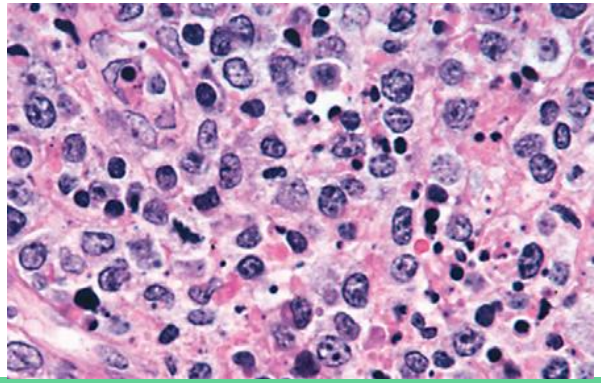

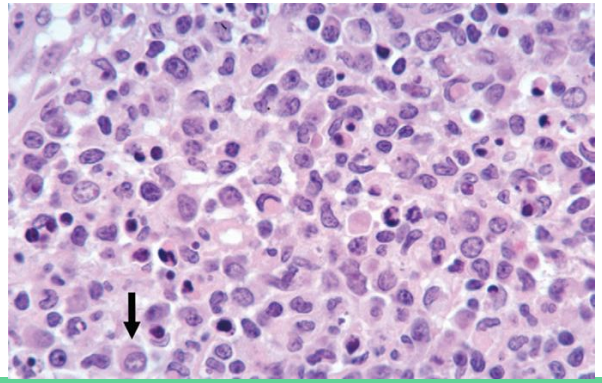

Fase proliferativa

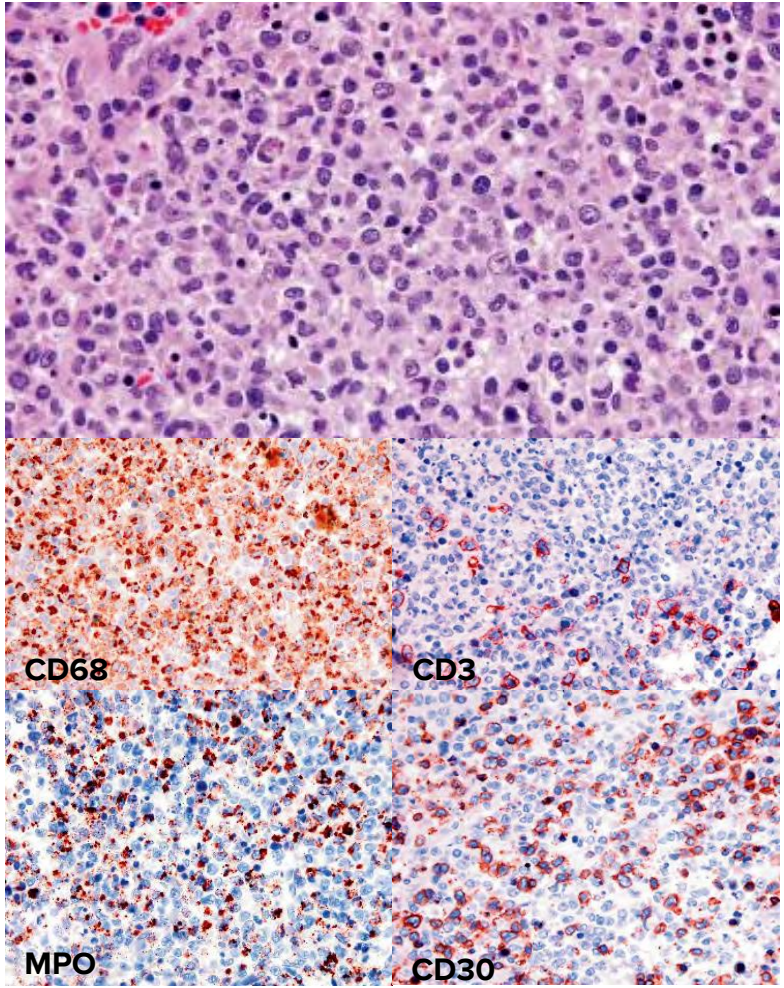

Fase necrótica

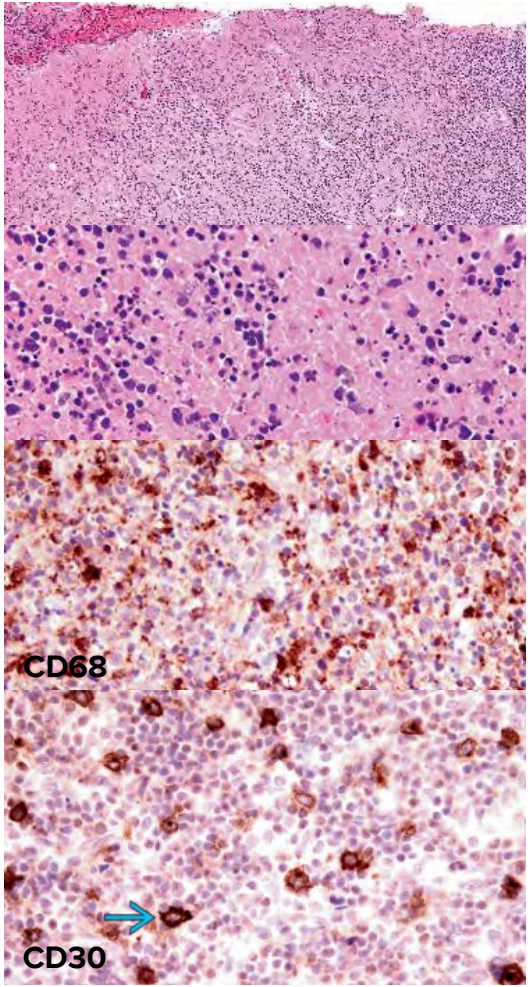

Fase fagocítica

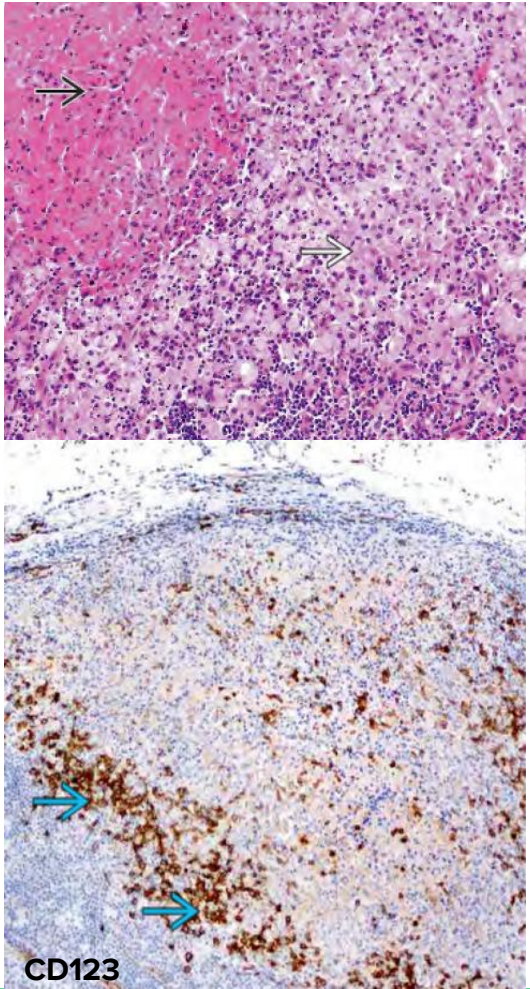

Diagnóstico diferencial

- Linfadenitis asociada a LES.
- Linfadenitis asociada a HPS:
  - Necrosis e histiocitos.
  - Inclusiones virales, PMN y úlceras.
- Linfadenitis granulomatosas necrotizantes:
  - TBC, micobacterias atípicas y hongos.
  - No restringidas a región paracortical.
  - C. epitelioides, PMN y plasmáticas.

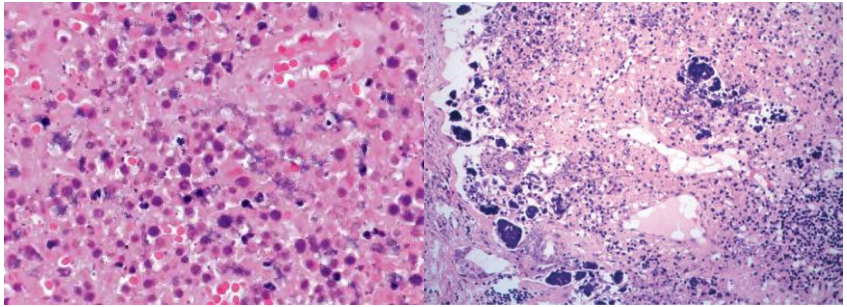

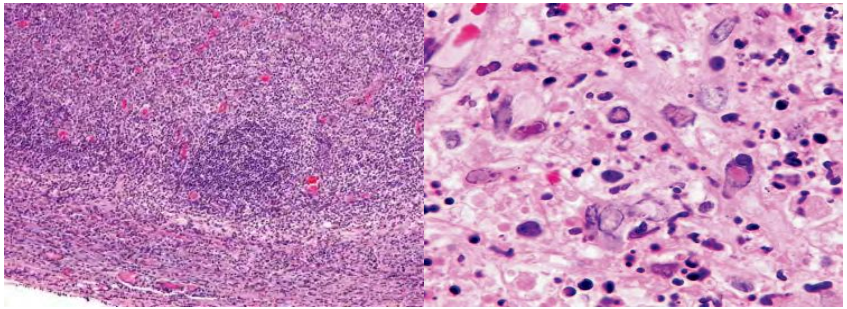

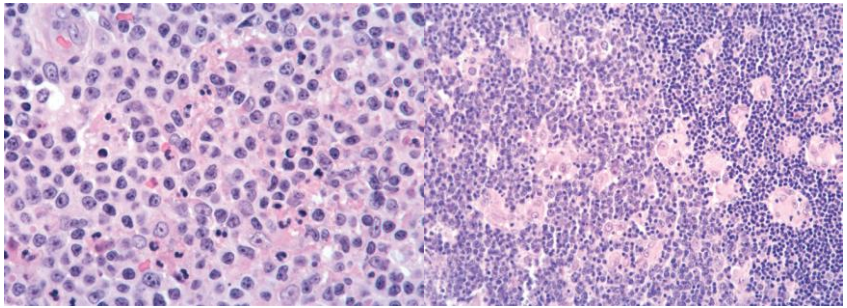

- Enfermedad por arañazo de gato:
  - Necrosis en estrella con PMN.
  - Granulomas.
- Enfermedad de Kawasaki:
  - Necrosis geográfica, PMN y trombos de fibrina.
- LDCGB:
  - Fase proliferativa similar.
  - Buscar histiocitos.
- Linfoma T periférico:
  - Sin histiocitos en C, ni células dendríticas.
  - CD4+, MPO- y sin reordenamientos típicos.
- Linfoma de Hodgkin clásico:
  - PMN, eosinófilos, células plasmáticas, Hodgkin y Reed-Sternberg.
- LAM/sarcoma mieloide.

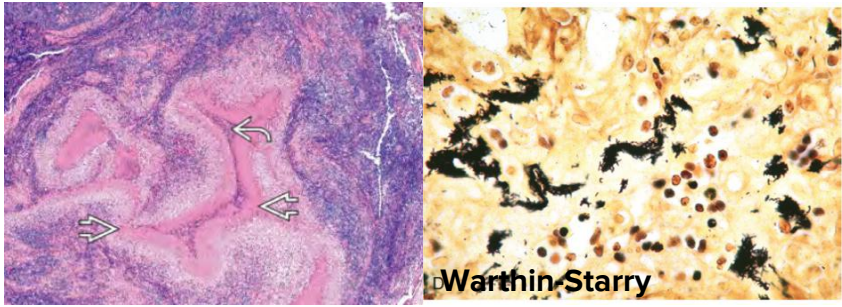

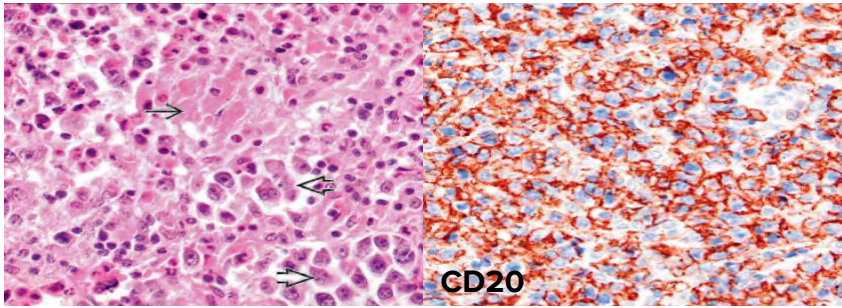

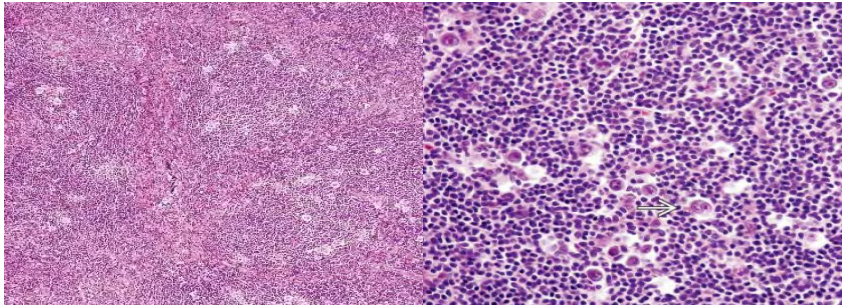

Conclusiones

- Enfermedad infrecuente.
- Tríada clínica:
  - Jóvenes.
  - Linfadenopatía cervical.
  - Fiebre baja.
- Claves diagnósticas:
  - Afectación paracortical.
  - Histiocitos en C.
  - Inmunoblastos numerosos.
  - Sin neutrófilos.

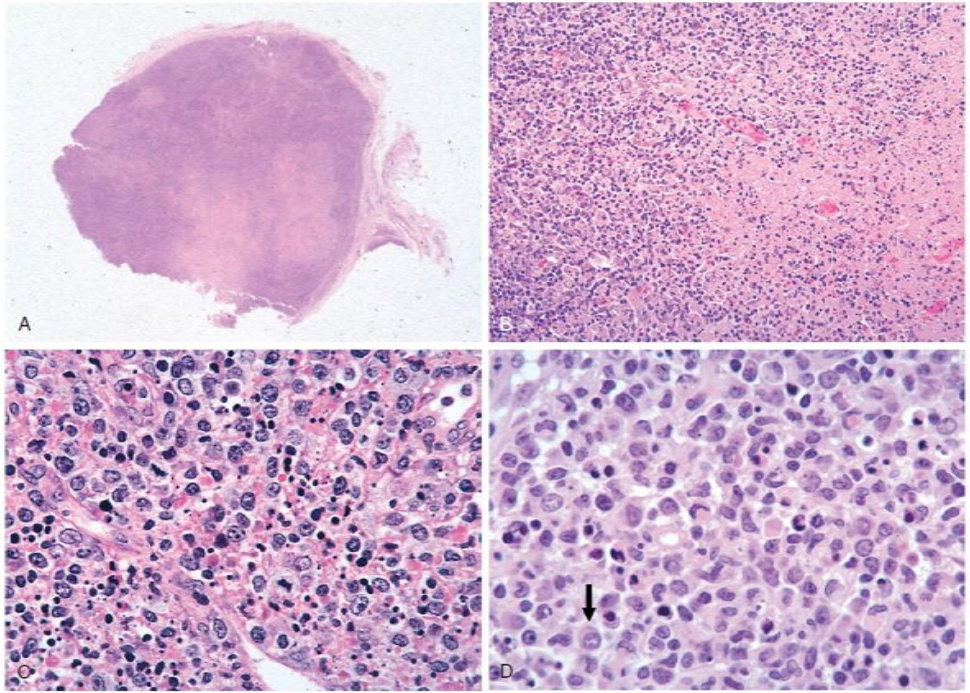

Linfadenopatía generalizada en paciente varón de 37 años

Marrero Afonso, Jorge S; García Hernández, S; Álvarez-Argüelles H.
Hospital Universitario de Canarias