SOCIEDAD VALENCIANA DE ANATOMIA PATOLOGICA

Caso 8

La Fe Hospital Universitari i Politècnic

Enrique García

Manuel Molina

Iván Rienda

Eva Company

Alessandra Bennini

Mónica Bauza

Nuria Rausell

Francisco Vera-Sempere



Historia clínica

- Varón de 43 años.
- Dolor en la región del hombro izquierdo.
- Múltiples adenopatías.
- Diagnosticado de metástasis de carcinoma de probable origen urotelial.

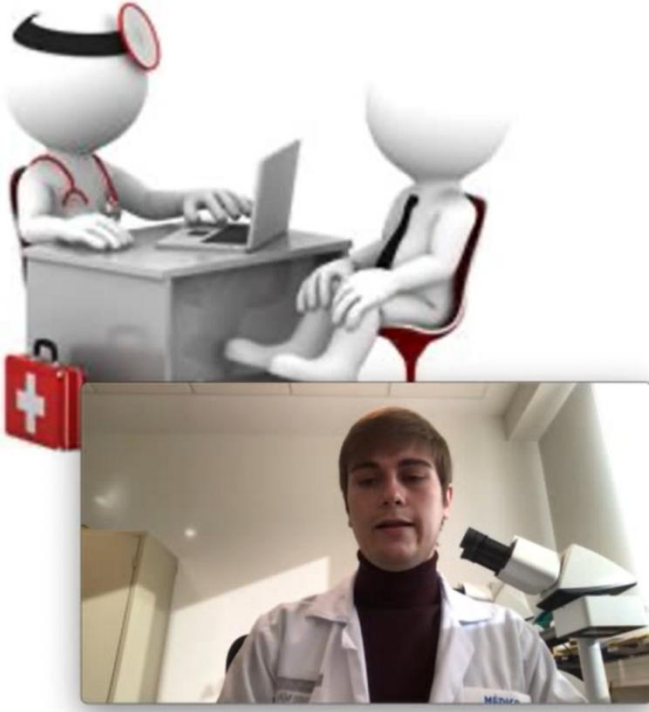

SOCIEDAD VALENCIANA DE ANATOMIA PATOLOGICA

La Fe Hospital Universitari i Politècnic

Historia clínica

- Viene a tratarse.
- Revisión historia.

SOCIEDAD VALENCIANA DE ANATOMIA PATOLOGICA

La Fe Hospital Universitari i Politècnic

TAC

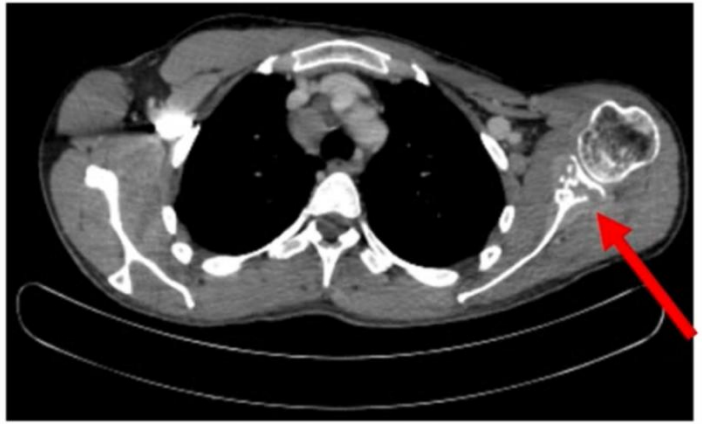

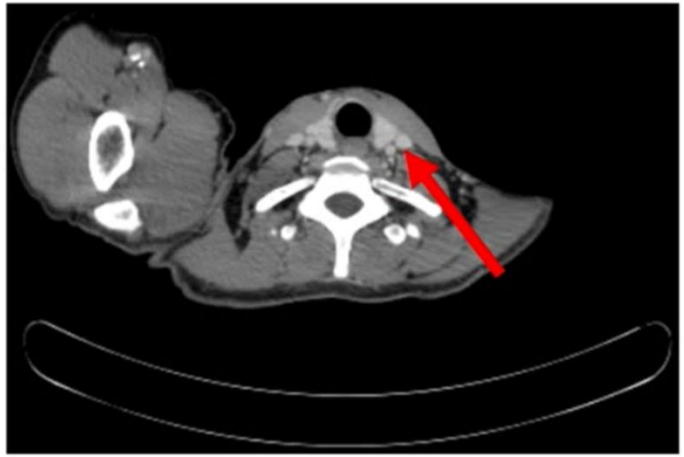

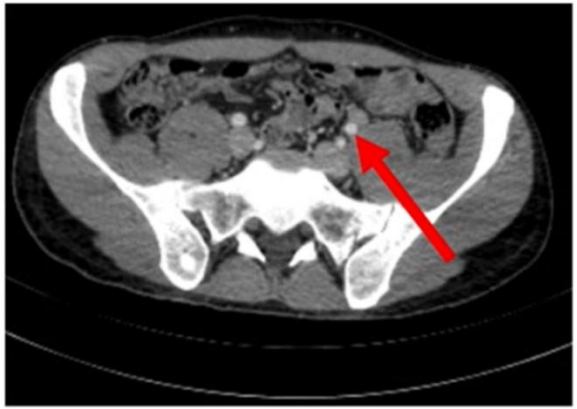

SOCIEDAD VALENCIANA
DE
ANATOMIA PATOLOGICA

La Fe
Hospital
Universitari
i Politècnic

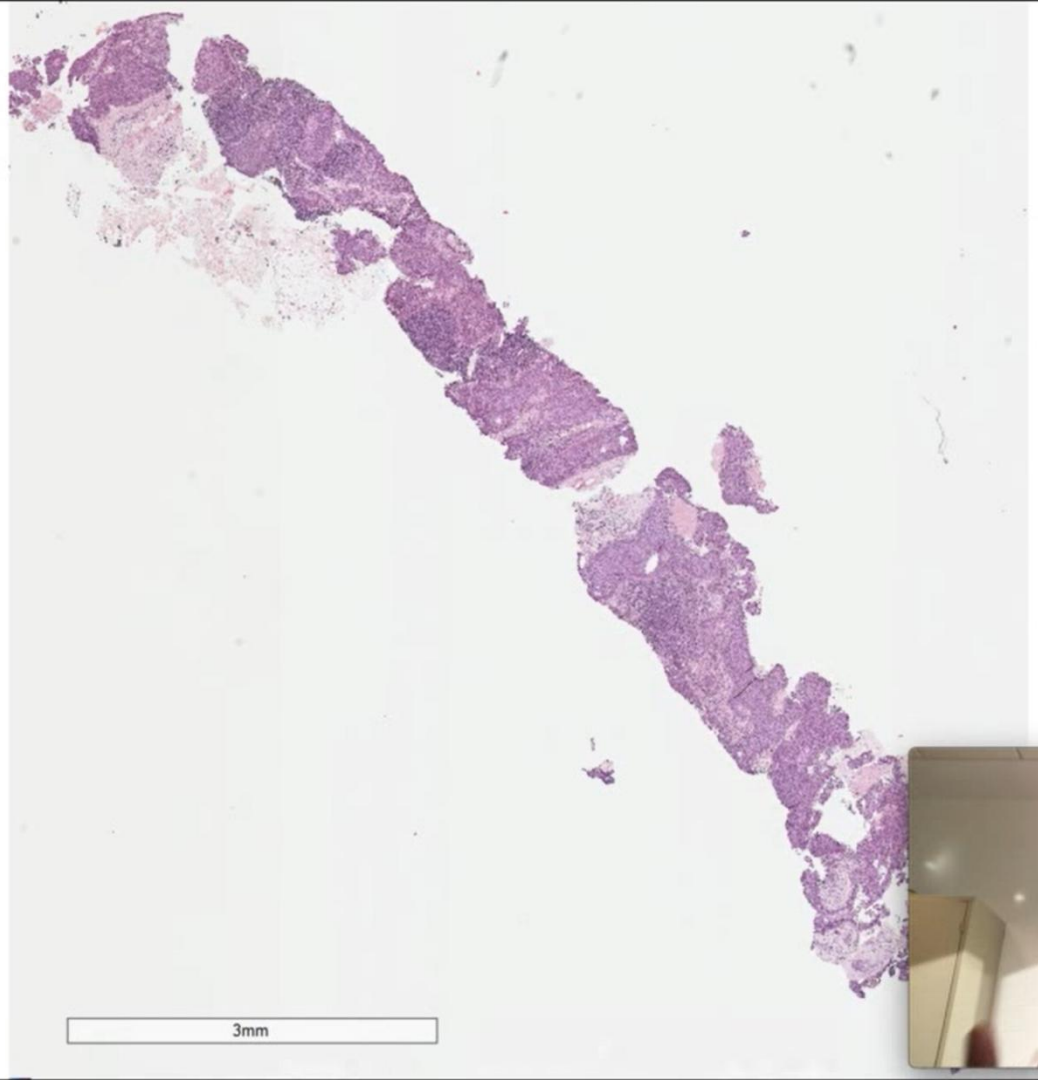



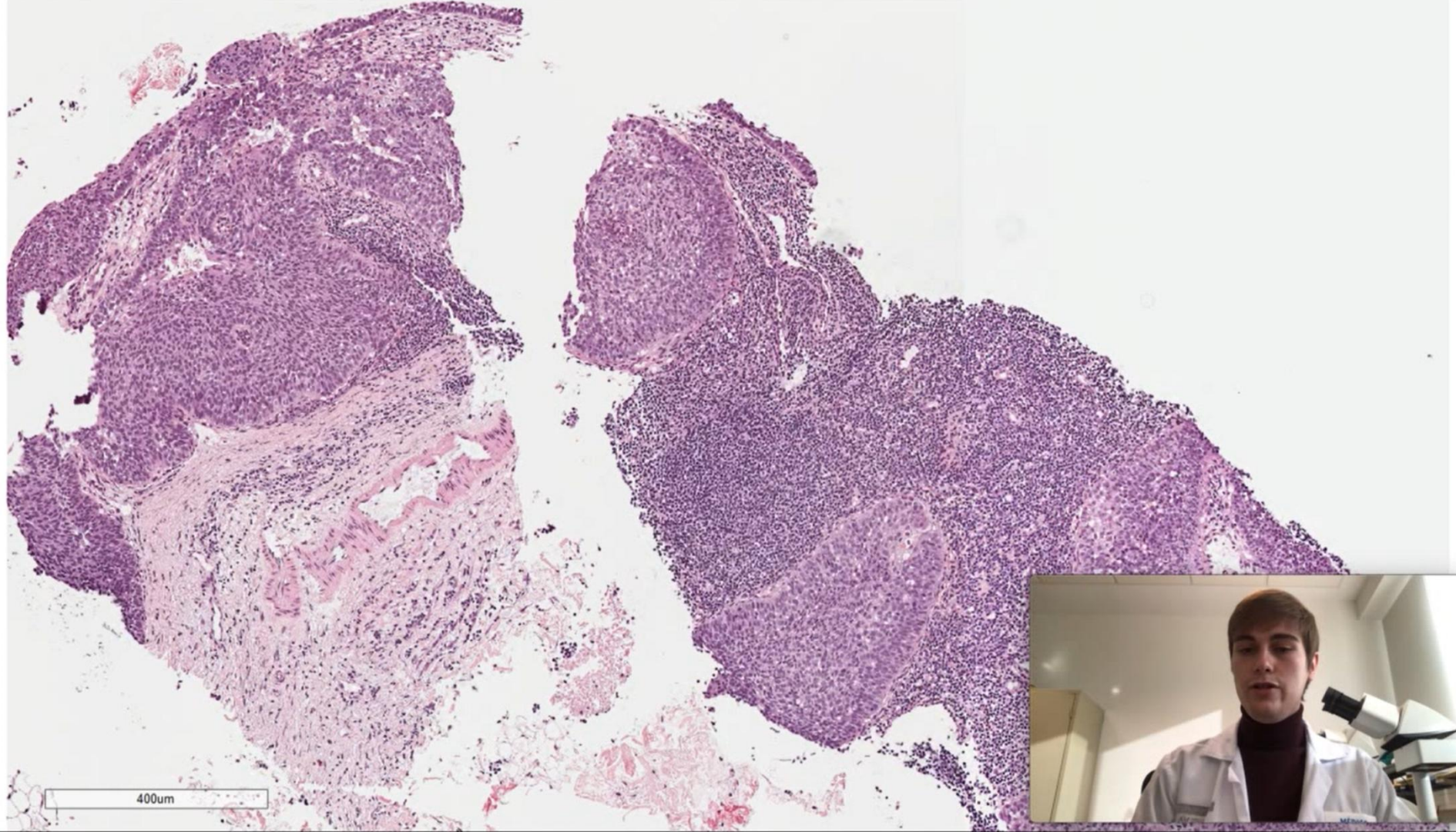
400um

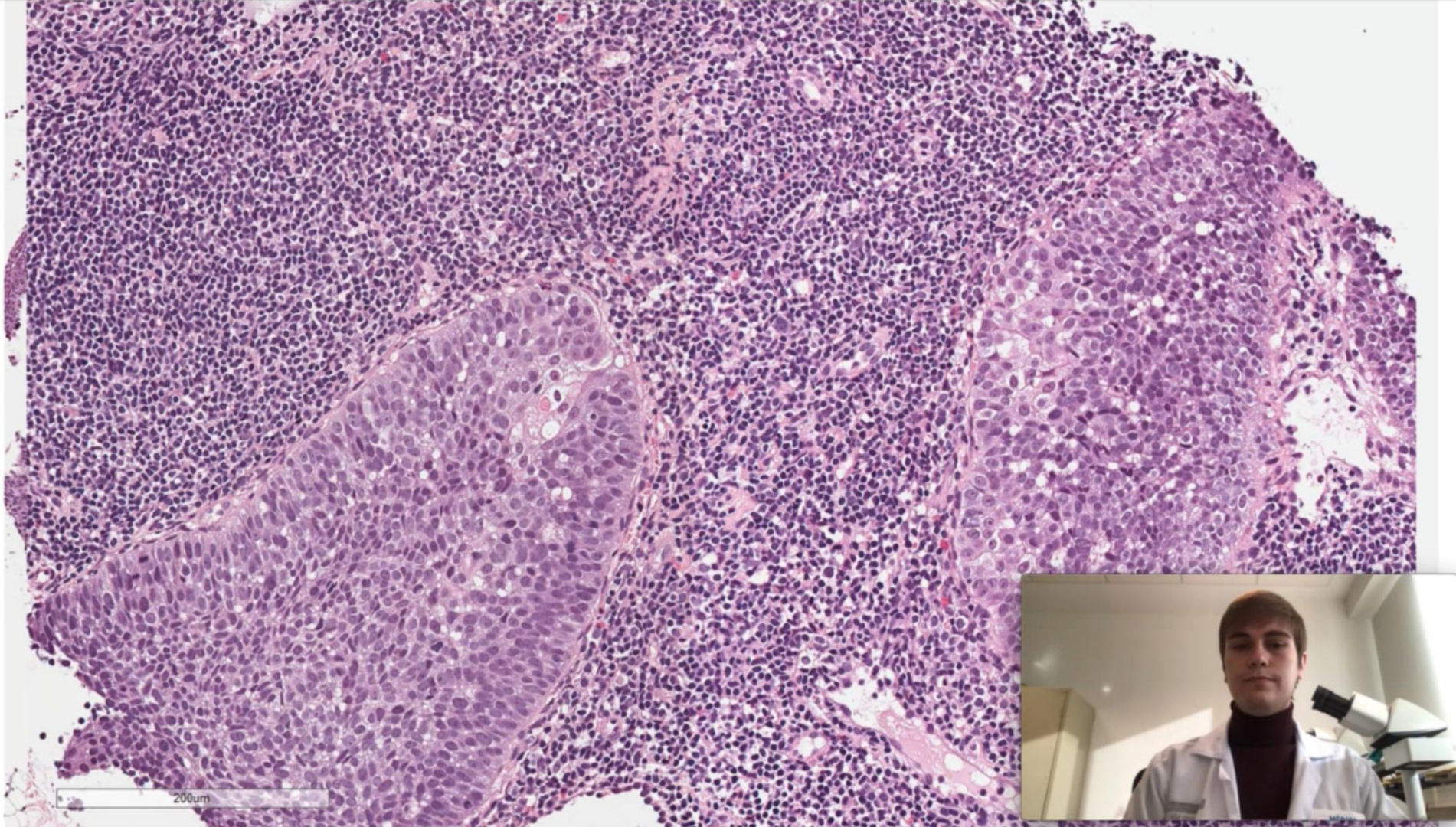
200um

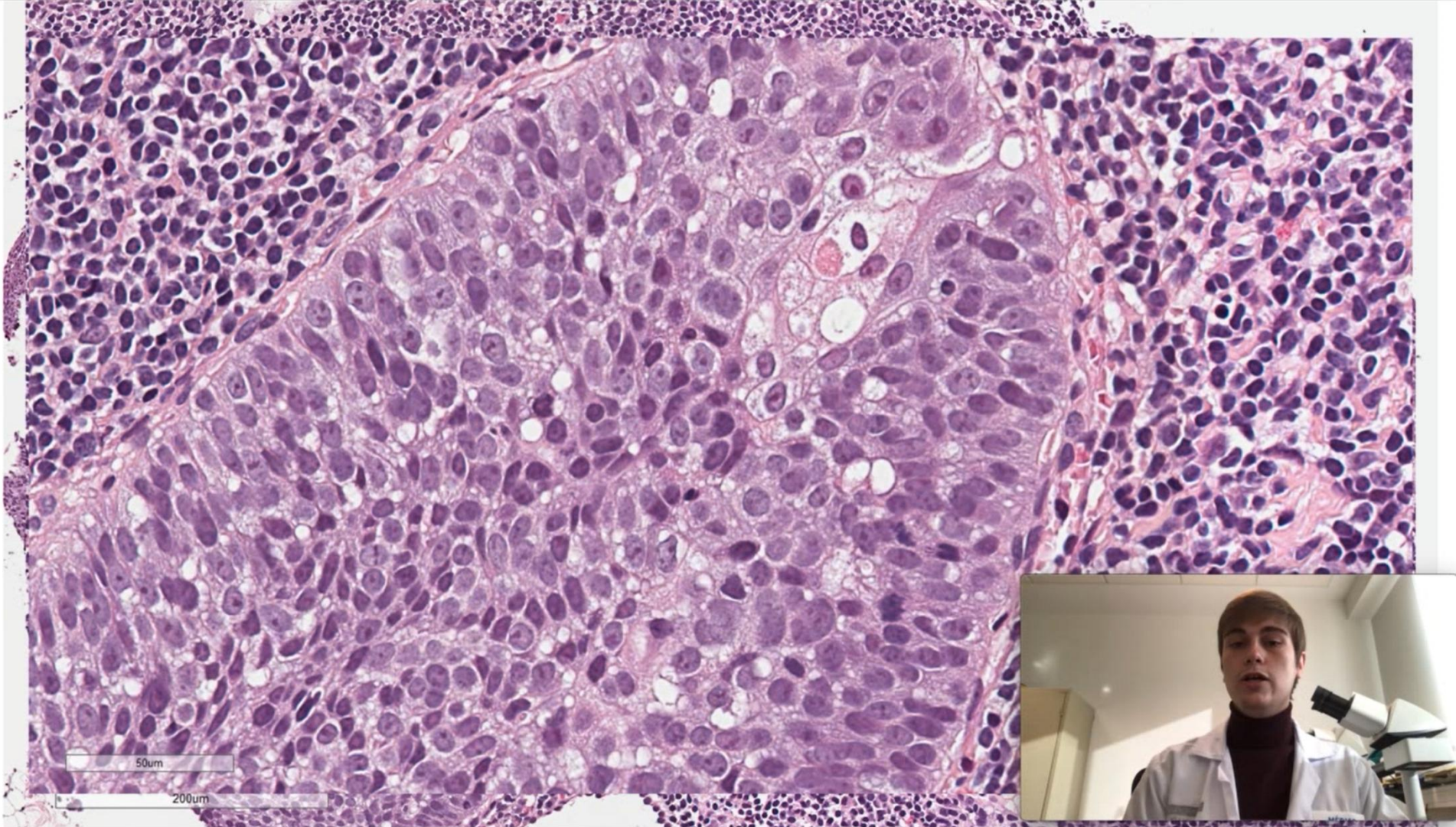
50um
200um

SOCIEDAD VALENCIANA DE ANATOMIA PATOLOGICA

La Fe Hospital Universitari i Politècnic

CK20

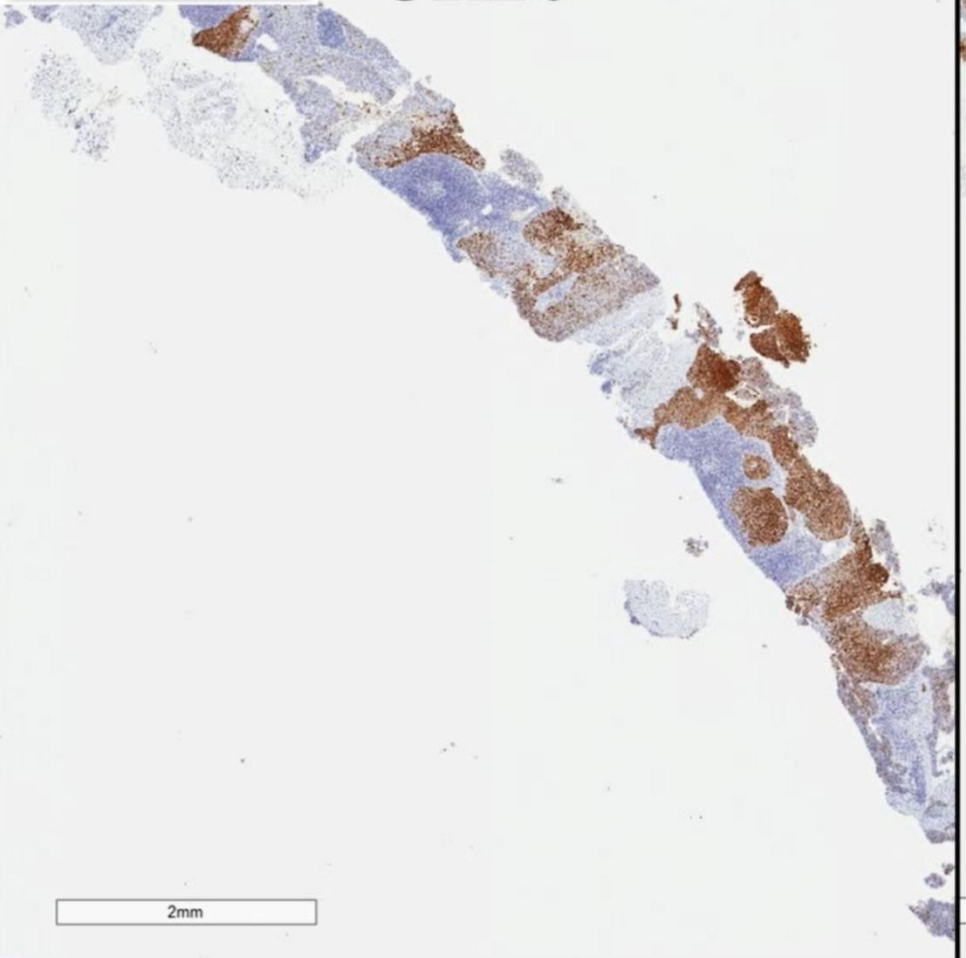

CK7

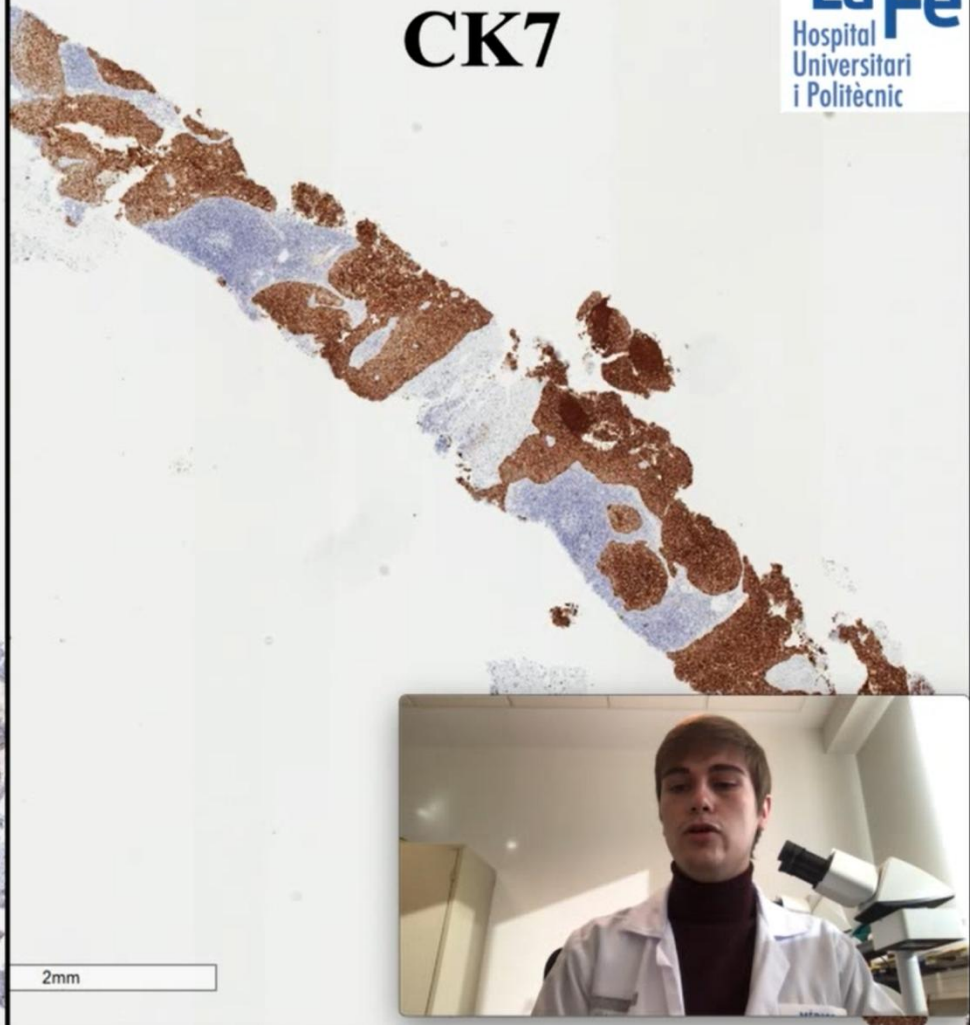

SOCIEDAD VALENCIANA DE ANATOMIA PATOLOGICA

La Fe Hospital Universitari i Politècnic

Diagnóstico diferencial

Table 1. Main primary origins of carcinomas of unknown primary site (CUPs) based on staining for CK7 and CK20 [4,8].

CK7+/CK20−	CK7+/CK20+	CK7−/CK20+	CK7−/CK20−
Breast carcinoma Lung adenocarcinoma Endometrial adenocarcinoma Endocervical adenocarcinoma Ovarian (serous) carcinoma Cholangiocarcinoma Small cell lung carcinoma Mesothelioma Thyroid carcinoma Salivary gland tumours Kidney (papillary) Urothelial carcinoma (subset) Pancreatic adenocarcinoma Gastric adenocarcinoma	Urothelial carcinoma Pancreatic adenocarcinoma Ovarian mucinous carcinoma Bladder adenocarcinoma Gastric adenocarcinoma Cholangiocarcinoma	Colorectal adenocarcinoma Merkel cell carcinoma Gastric adenocarcinoma	Prostate adenocarcinoma Renal (clear cells) Hepatocellular carcinoma Adrenocortical carcinoma Non-seminoma germ cell

Review

Immunohistochemistry for Diagnosis of Metastatic Carcinomas of Unknown Primary Site

Janick Selves [1], Elodie Long-Mira [2], Marie-Christine Mathieu [3], Philippe Rochaix [1] and Marius Ilié [2,*]

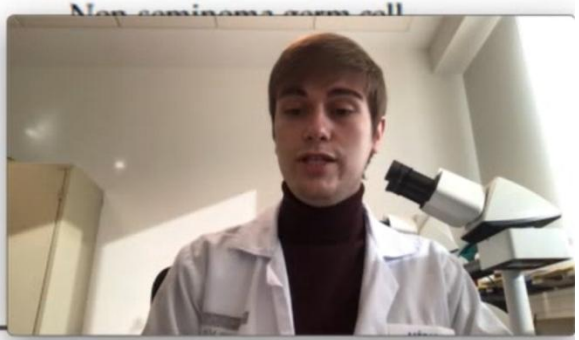

SOCIEDAD VALENCIANA DE ANATOMIA PATOLOGICA

La Fe Hospital Universitari i Politècnic

p40

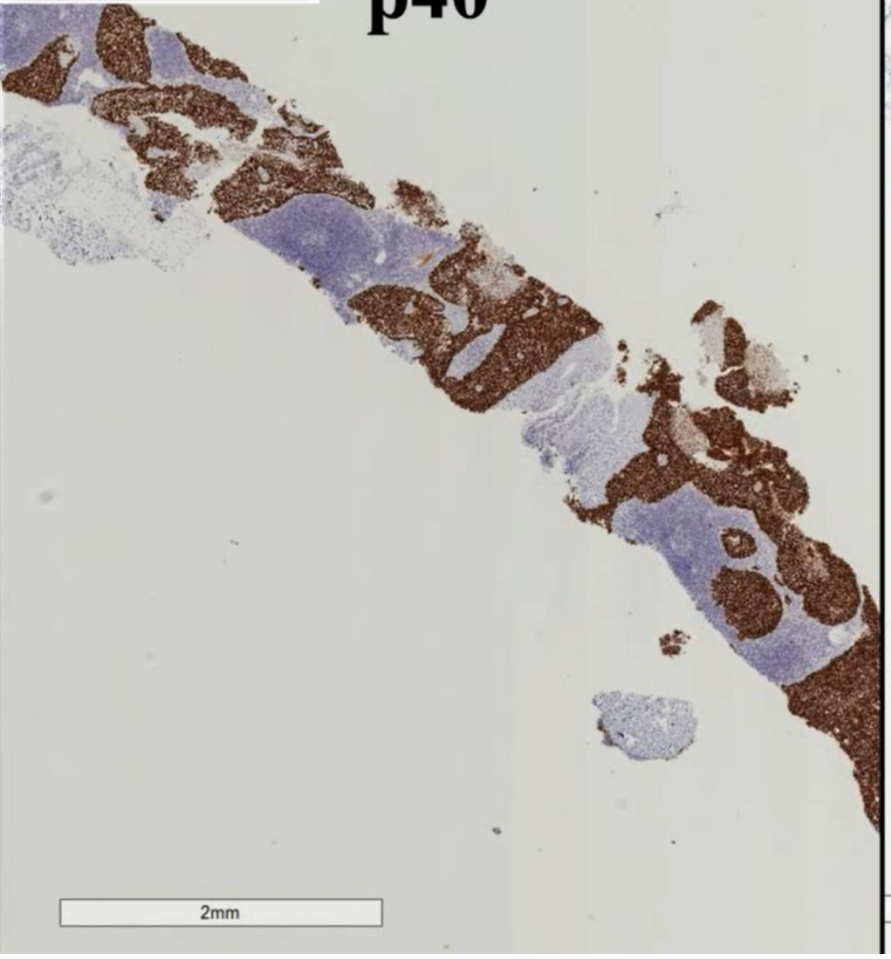

p63

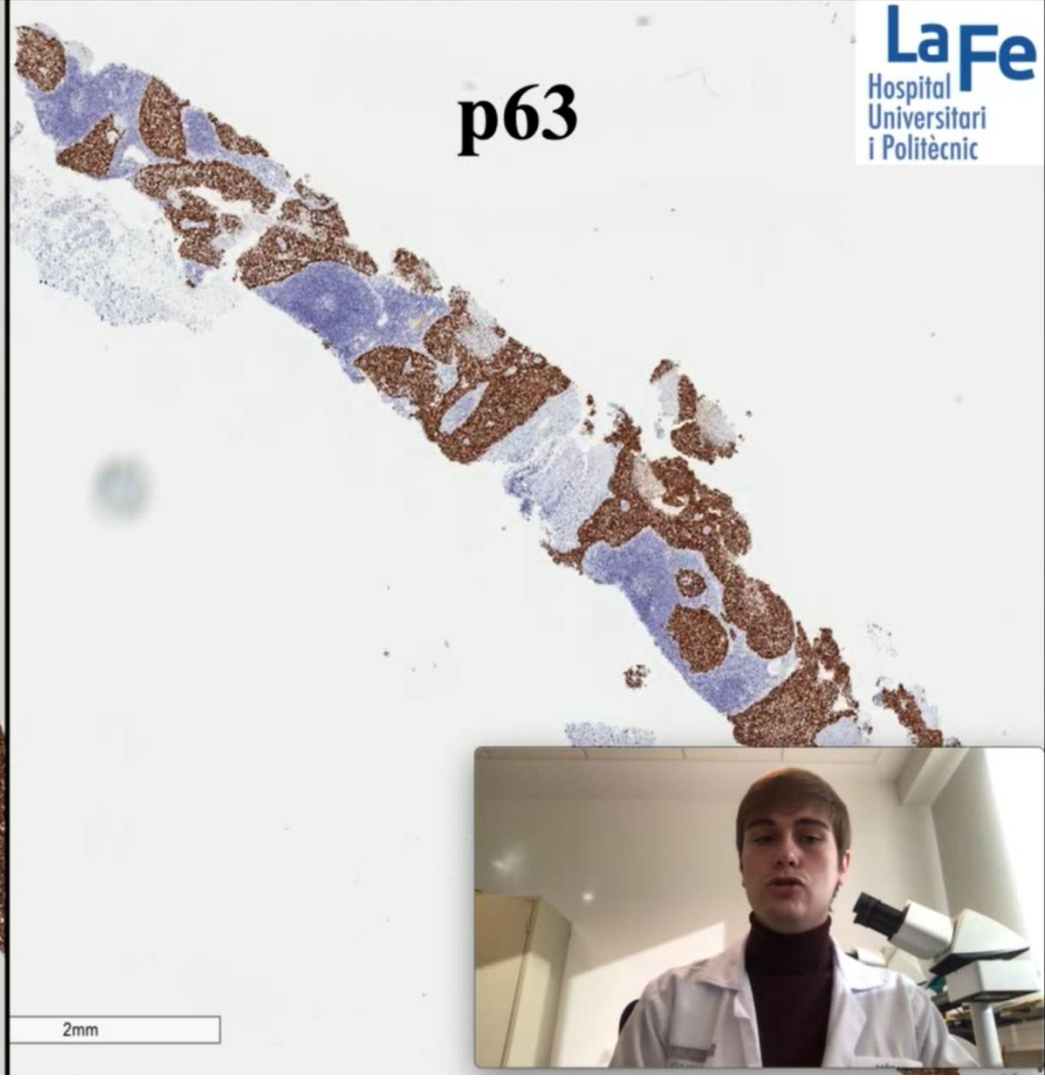

SOCIEDAD VALENCIANA DE ANATOMIA PATOLOGICA

La Fe Hospital Universitari i Politècnic

TTF1

GATA3

SOCIEDAD VALENCIANA DE ANATOMIA PATOLOGICA

La Fe Hospital Universitari i Politècnic

Historia clínica

- Sugerimos que nos envíen la biopsia de la adenopatía que ya tenían.

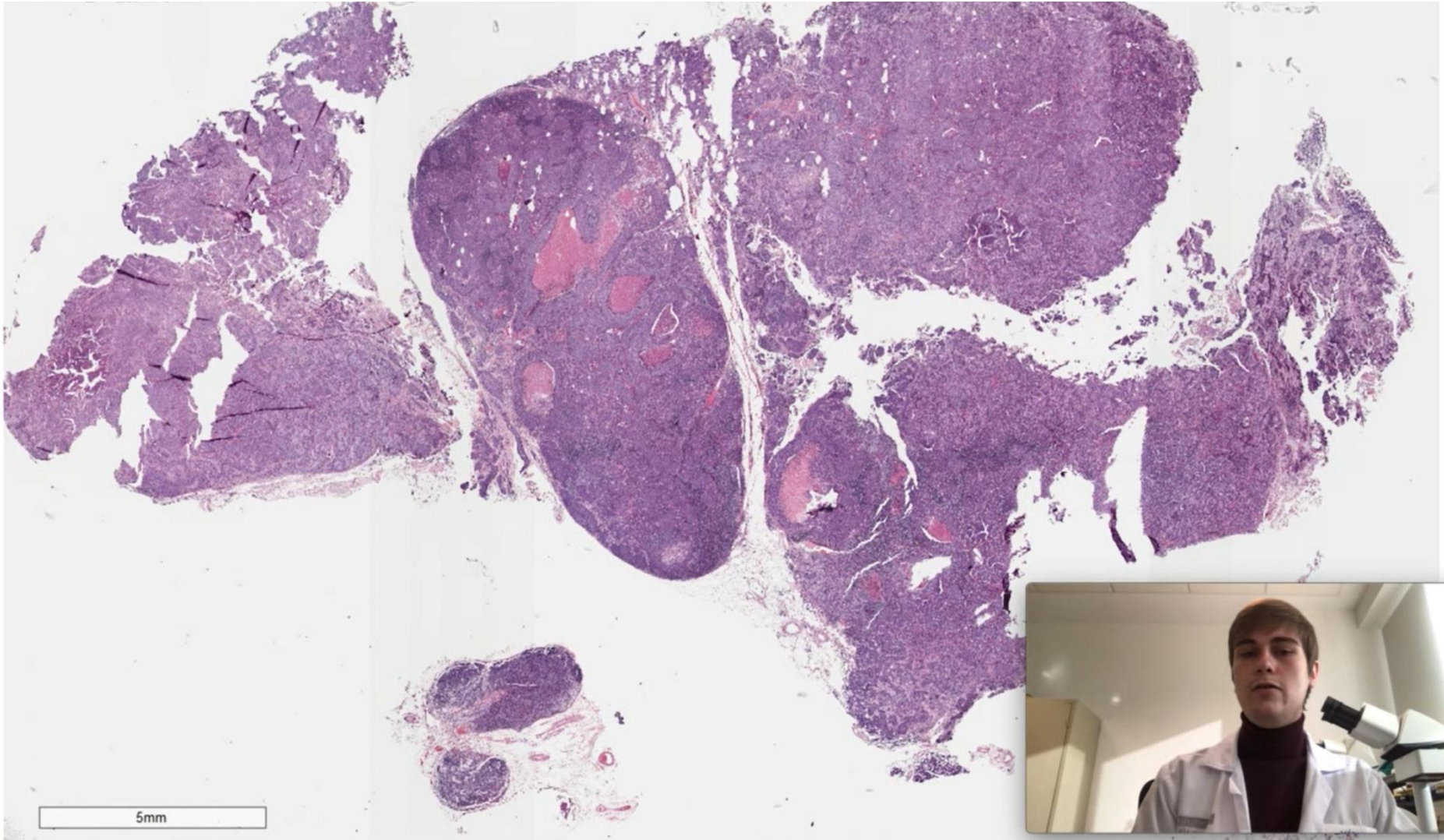
5mm

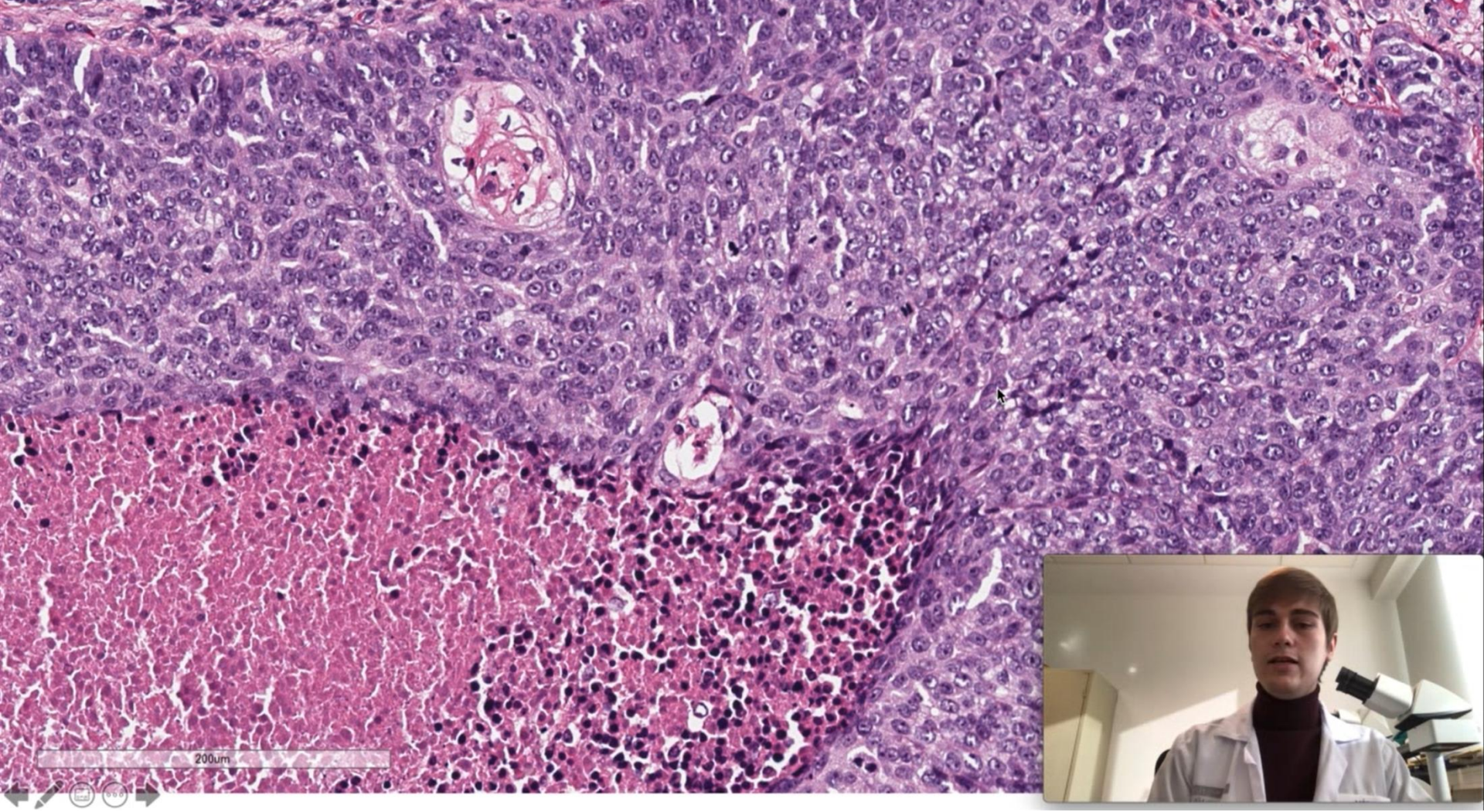
200um

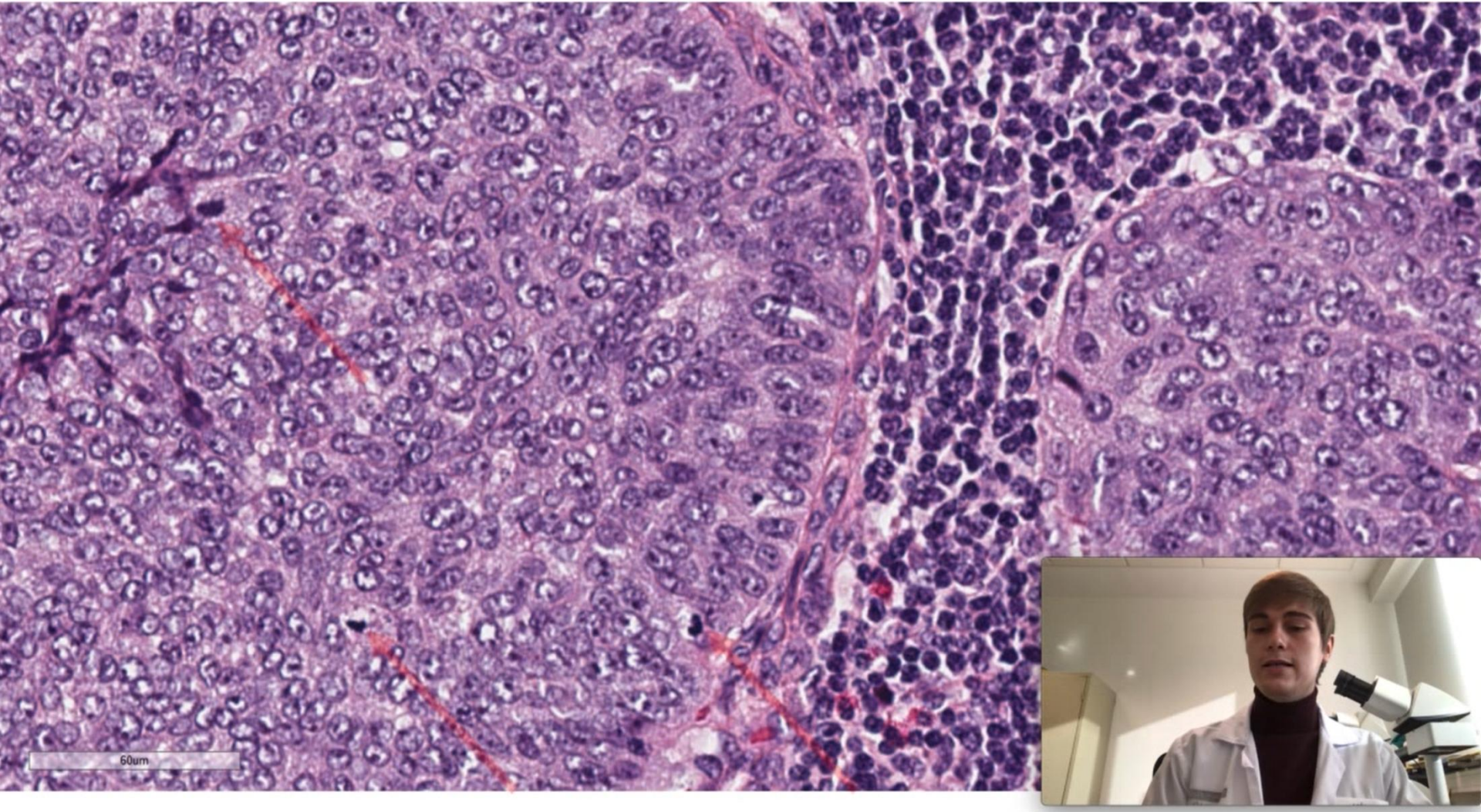
60um

SOCIEDAD VALENCIANA
DE
ANATOMIA PATOLOGICA

La Fe
Hospital
Universitari
i Politècnic

CK20

CK7

p40

p63

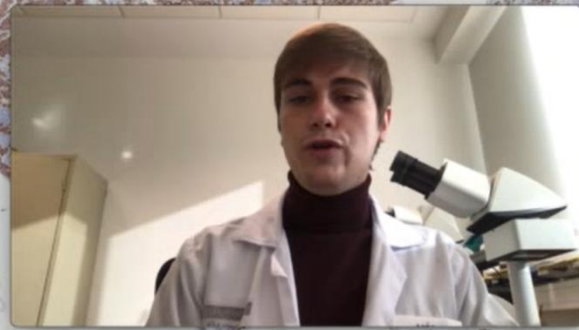

SOCIEDAD VALENCIANA DE ANATOMIA PATOLOGICA

La Fe Hospital Universitari i Politècnic

TTF1

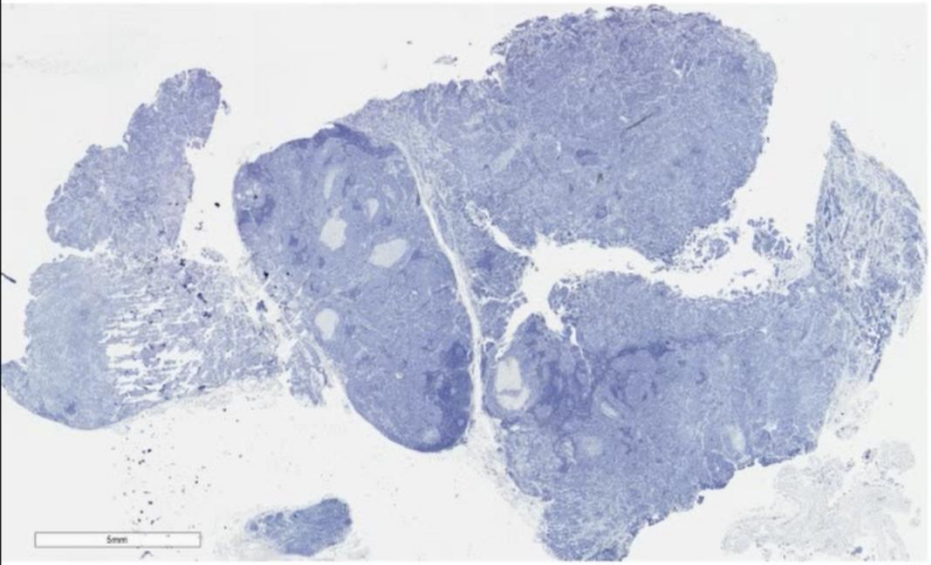

GATA3

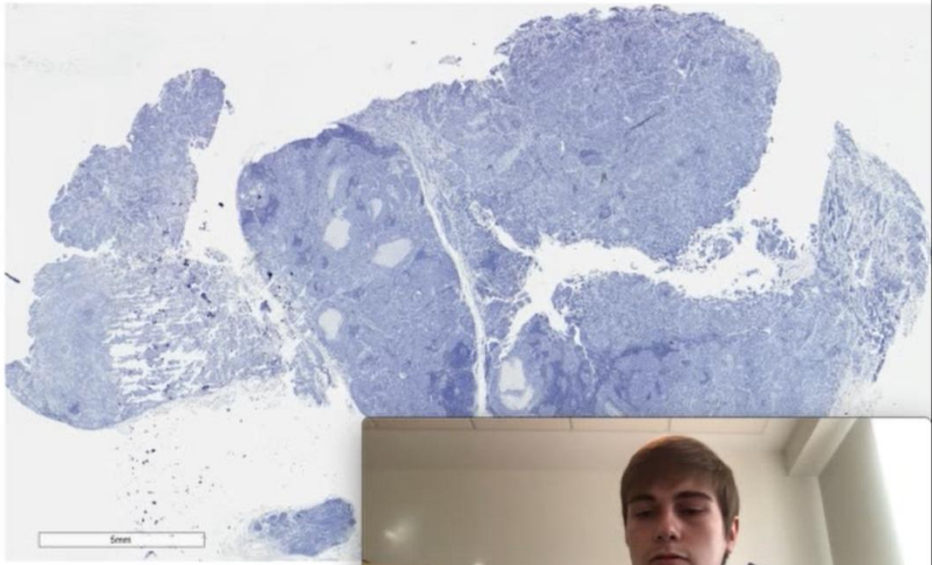

SOCIEDAD VALENCIANA DE ANATOMIA PATOLOGICA

La Fe Hospital Universitari i Politècnic

Diagnóstico diferencial

Table 4. IHC tumour staining patterns in the differential diagnosis of CUPs expressing CK7+/CK20+ [1,7].

Primary Origin Site	Immunostaining Profile
Lung (mucinous) [49]	TTF1−/+, CK7−/+, CDX2−/+
Pancreas [26,27,50,51]	Maspin A+, S100P+, IMP-3+, pVHL−, SMAD4−/+, MUC5AC+, CDX2−/+
Stomach [26,27,50,51]	CEA+, CDX2−/+, MUC1−/+, MUC5AC−/+, CDH17+/−, TTF1−
Oesophagus [26,27,50,51]	CEA+, MUC5AC+/−, CDH17+, MUC1−/+, CDX2−/+
Ovary (mucinous) [7,52]	DPC4+, CA-12.5+, CDX2+/−
Urinary bladder [17–21]	GATA3+, p63+, p40+, CK5/6+, CK20+/−, S100P+, CK903+, UPIII+/−
Small intestine [39]	CDX2+, CDH17+, Villin+/−, MUC5AC+/−
NUT midline carcinoma [53–55]	CK7+/−, CK20+/−, p40+/−, NUT

cancers MDPI

Review

Immunohistochemistry for Diagnosis of Metastatic Carcinomas of Unknown Primary Site

Janick Selves [1], Elodie Long-Mira [2], Marie-Christine Mathieu [3], Philippe Rochaix [1] and Marius Ilié [2,*]

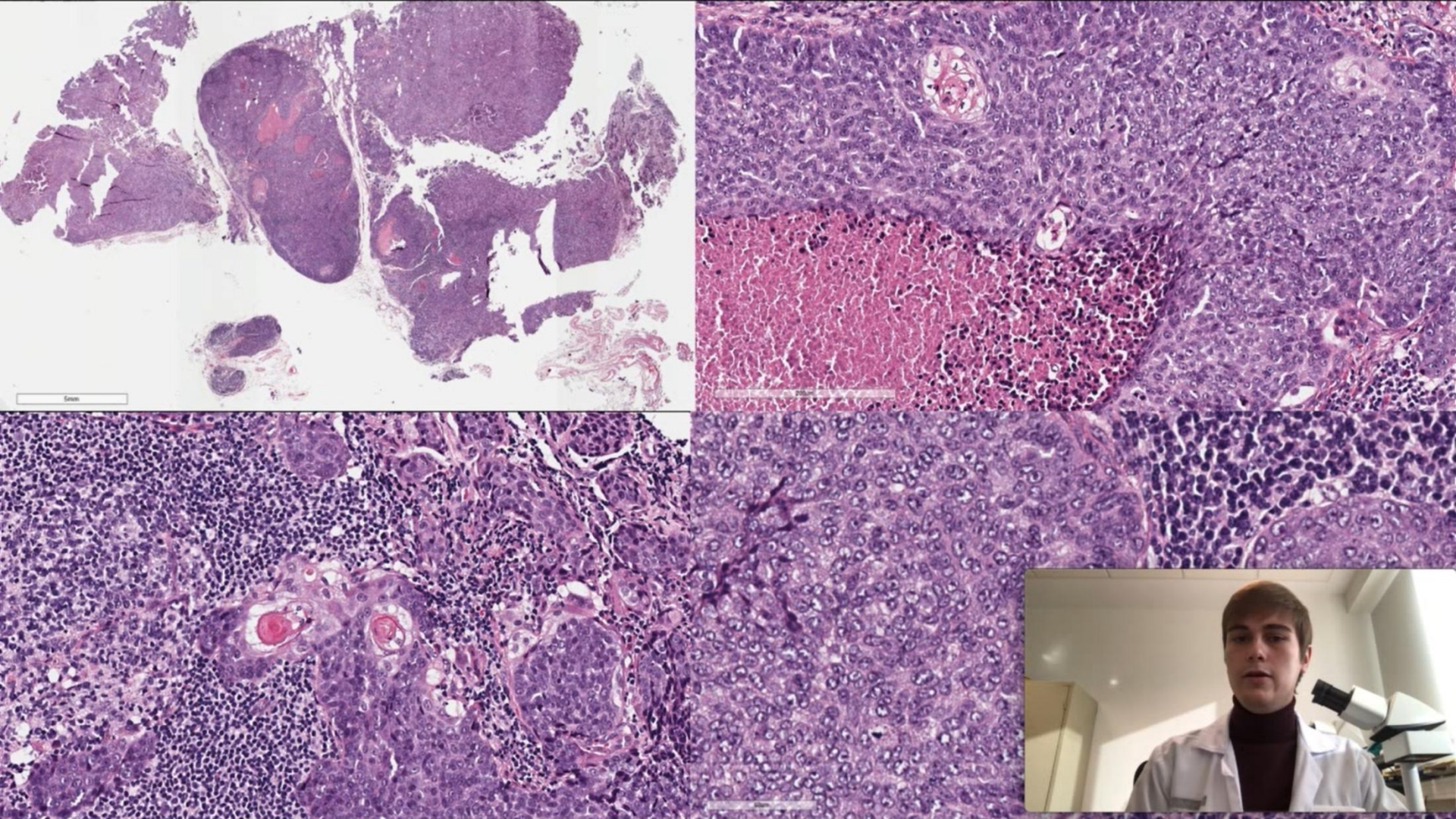

SOCIEDAD VALENCIANA
DE
ANATOMIA PATOLOGICA

La Fe
Hospital
Universitari
i Politècnic

NUT1

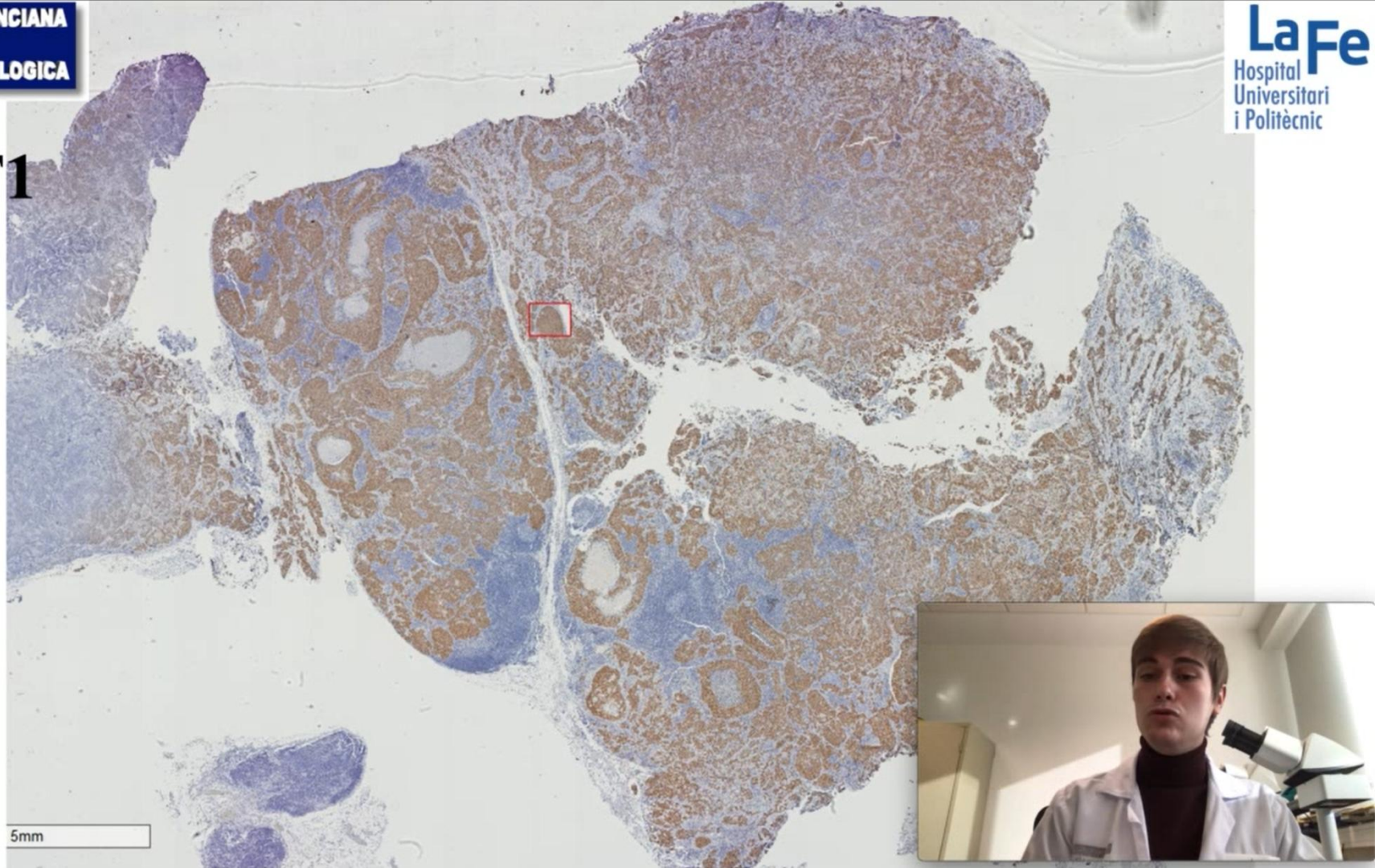

SOCIEDAD VALENCIANA
DE
ANATOMIA PATOLOGICA

La Fe
Hospital
Universitari
i Politècnic

NUT1

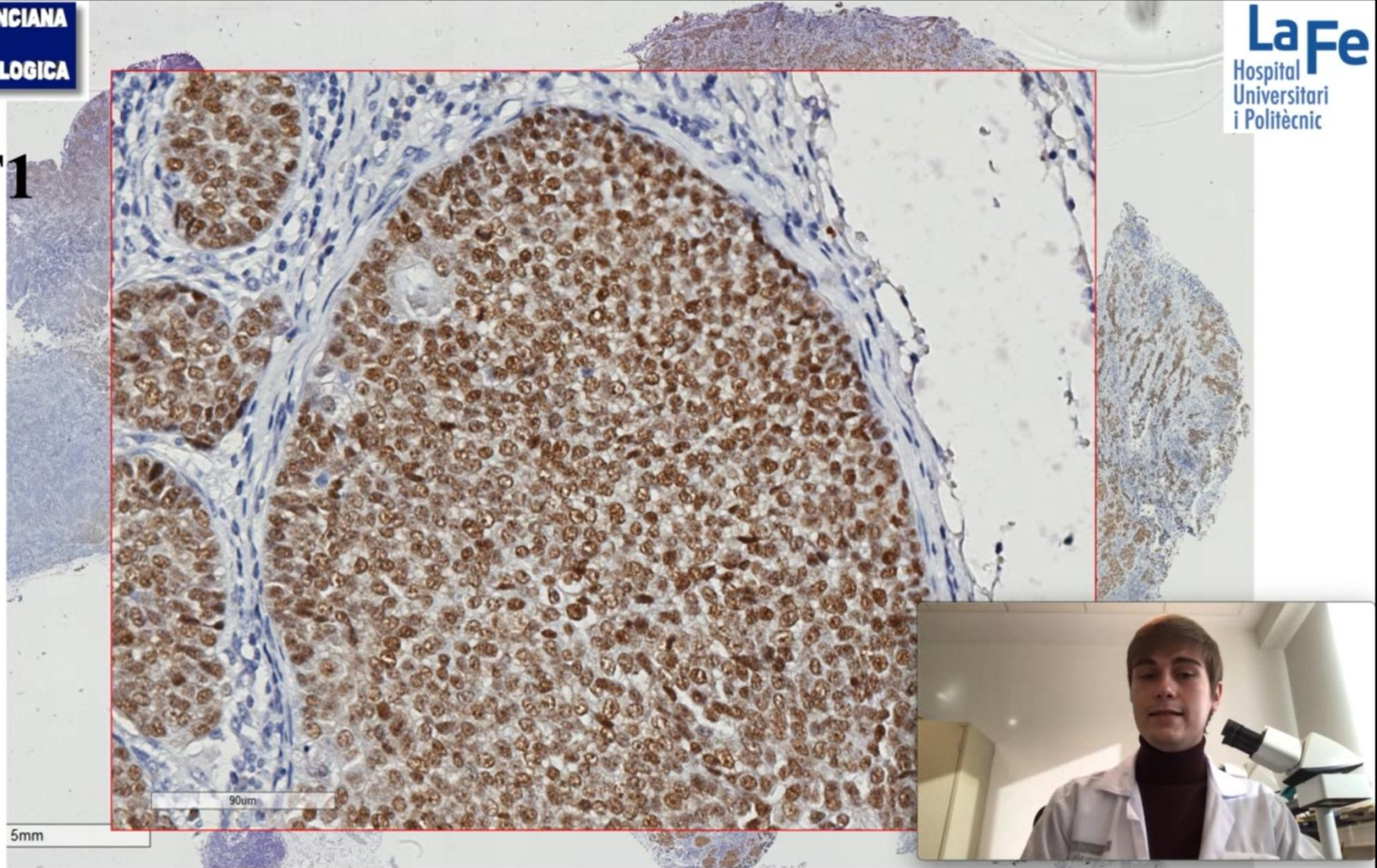

SOCIEDAD VALENCIANA DE ANATOMIA PATOLOGICA

La Fe Hospital Universitari i Politècnic

FISH NUT1

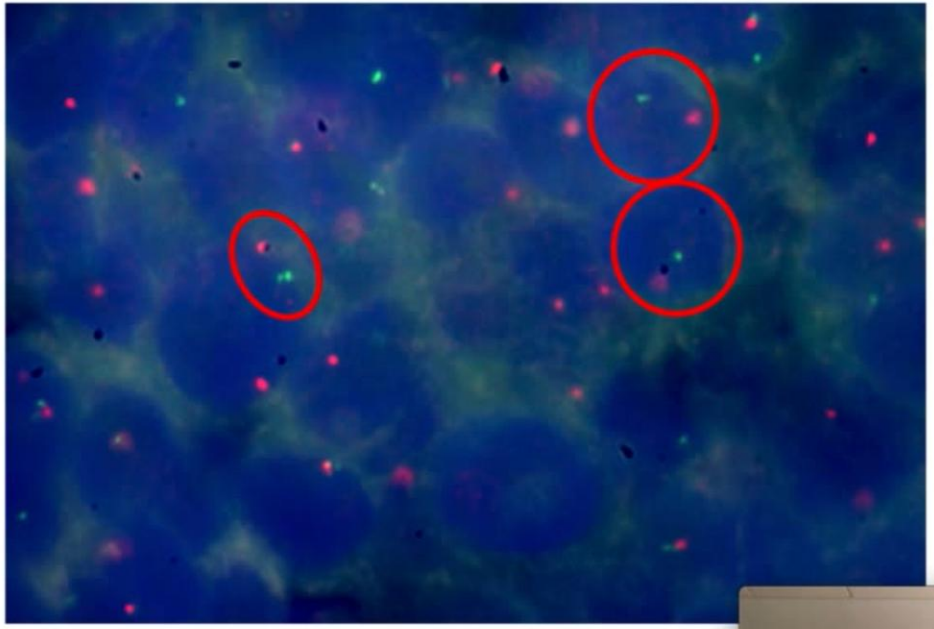

SOCIEDAD VALENCIANA DE ANATOMIA PATOLOGICA

La Fe Hospital Universitari i Politècnic

Carcinoma NUT

- Carcinoma muy agresivo.
- Suele diagnosticarse en jóvenes (media 21,9 años) (0,1-82 años).
- Etiología desconocida.
- No asociado a tabaquismo, HPV, VEB, ni otros virus.
- Localización a nivel de la línea media (sinusal, epiglotis, pulmón y mediastino).
- 50% presentan con metástasis en ganglios linfáticos.
- Indiferenciado o similar a carcinoma escamoso poco diferenciado.
- Puntos clave: focos abruptos de queratinización, alta activid
  zonas de necrosis.
- Translocación 15q14.

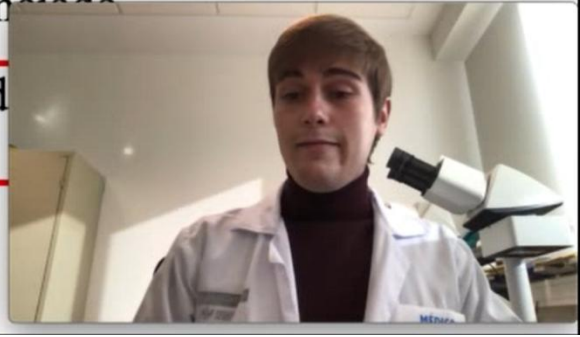

SOCIEDAD VALENCIANA
DE
ANATOMIA PATOLOGICA

La Fe
Hospital
Universitari
i Politècnic

Muchas gracias