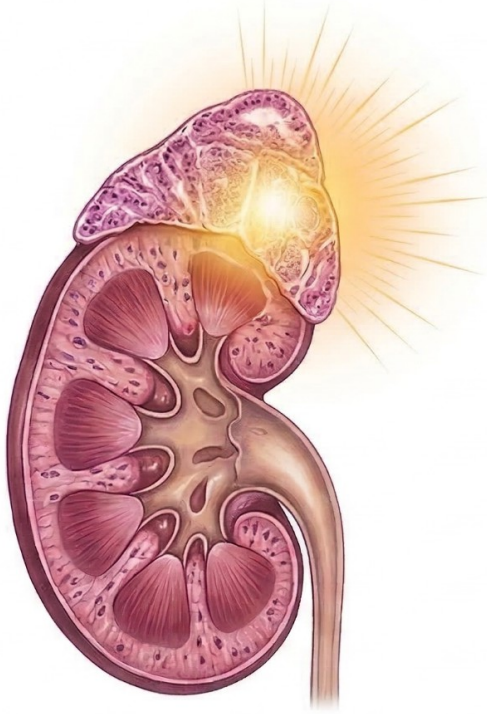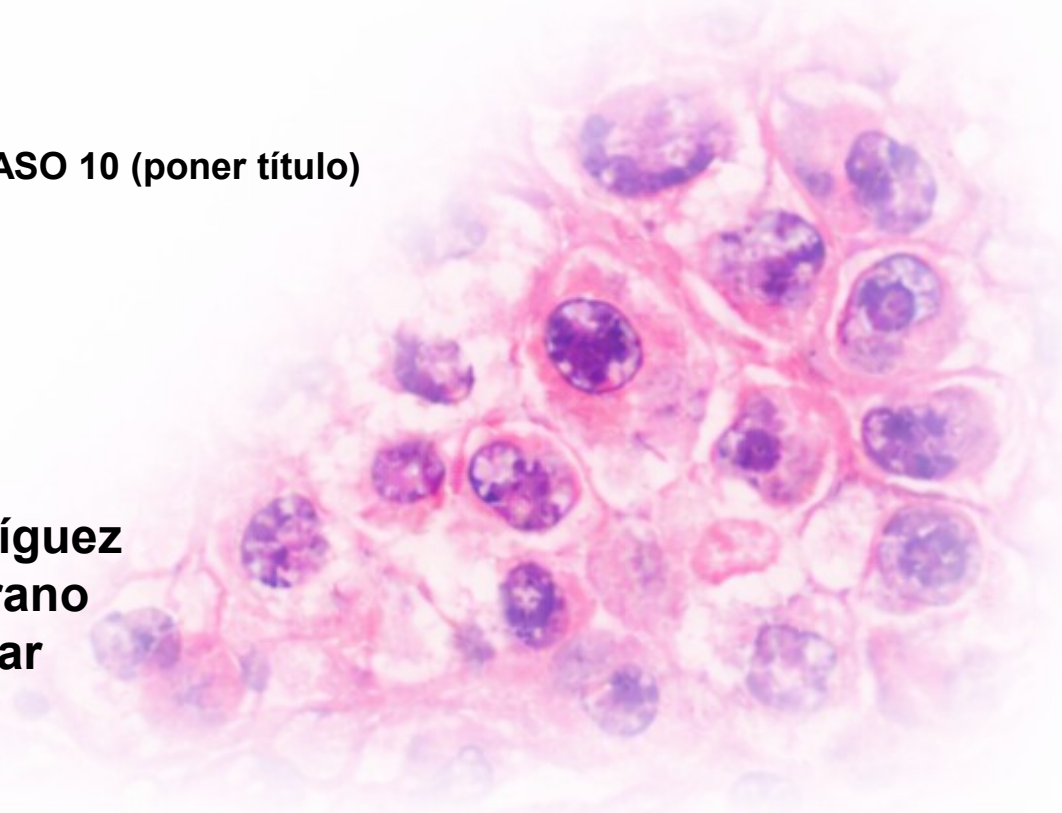


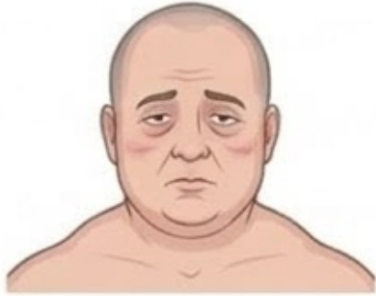CASO 10 (poner título)

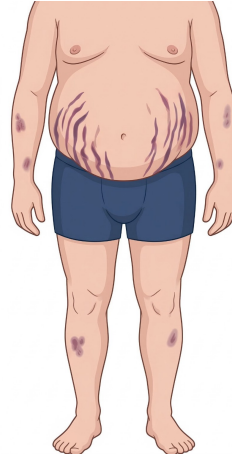**Shalygina S, Gracia Sáenz L, Rodríguez
Morel JA, Niveiro de Jaime M, Serrano
Gotarredona J, Volar Volar L, Melgar
Requena P, Peiró Marqués FM.**



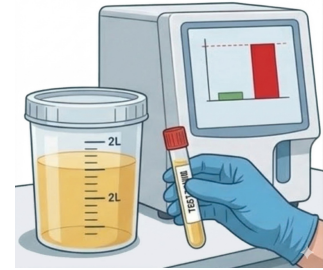PRESENTACIÓN CLÍNICA



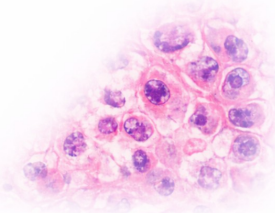
Varón, 43 años



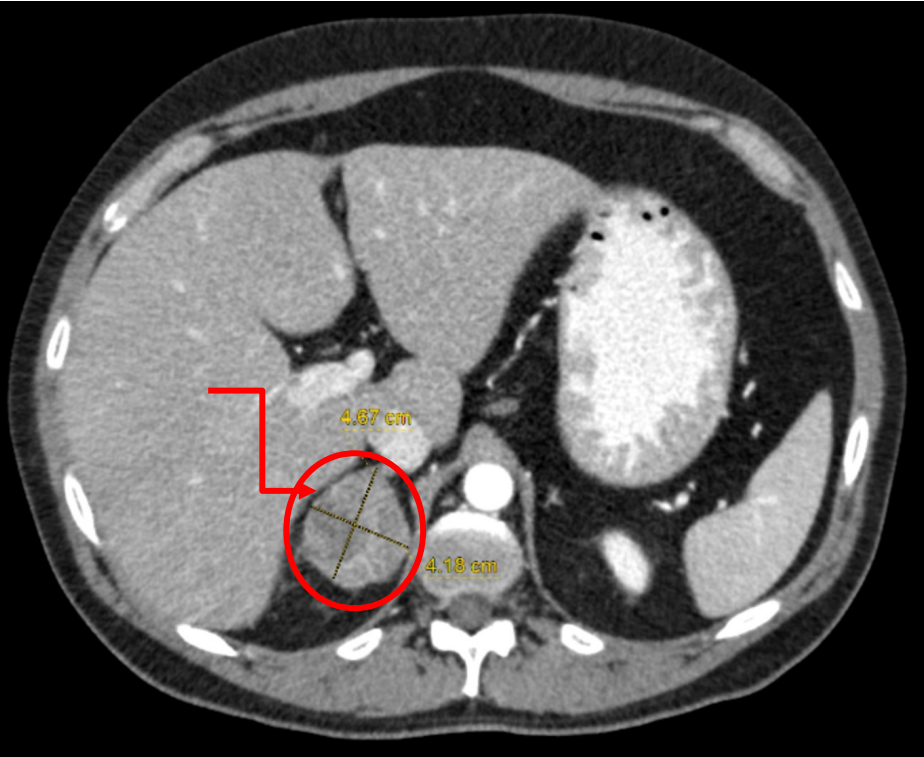
- **Síndrome de Cushing**
florido
- **HTA** refractaria (3
meses)



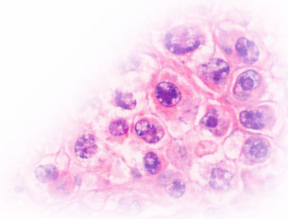
Cortisol urinario: **>1280**
µg/24h (58 - 403)



RADIOLOGÍA



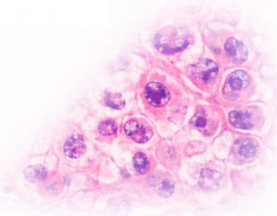
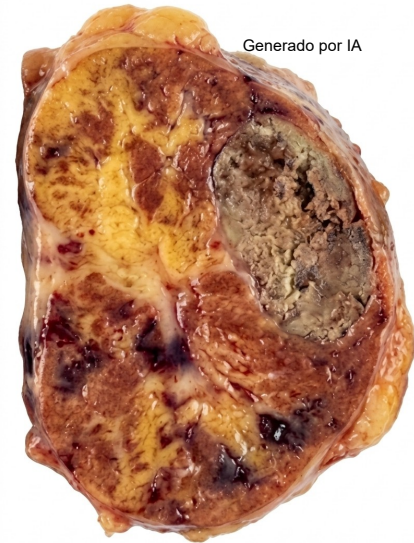
- Masa suprarrenal derecha (4,7 cm)
- Invasión de VCI
- Adenopatías retrocavas sospechosas

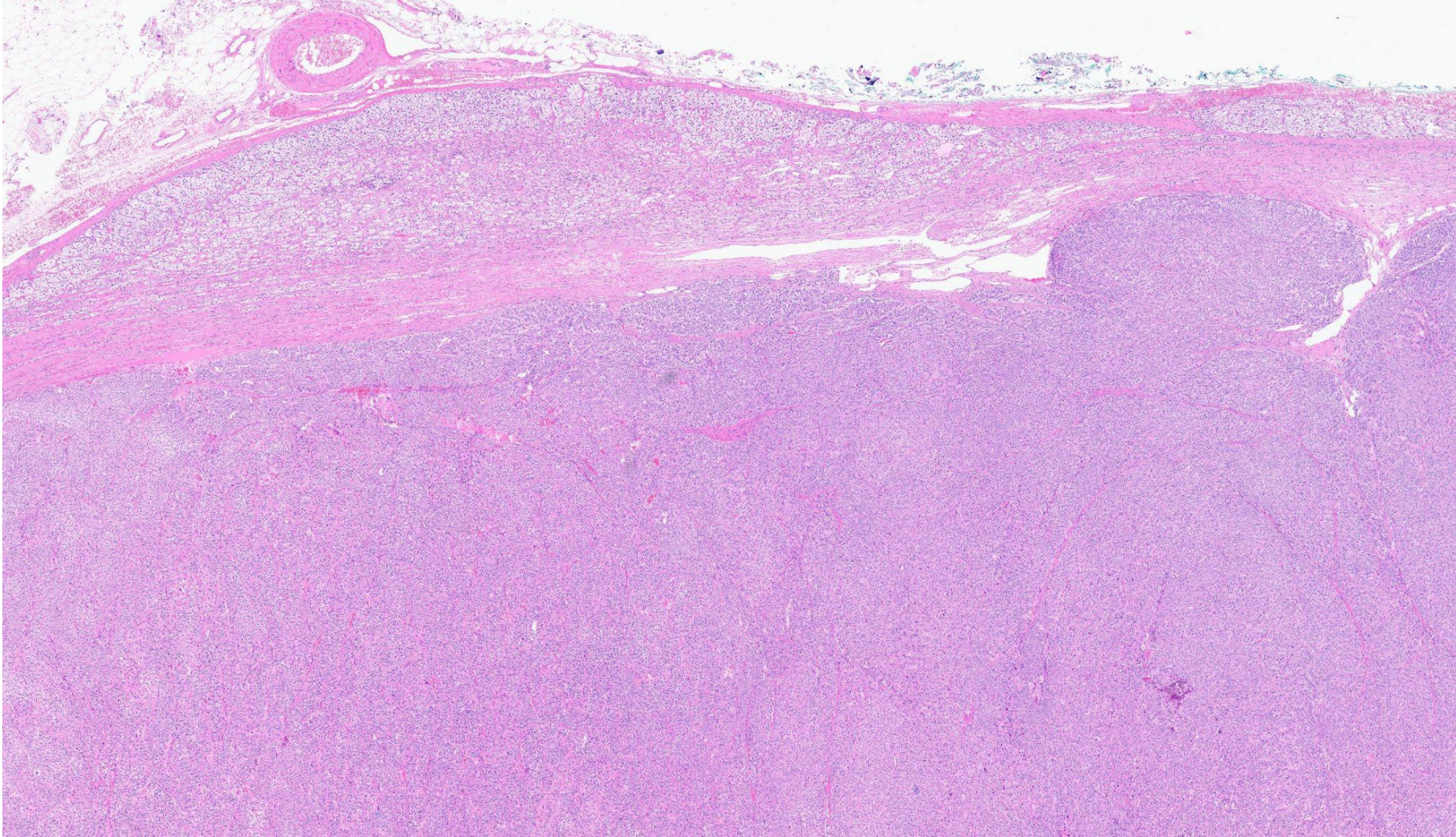


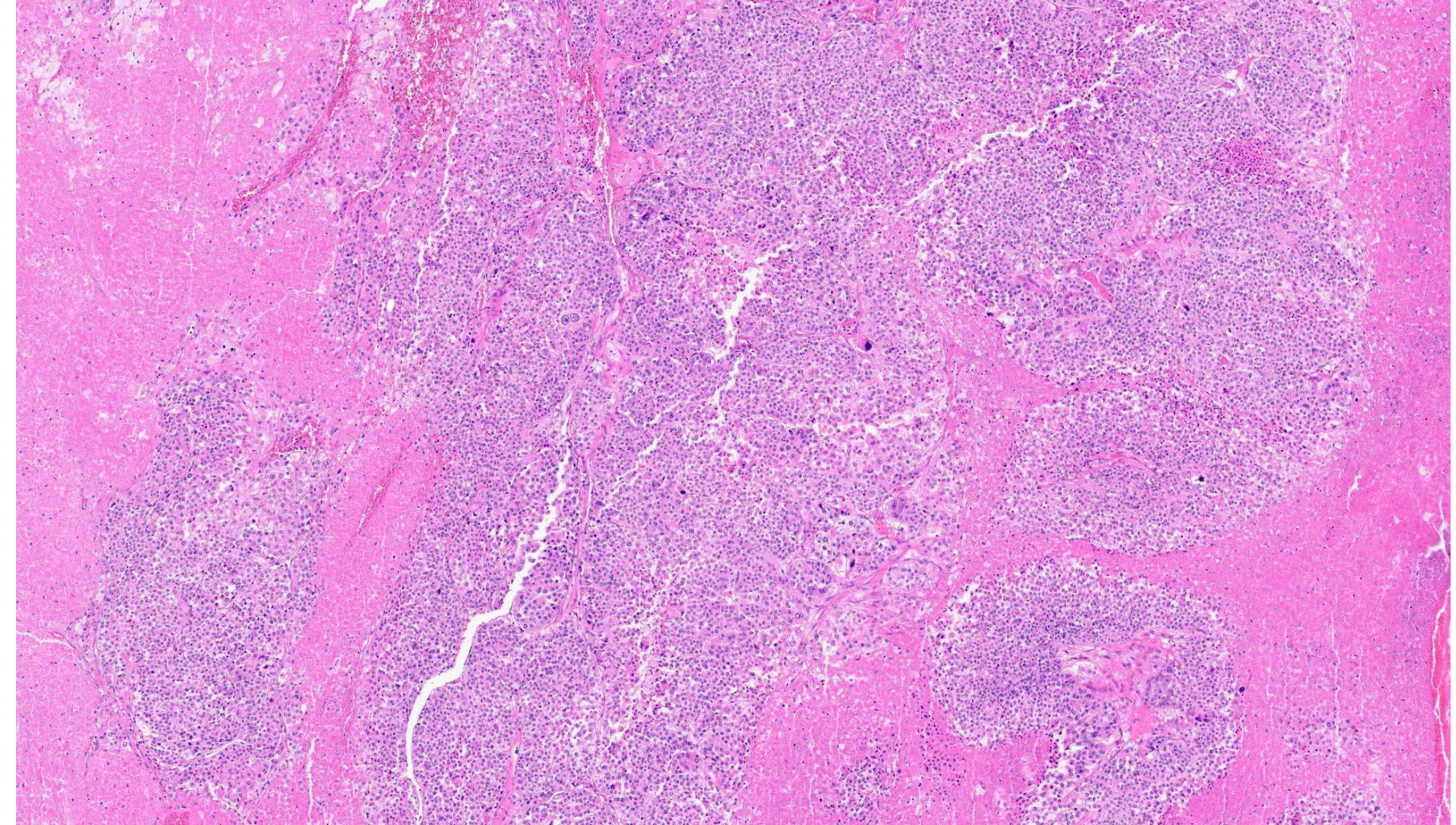
MACROSCOPIA

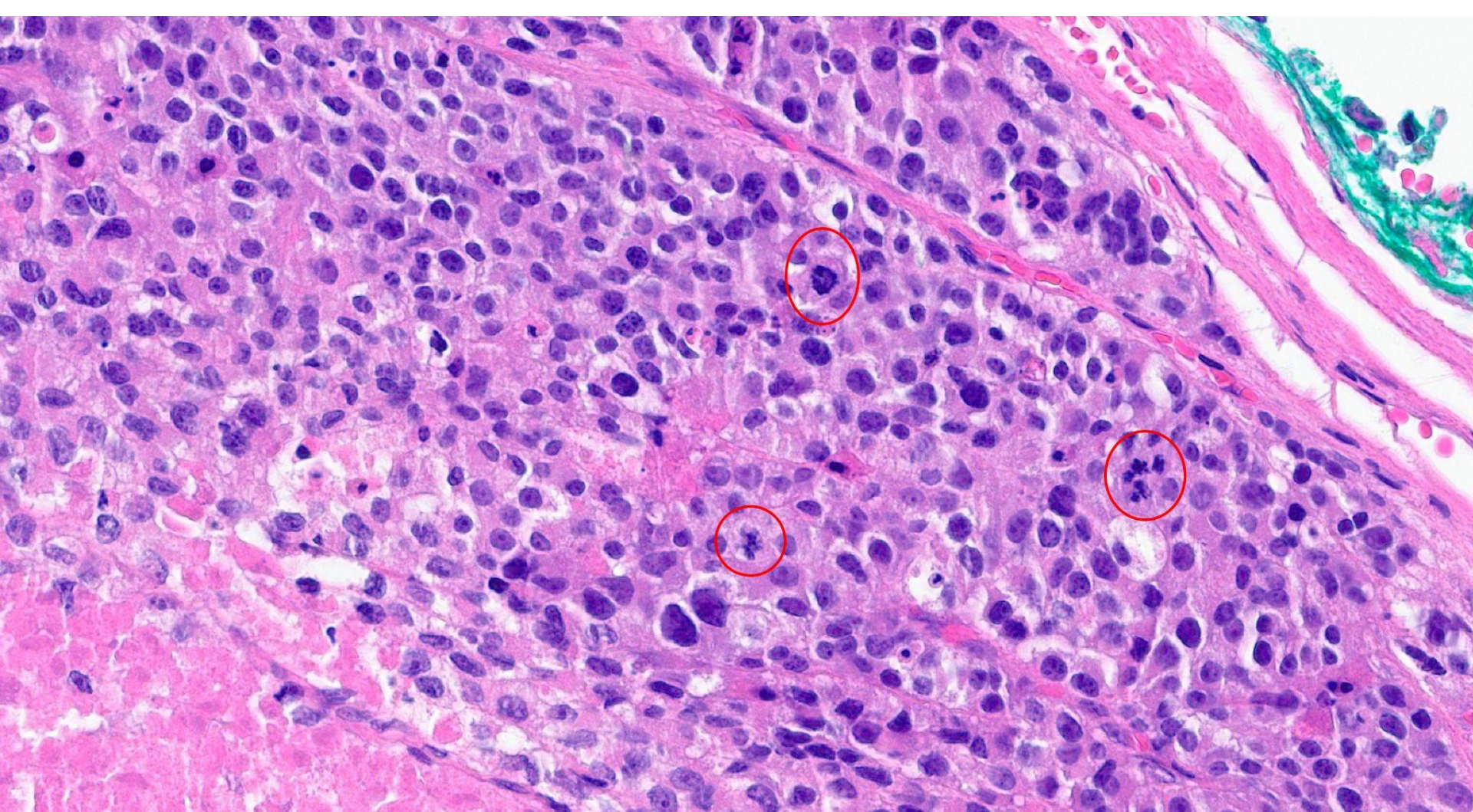
Adrenalectomía derecha

- Tamaño: 8 cm
- Peso: 90 g
- Necrosis subcapsular (5,5 cm)
- Focos de hemorragia





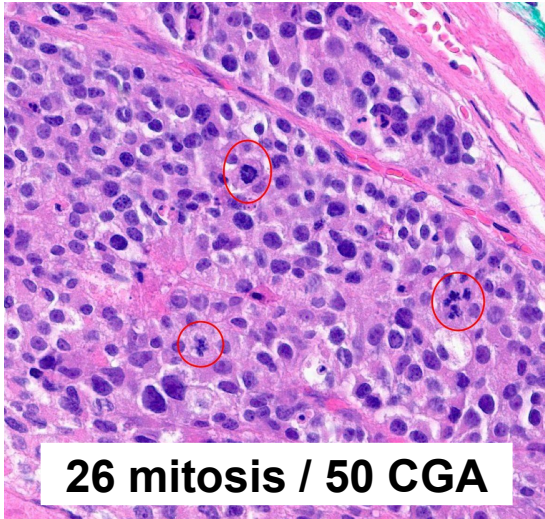




TUMORES ADRENOCORTICALES

Convencionales

CRITERIOS
CLÁSICOS DE WEISS



Oncocíticos

CRITERIOS LIN-WEISS-BISCEGLIA

Crterios mayores
(≥ 1 → carcinoma):

- Actividad mitótica \uparrow ($>5/50$ CGA) ✓
- Mitosis atípicas ✗
- Invasión venosa ✗

Crterios menores:

- Tamaño > 10 cm ✗
- Peso > 200 g ✗
- Necrosis tumoral ✓
- Invasión capsular ✓
- Invasión sinusoidal ✓

HELSINKI SCORE

Recuento
mitótico

26 / 50 CGA

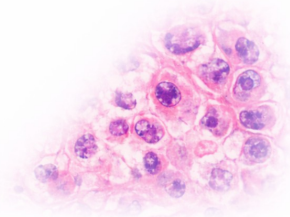
Necrosis
tumoral
presente

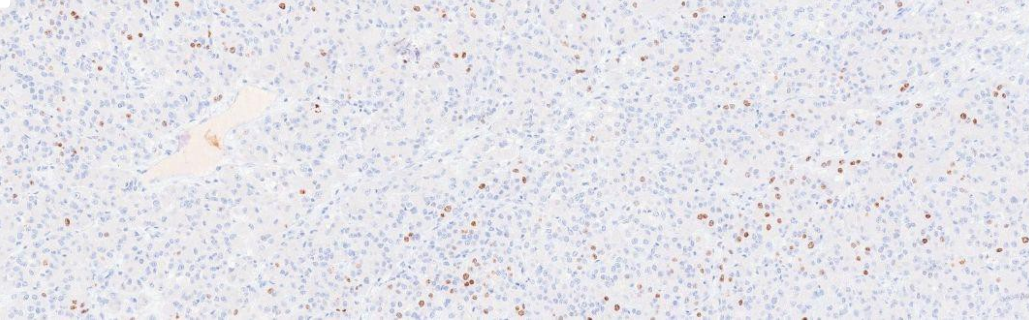
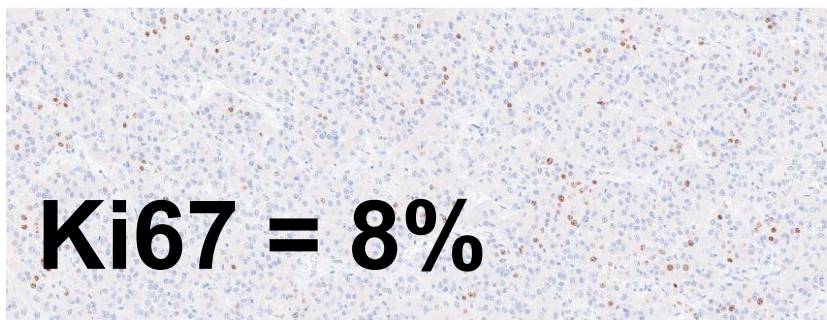
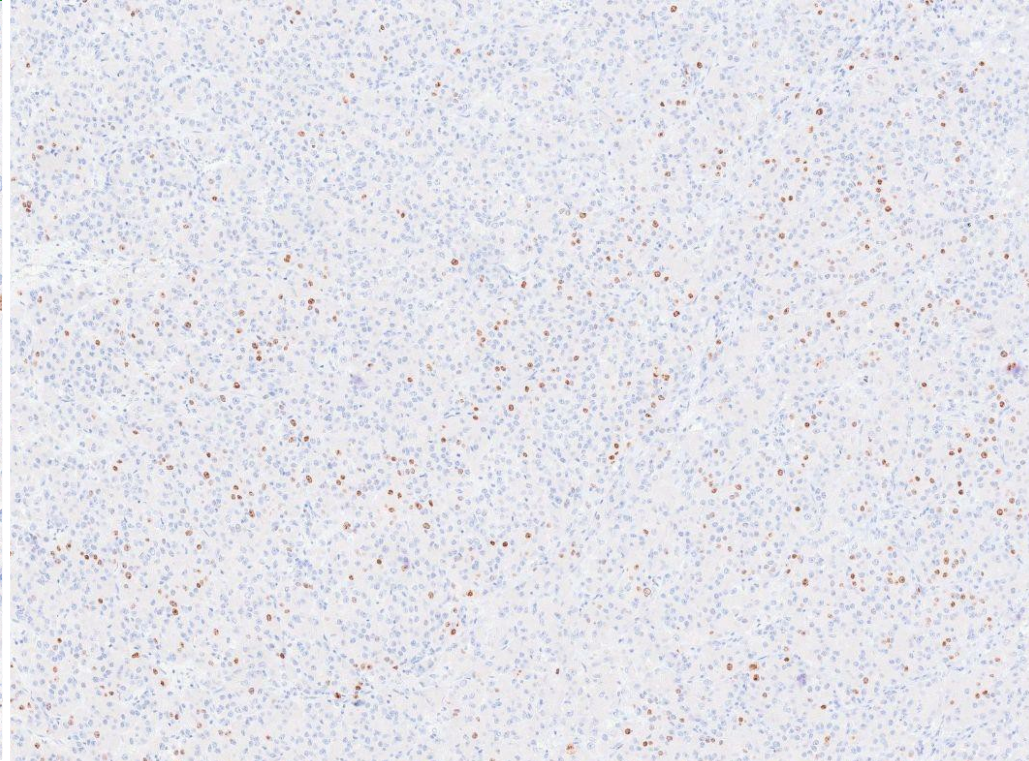
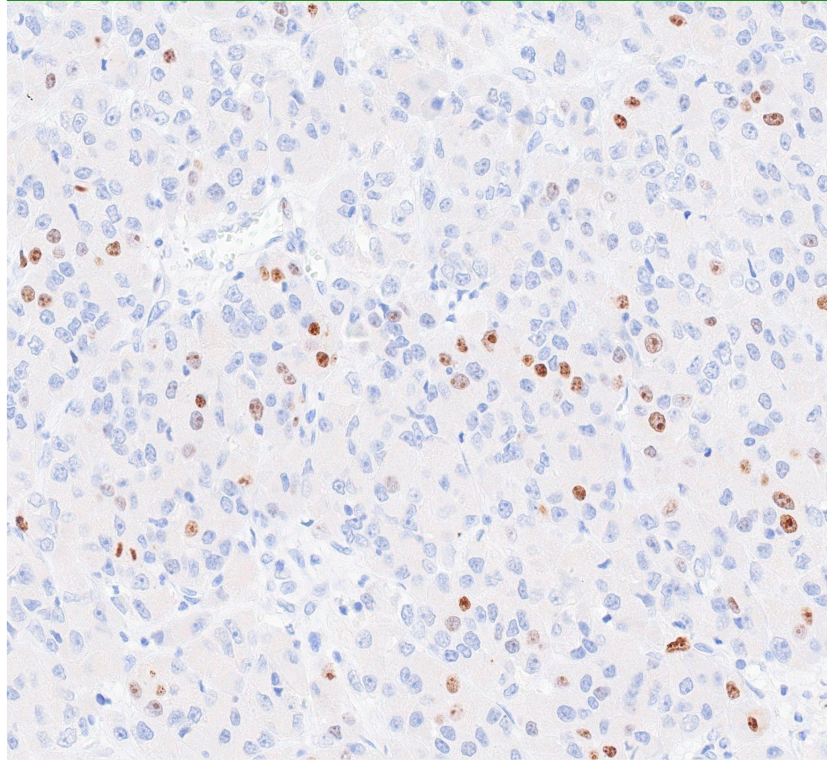
Hotspot Ki67

60%

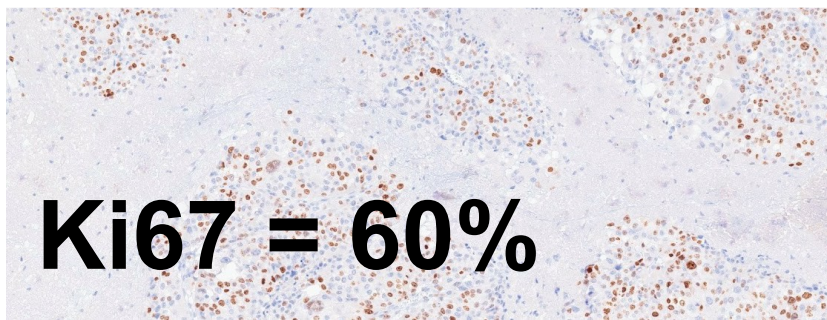
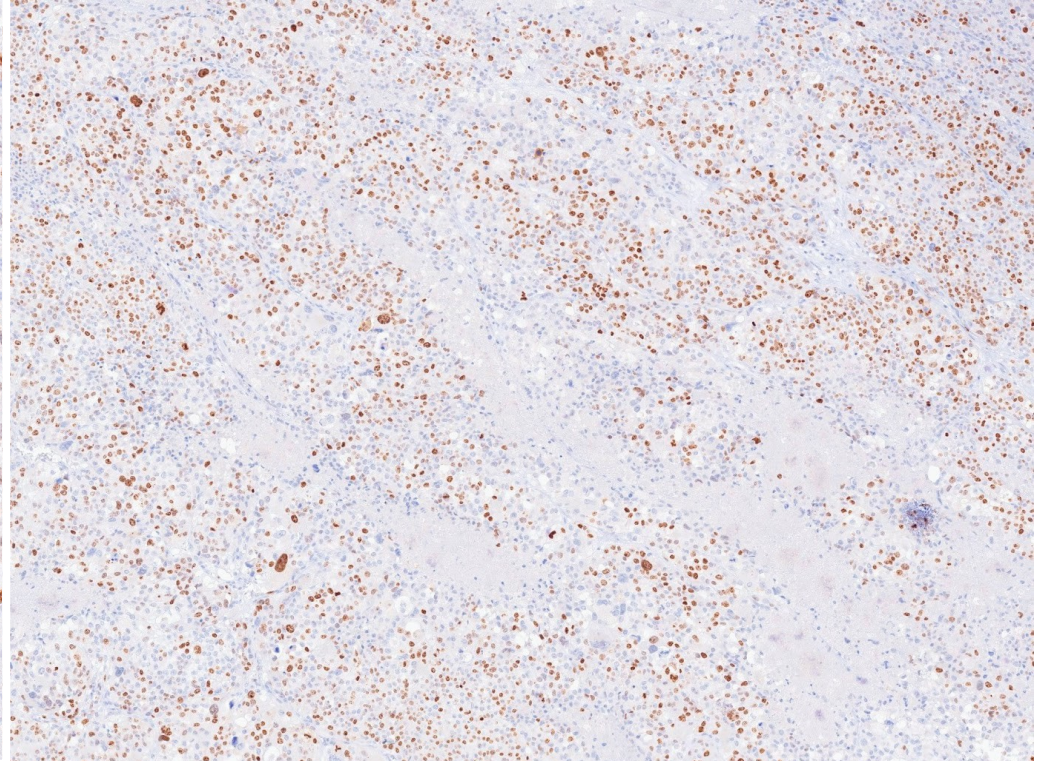
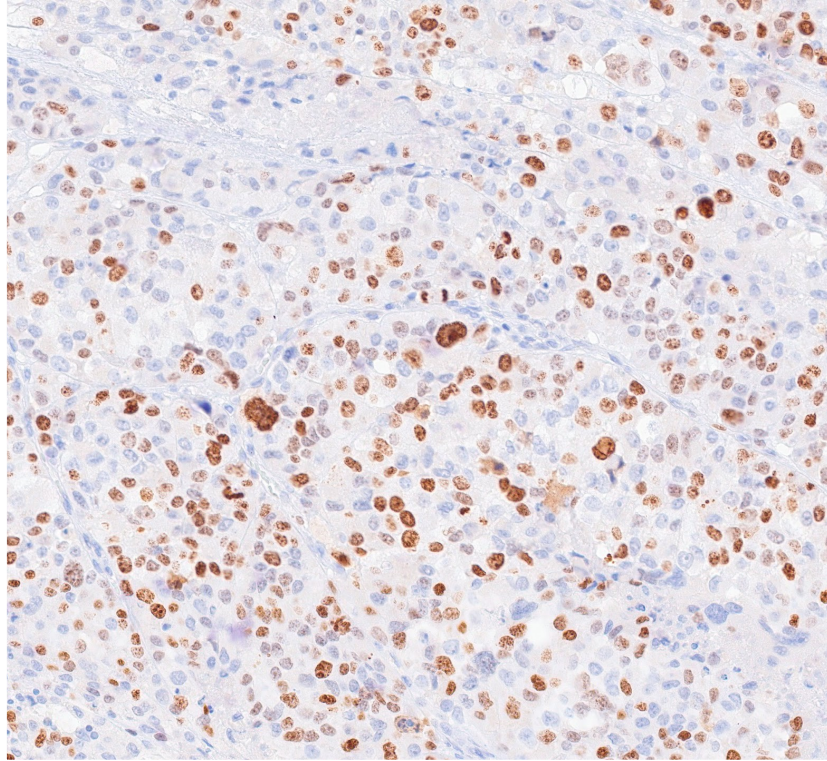
Cut-off 8,5 → mal pronóstico

Nuestro caso: 68





Ki67 = 8%



Ki67 = 60%



The image displays a high-magnification view of brain tissue stained for Synaptophysin. The tissue exhibits a complex, interconnected network of brown-stained structures, likely representing synaptic vesicles and axons. The staining is dense and widespread, covering most of the field of view. The background is a light, pale color, providing a clear contrast for the brown-stained structures. The overall appearance is that of a highly organized neural network.

Sinaptofisina



SF1

NGS REPORT

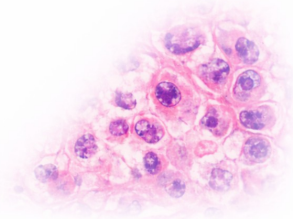
mutación patológica
en *TP53* (c.375+1G>C)



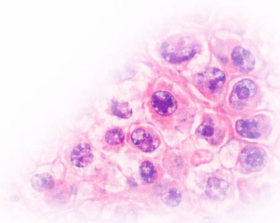
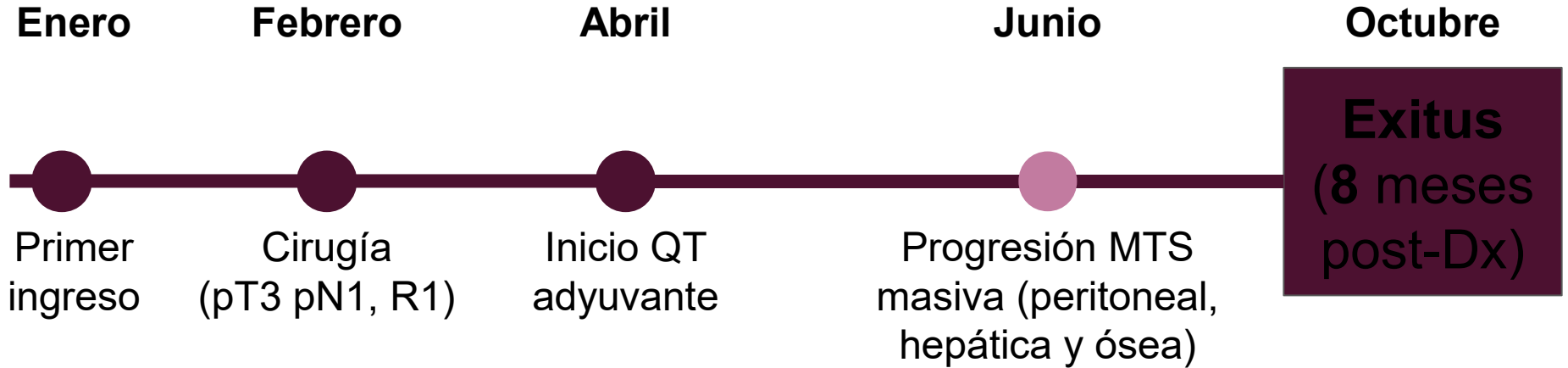p53

INTEGRACIÓN DIAGNÓSTICA

- **CARCINOMA ADRENOCORTICAL, VARIANTE ONCOCÍTICA**
- **ALTO GRADO (26 mitosis / 50 CGA)**
- **INVASIÓN CAPSULAR CON EXTENSIÓN A GRASA PERIADRENAL**
- **METÁSTASIS GANGLIONARES (4/4)**
- **pT3 pN1**



EVOLUCIÓN CLÍNICA



CONCLUSIONES




Engaño macroscópico

Tamaño y peso conservados (<10 cm, <200 g) no descartan alta agresividad en la variante **oncocítica**



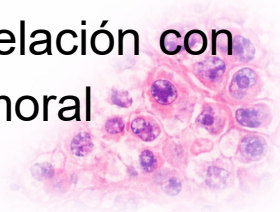Limitaciones de Lin-Weiss-Bisceglia

Sistema útil para diagnóstico, pero limitado para estimar el comportamiento biológico



Valor de parámetros cuantitativos

Ki67 (hotspot) y Helsinki score: mejor correlación con la agresividad tumoral



**MUCHAS
GRACIAS!**

