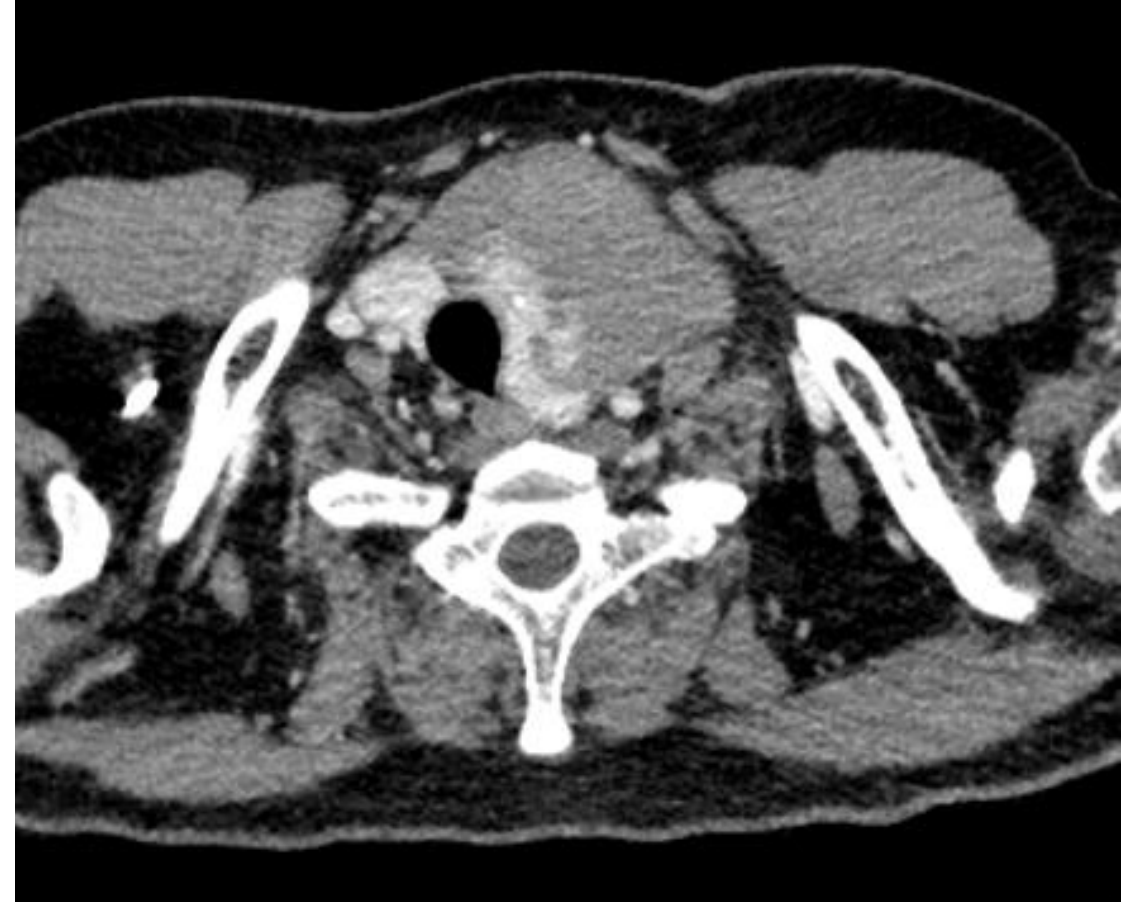

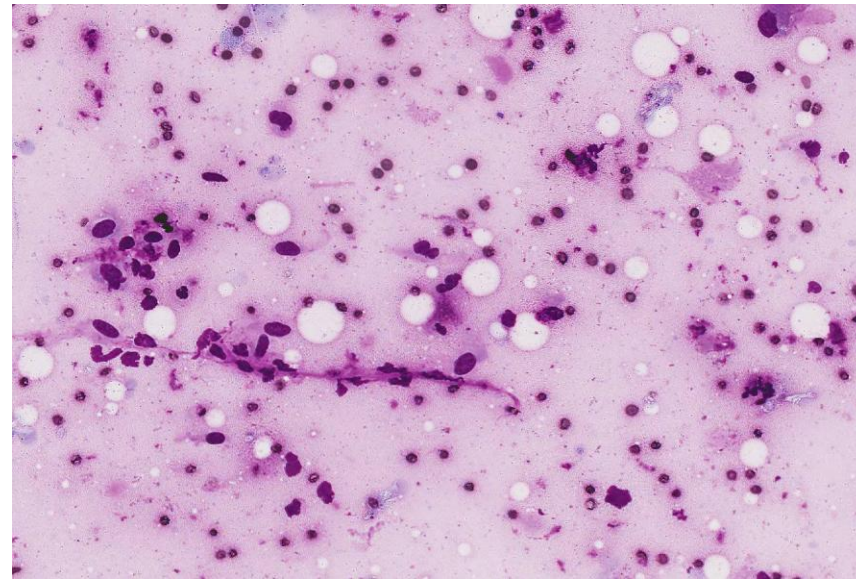
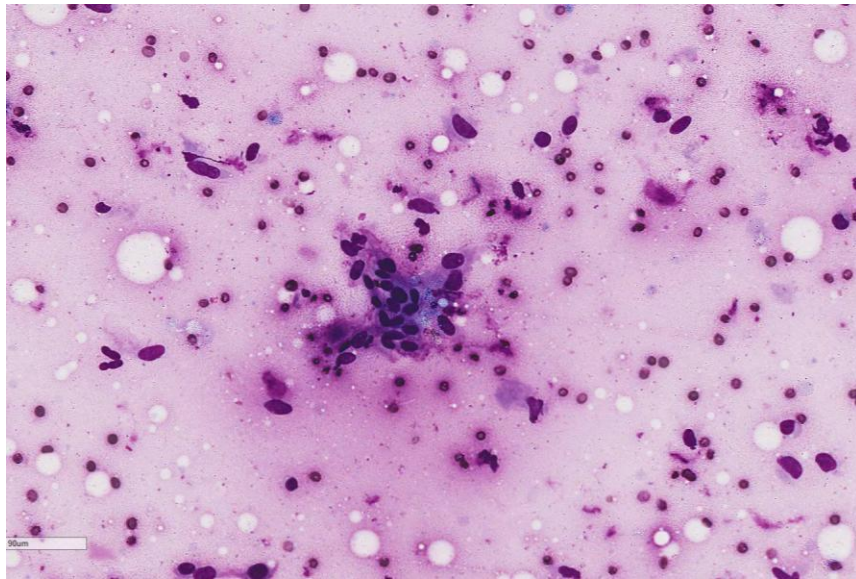
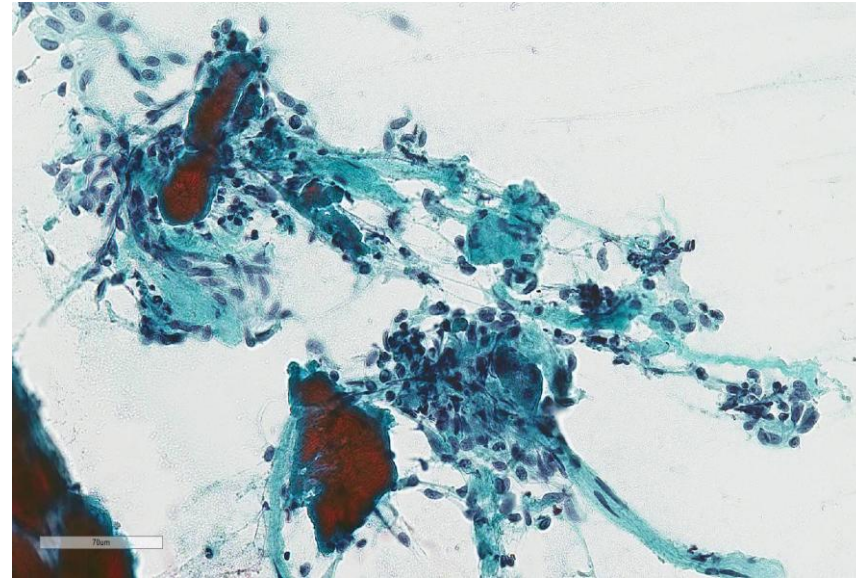
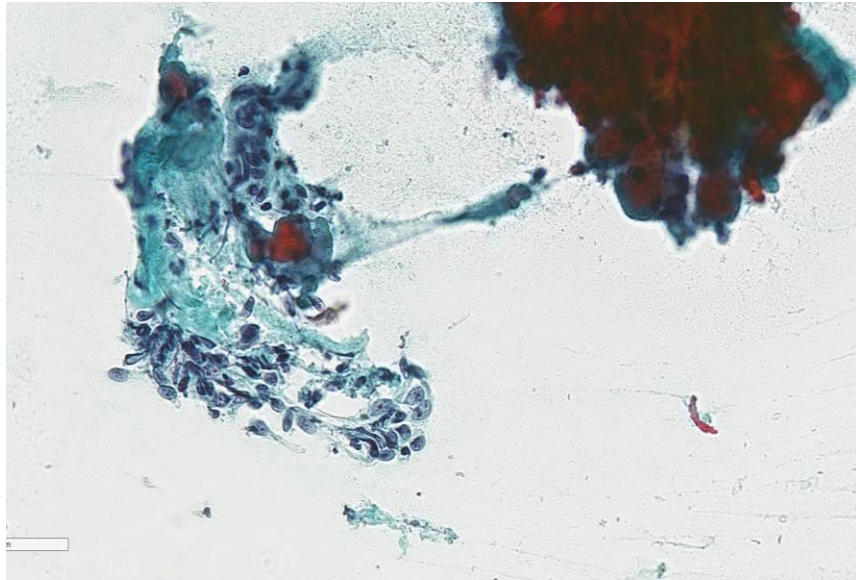
CASO 4

Judith González López

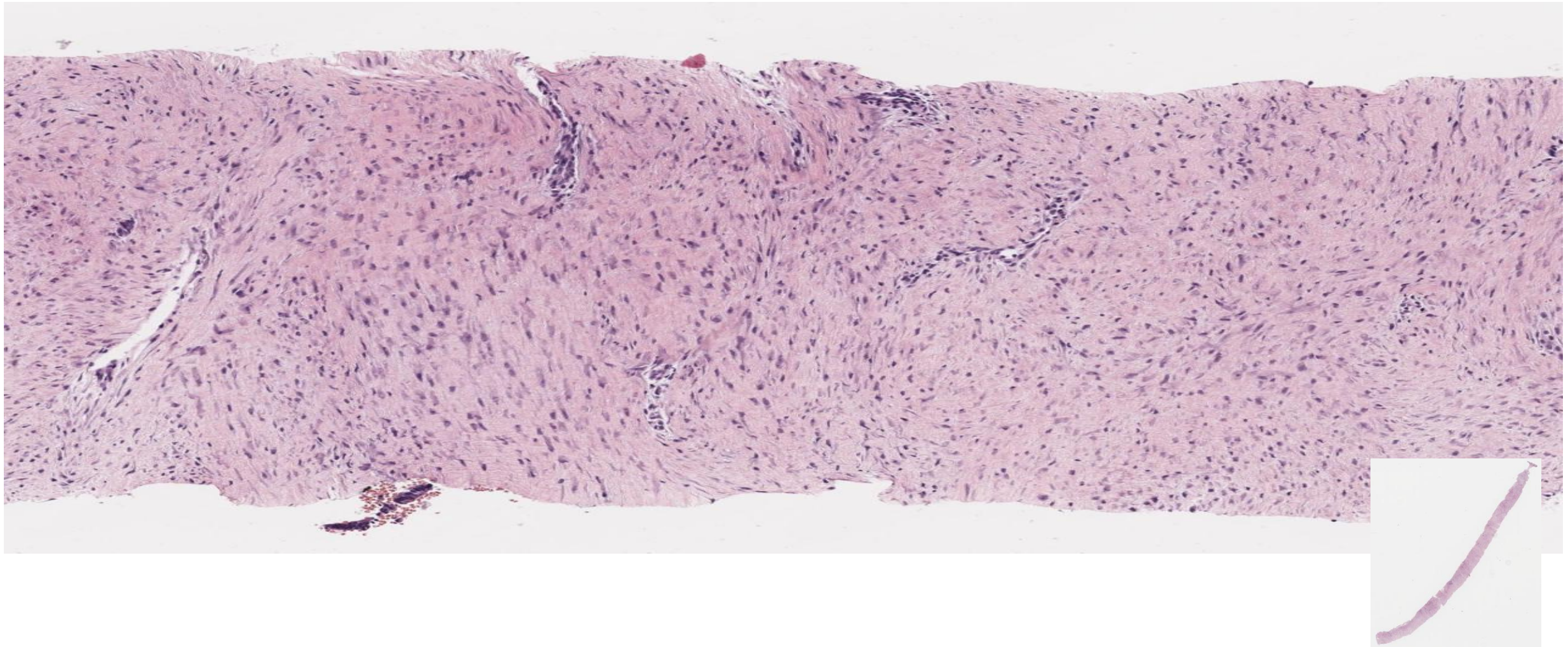
- Varón 36 años.
- Antecedentes familiares: Múltiples carcinomas tiroideos por línea materna.
- Consulta por masa cervical indurada adherida a planos profundos y disnea.
- TC: Tumoración en lóbulo tiroideo izquierdo de 6,5 x 5,3 x 7 cm con infiltración de músculos anteriores y adenopatías izquierdas cervicales, supraclaviculares y mediastínicas altas.
- PET-TC: Masa cervical y ganglios laterocervicales, supraclavicular y paratraqueal alto izquierdos.



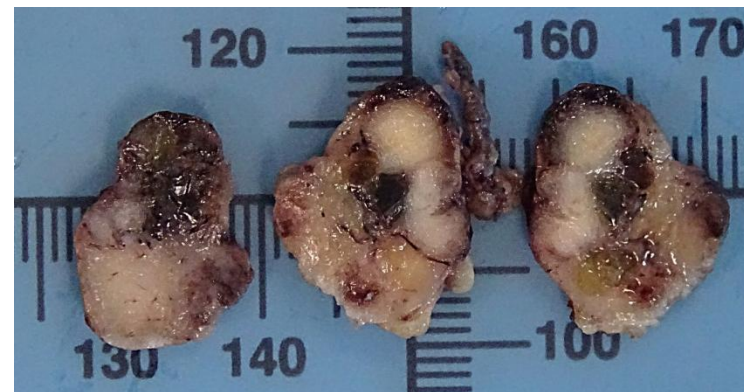
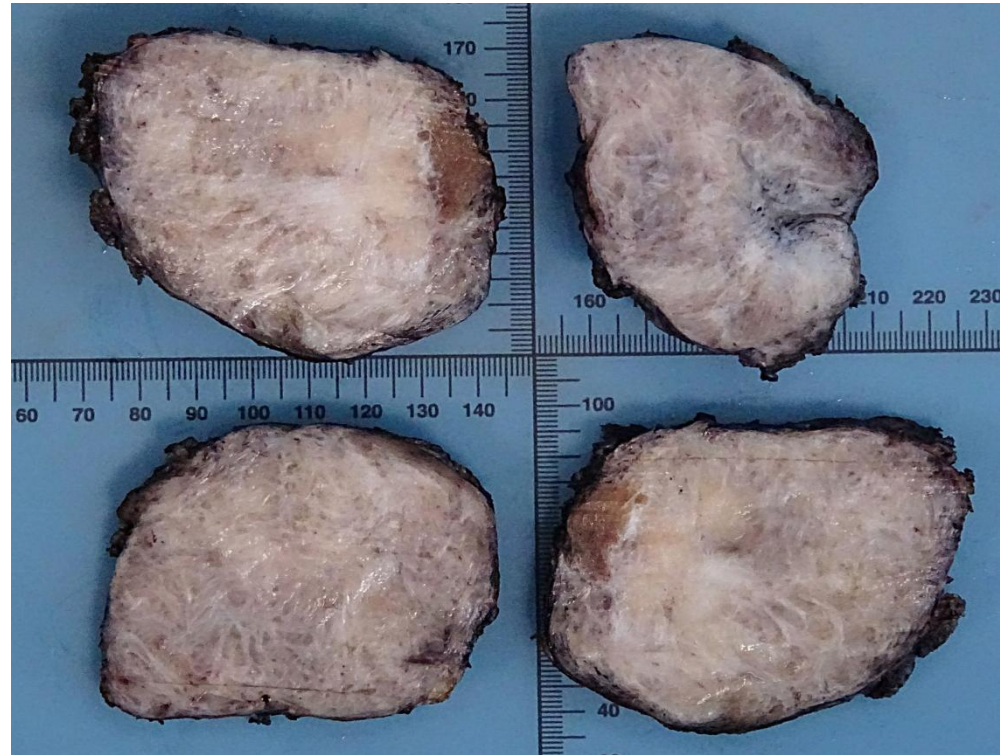
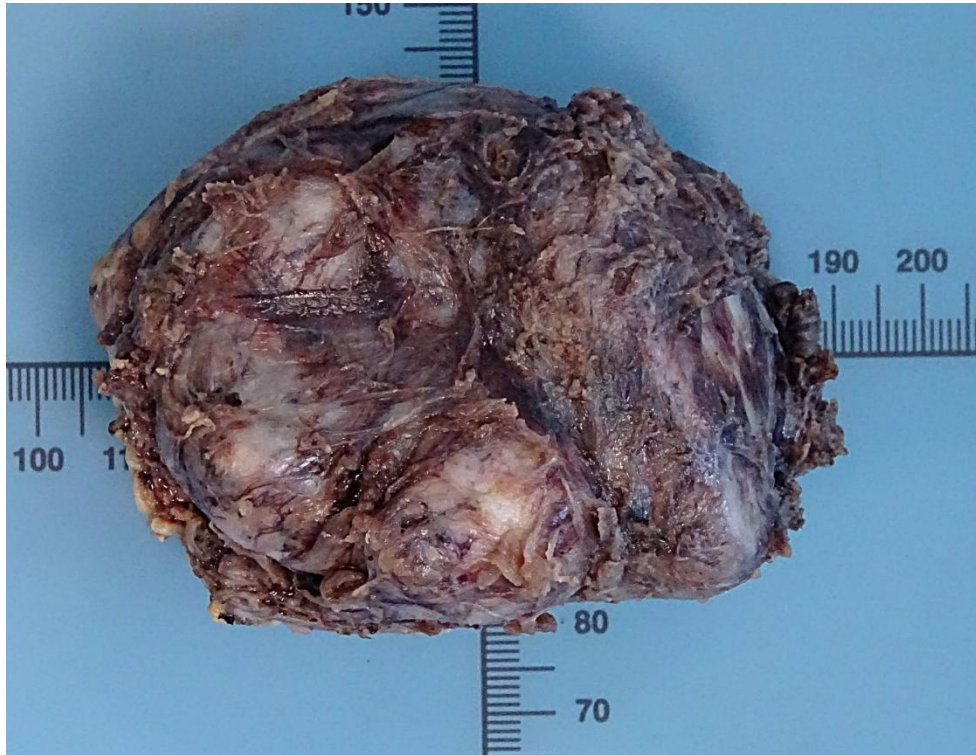
PUNCIÓN ASPIRACIÓN CON AGUJA FINA (PAAF)



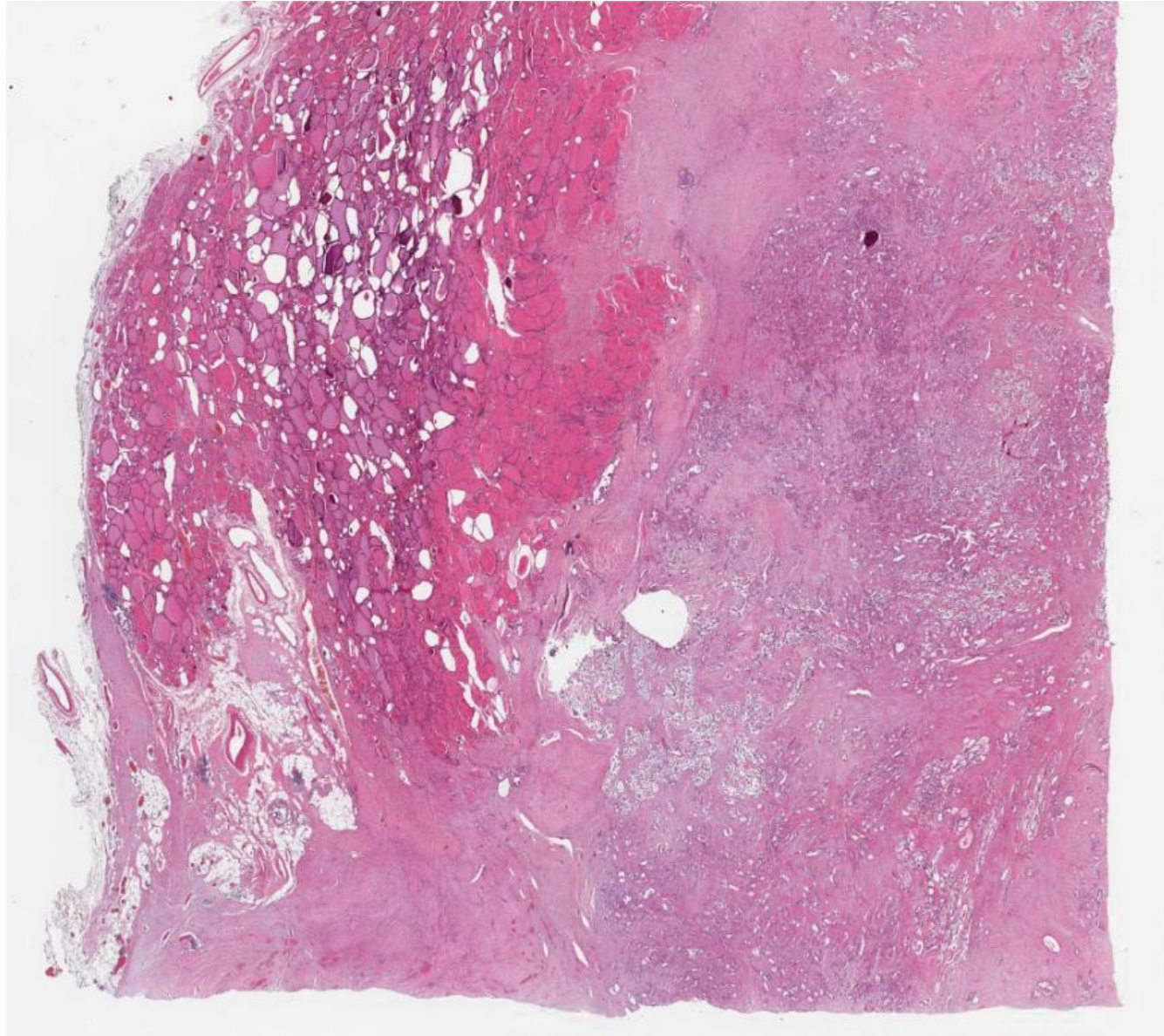
BIOPSIA CON AGUJA GRUESA (BAG)


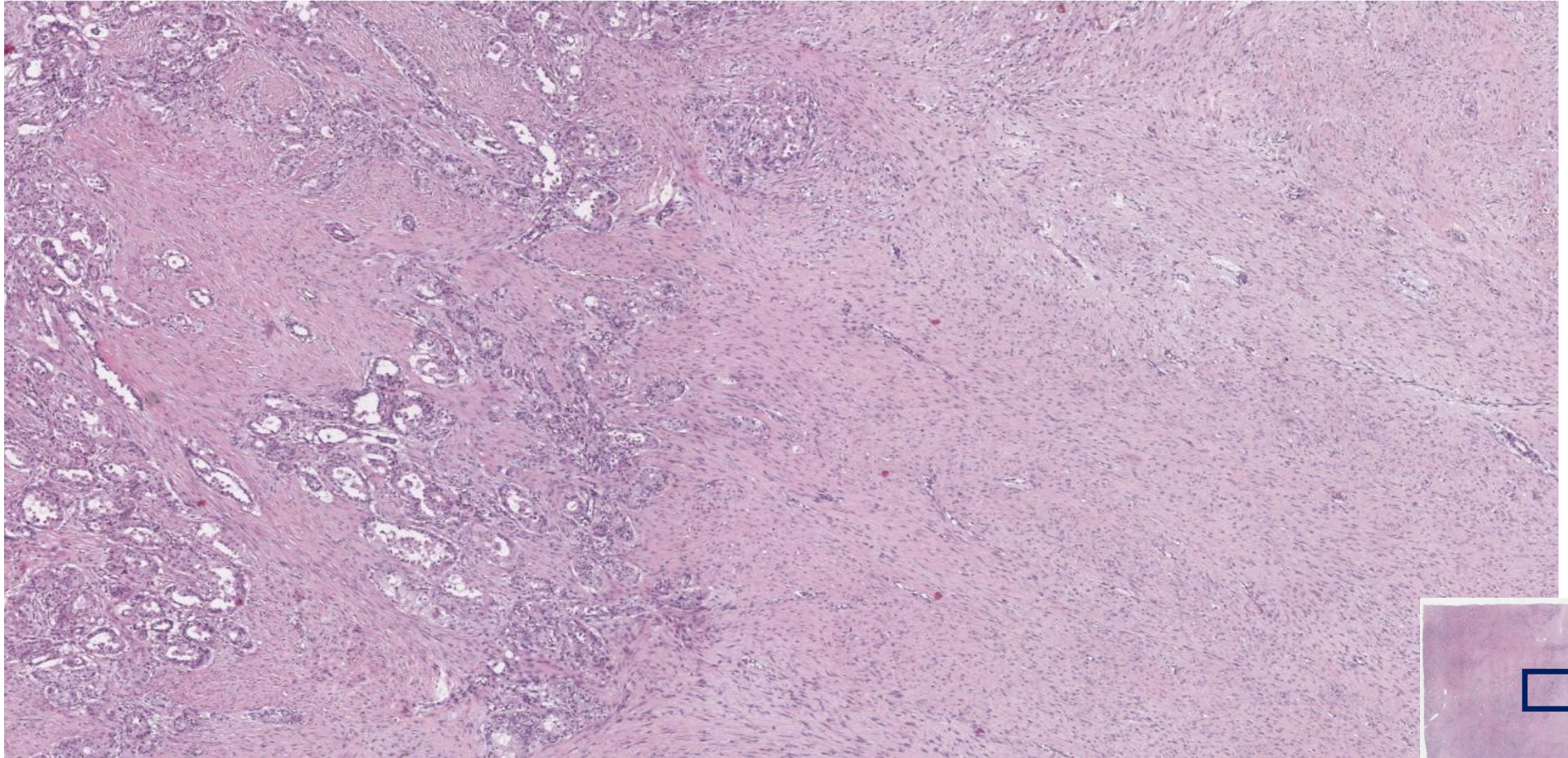


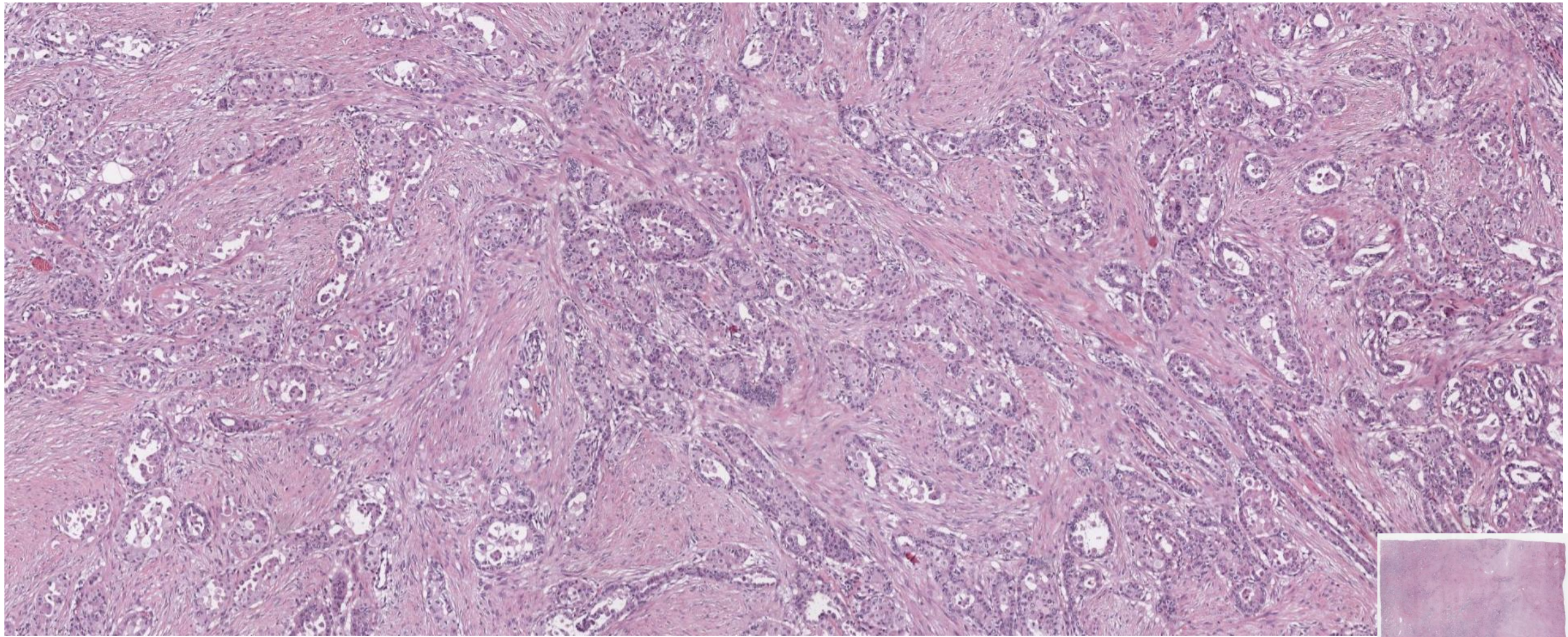
HALLAZGOS MACROSCÓPICOS

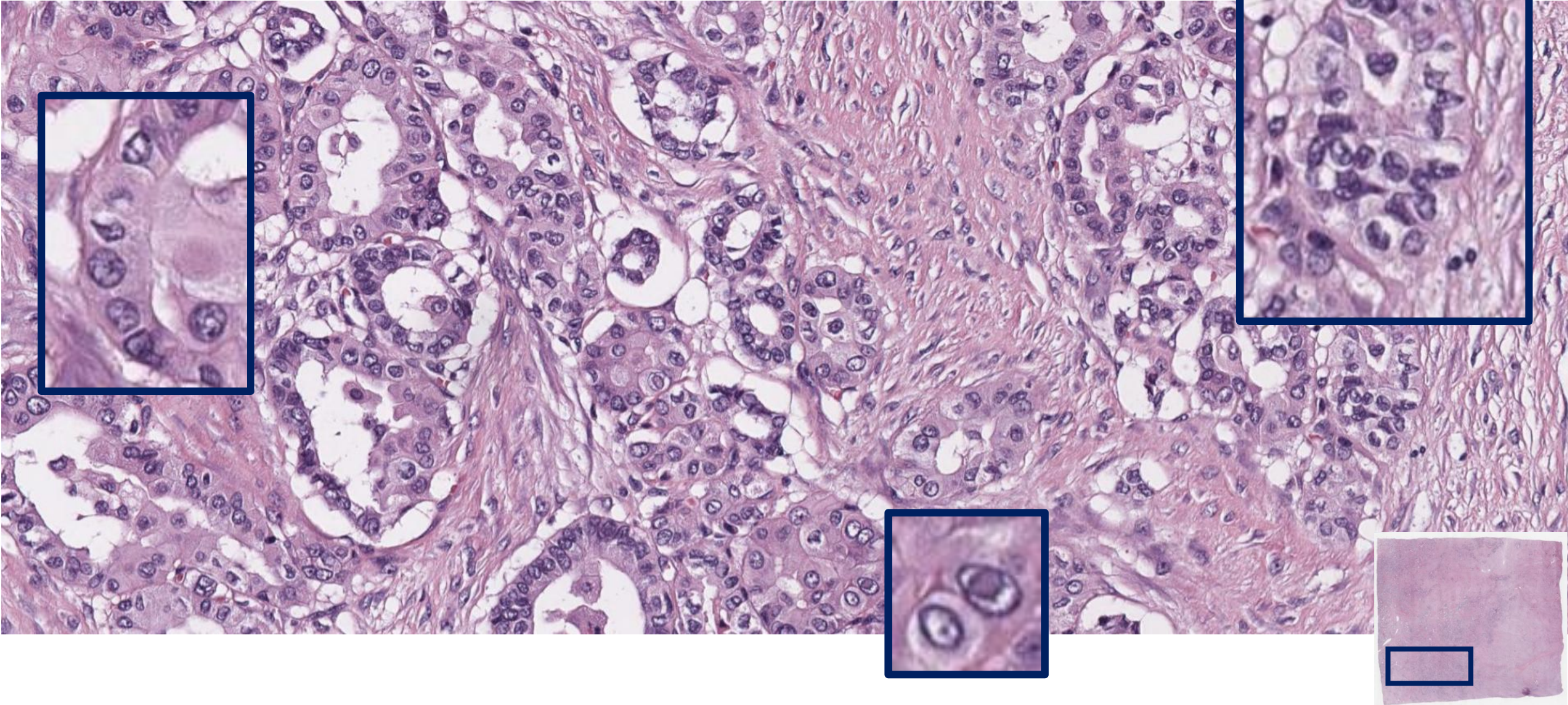


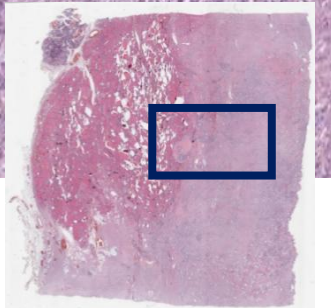
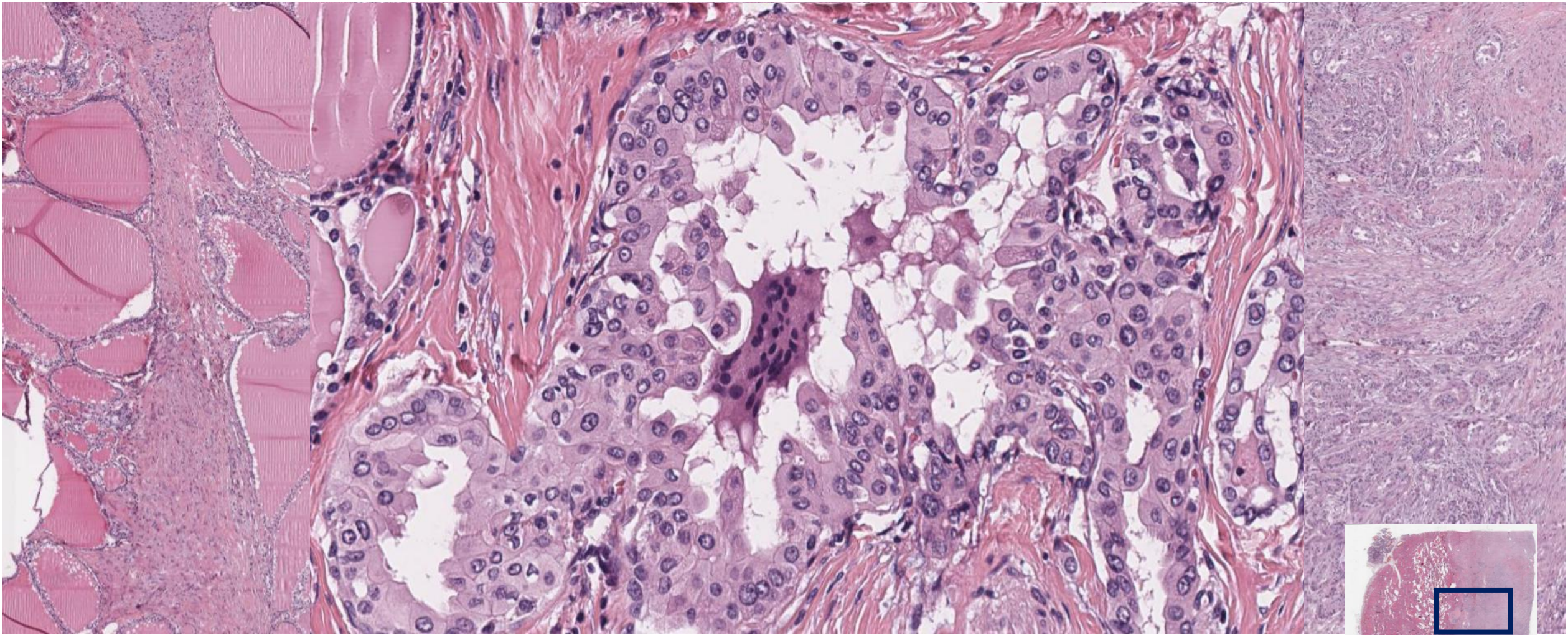
HALLAZGOS MICROSCÓPICOS



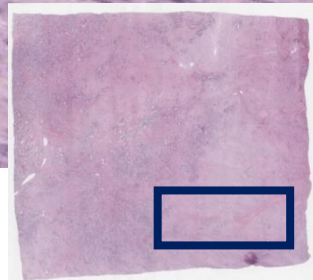
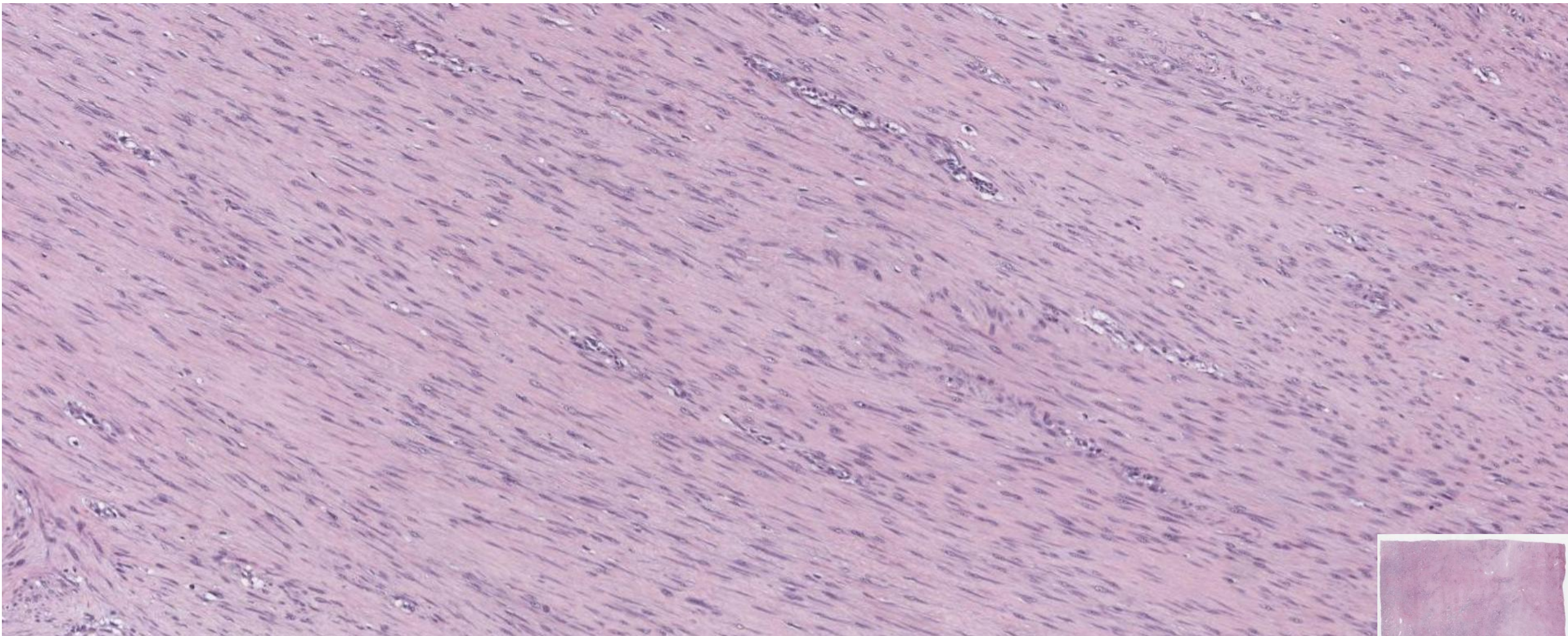


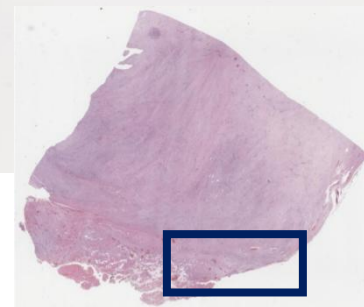
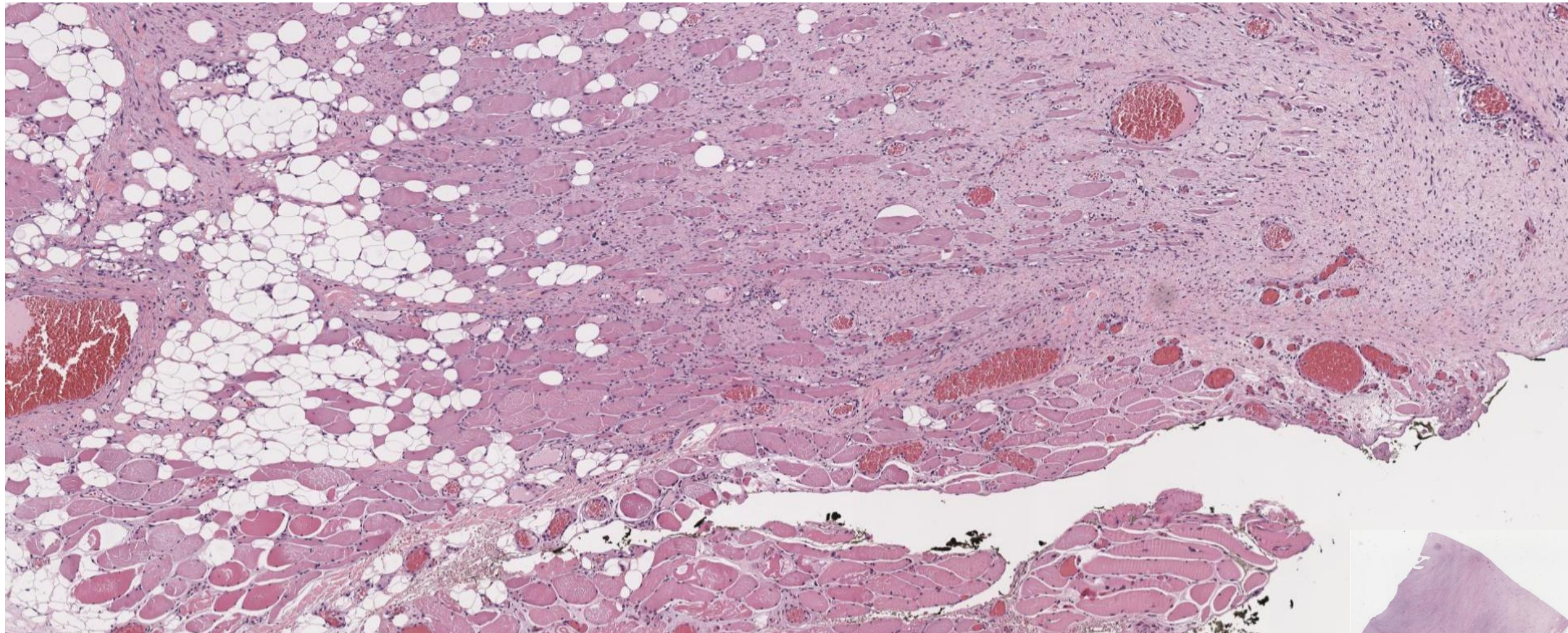


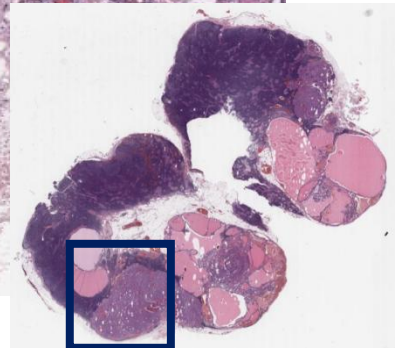
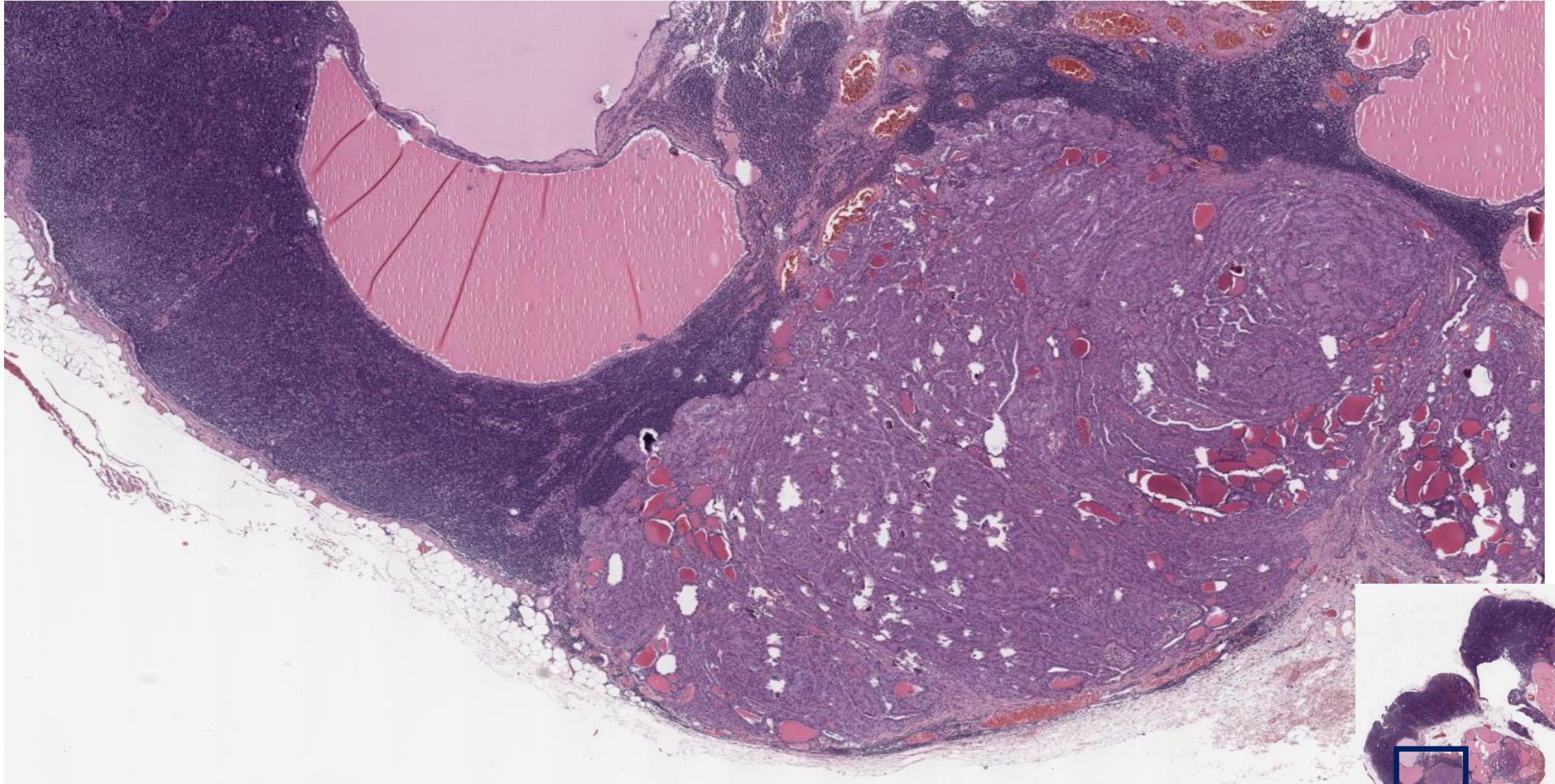


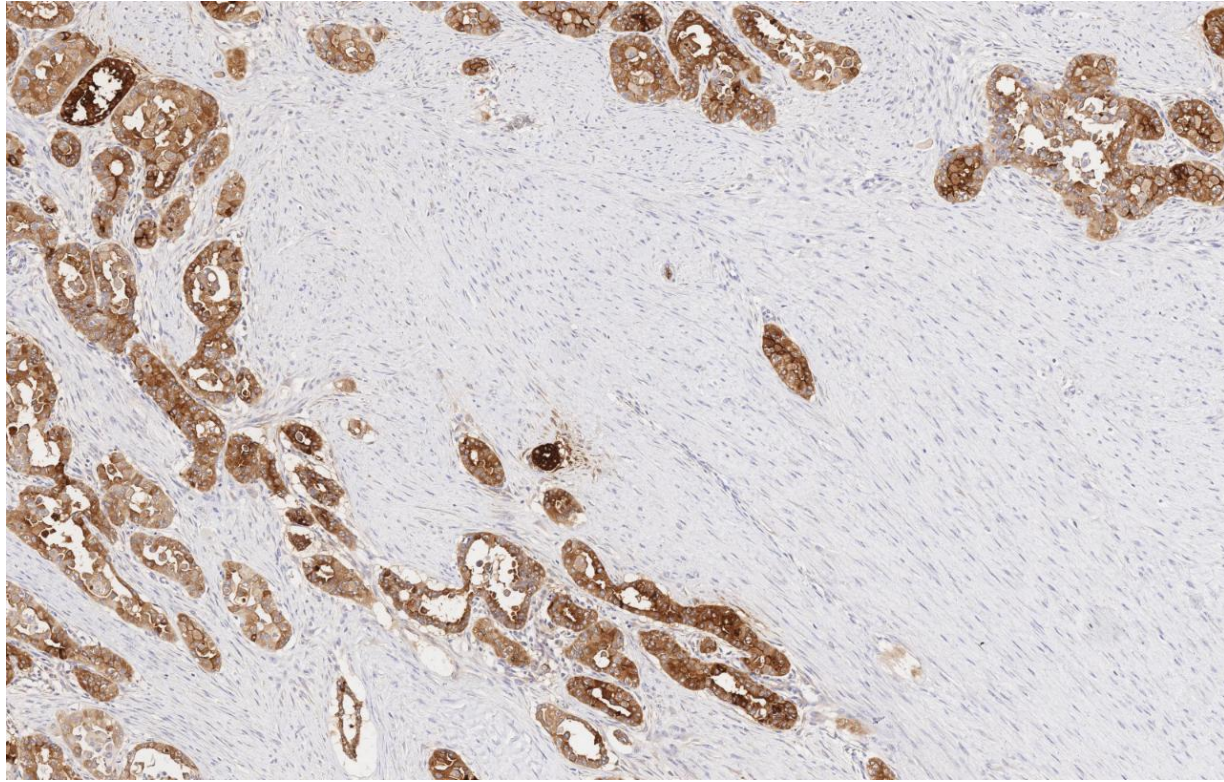


HALLAZGOS MICROSCÓPICOS

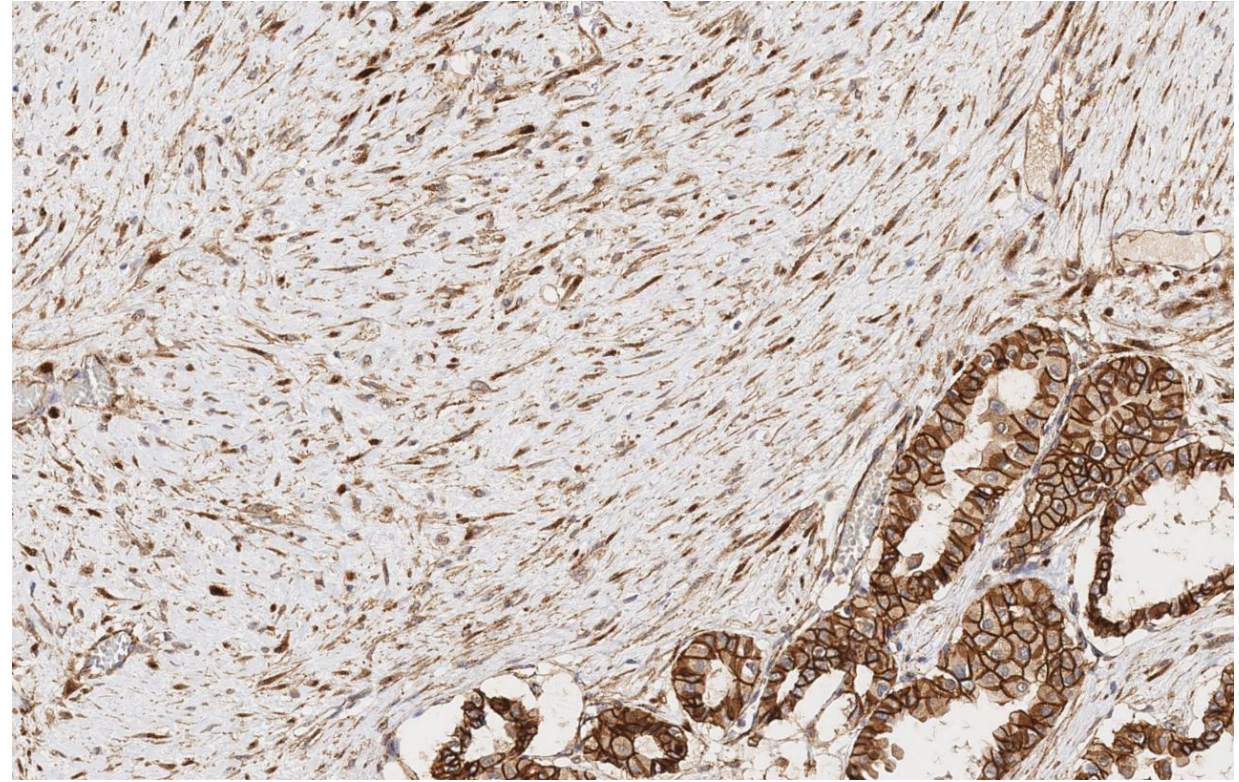






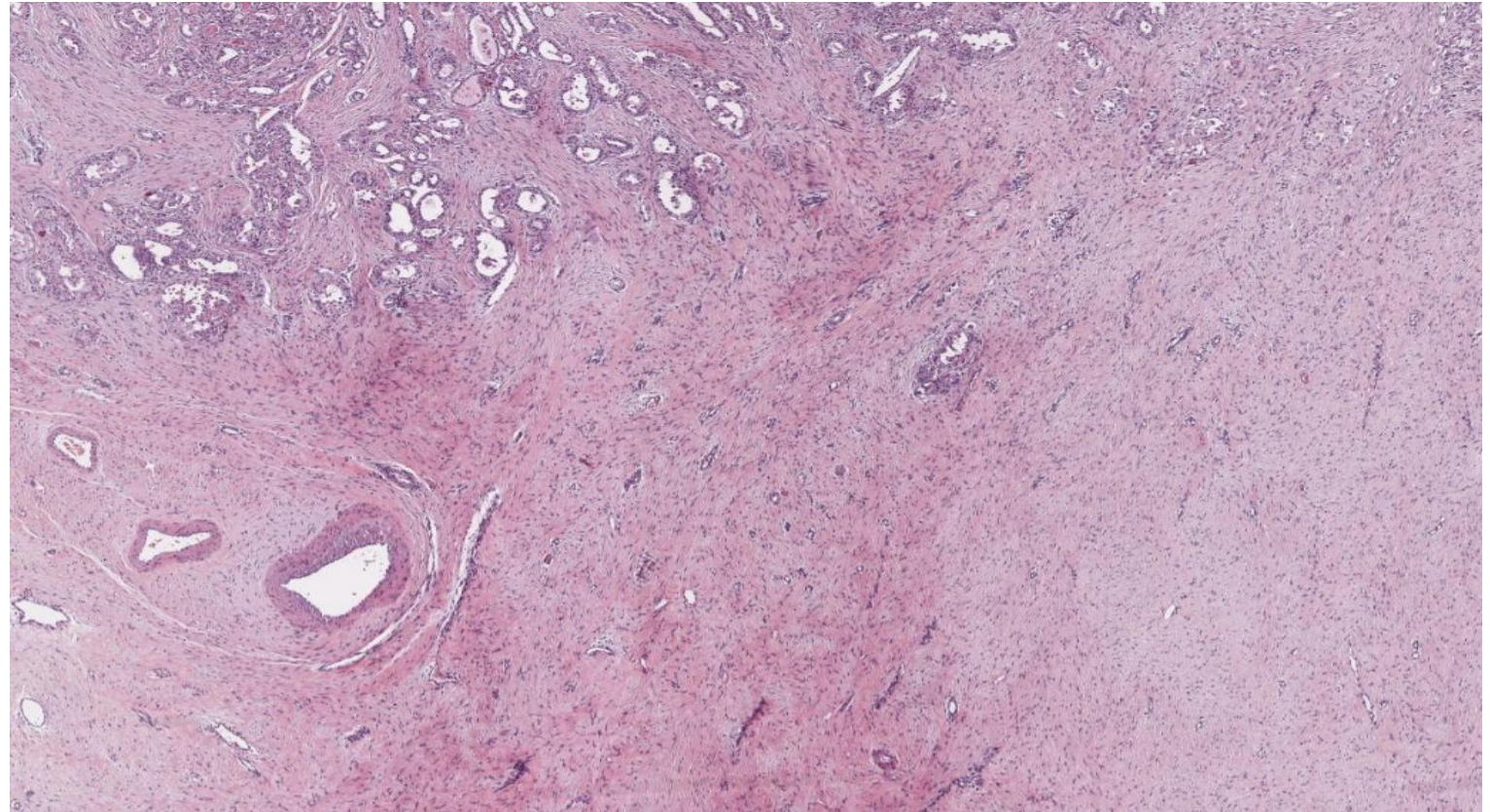


Tiroglobulina



Beta Catenina

Carcinoma papilar de tiroides con fibromatosis/*fascitis-like*/estroma tipo desmoide con metástasis ganglionar



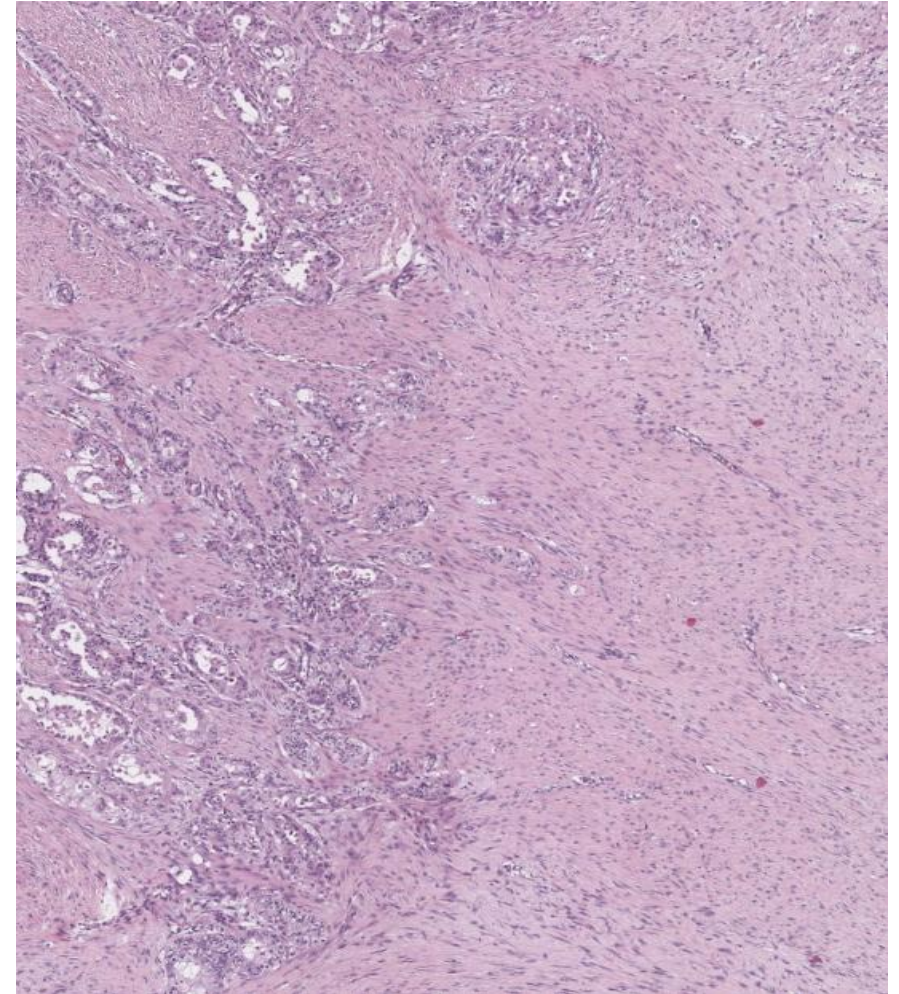
INFORME SECUENCIACIÓN MASIVA (NGS)

RESULTADOS:

- Variantes de potencial utilidad clínica (patogénicas):

-Gen: *BRAF*_Posición:Chr7: 140453136_Profundidad:130_VAF: 16.9 % _ RefSeq
Transcript: NM_004333.4_Exón: 15/18_cHgvs: c.1799T>A_pHgvs: p.Val600Glu

-Gen: *CTNNB1*_Posición:Chr3: 41266136_Profundidad:157_VAF: 5.7 % _ RefSeq
Transcript: NM_001904.3_Exón: 3/15_cHgvs: c.133T>C_pHgvs: p.Ser45Pro



WHO Classification of Tumours • 5th Edition

Endocrine Tumours

Edited by the WHO Classification of Tumours Editorial Board

Review > BMC Endocr Disord. 2023 Apr 14;23(1):80. doi: 10.1186/s12902-023-01337-y.

Papillary thyroid carcinoma with fibromatosis-like stroma: a case report and review of the literature

Antonio Toniato ¹, Marco Brusoni ², Marica Mirabella ², Luca Pomba ², Vasileios Mourmouras ³, Antonio Scapinello ³, Enrico Battistella ²

Affiliations + expand

PMID: 37060011 PMCID: PMC10103504 DOI: 10.1186/s12902-023-01337-y

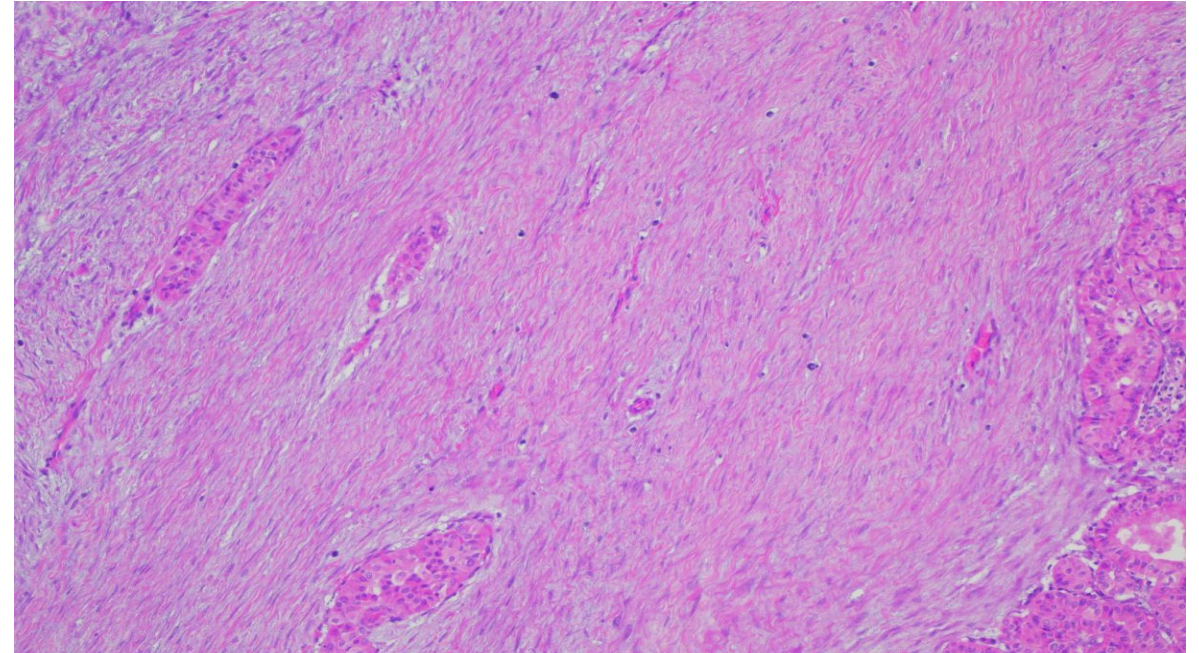
Review > Cancers (Basel). 2021 Sep 6;13(17):4482. doi: 10.3390/cancers13174482.

Papillary Thyroid Carcinoma with Desmoid-Type Fibromatosis: Review of Published Cases

Abdallah Roukain ¹, Stefano La Rosa ², Massimo Bongiovanni ³, Marie Nicod Lalonde ⁴, Valérie Cristina ⁵, Michael Montemurro ⁵, Stephane Cochet ⁶, Alexandra Luquain ⁷, Peter A Kopp ¹, Gerasimos P Sykiotis ¹

Affiliations + expand

PMID: 34503292 PMCID: PMC8430917 DOI: 10.3390/cancers13174482





GRACIAS