



118^a Reunión de la Territorial Valenciana de la SEAP

15 de diciembre de 2023 en el Consorci Hospital General Universitari de Valencia.
Salón de actos: Edificio de Ciencias de la Salud (junto a la cafetería).
Avda Tres Cruces, 2. Valencia

Alberto Guillén Mollá (R4)
Hospital General Universitario de Elche

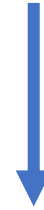ANTECEDENTES PERSONALES

- ❖ Mujer de 50 años, procedente de Colombia.
- ❖ Hábitos tóxicos: No fumadora. No hábito etílico.
- ❖ RAMc: Paracetamol.
- ❖ Antecedentes quirúrgicos: **parotidectomía parcial izquierda en Colombia (No remite informe: “CARCINOMA”)**. Controles posteriores en Colombia con técnicas de imagen negativos.
- ❖ Tratamientos: Eutirox





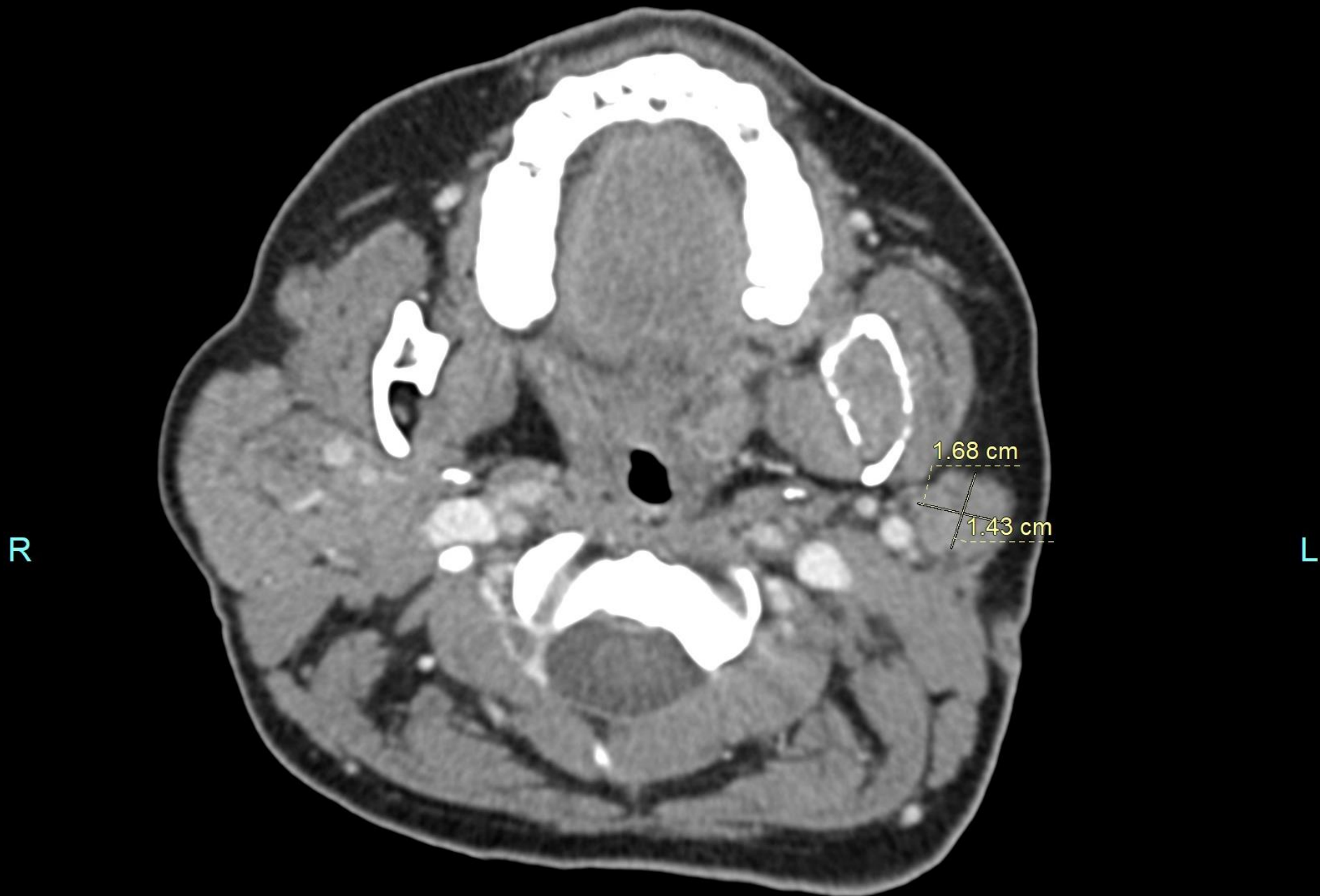
MÉDICO ATENCIÓN PRIMARIA



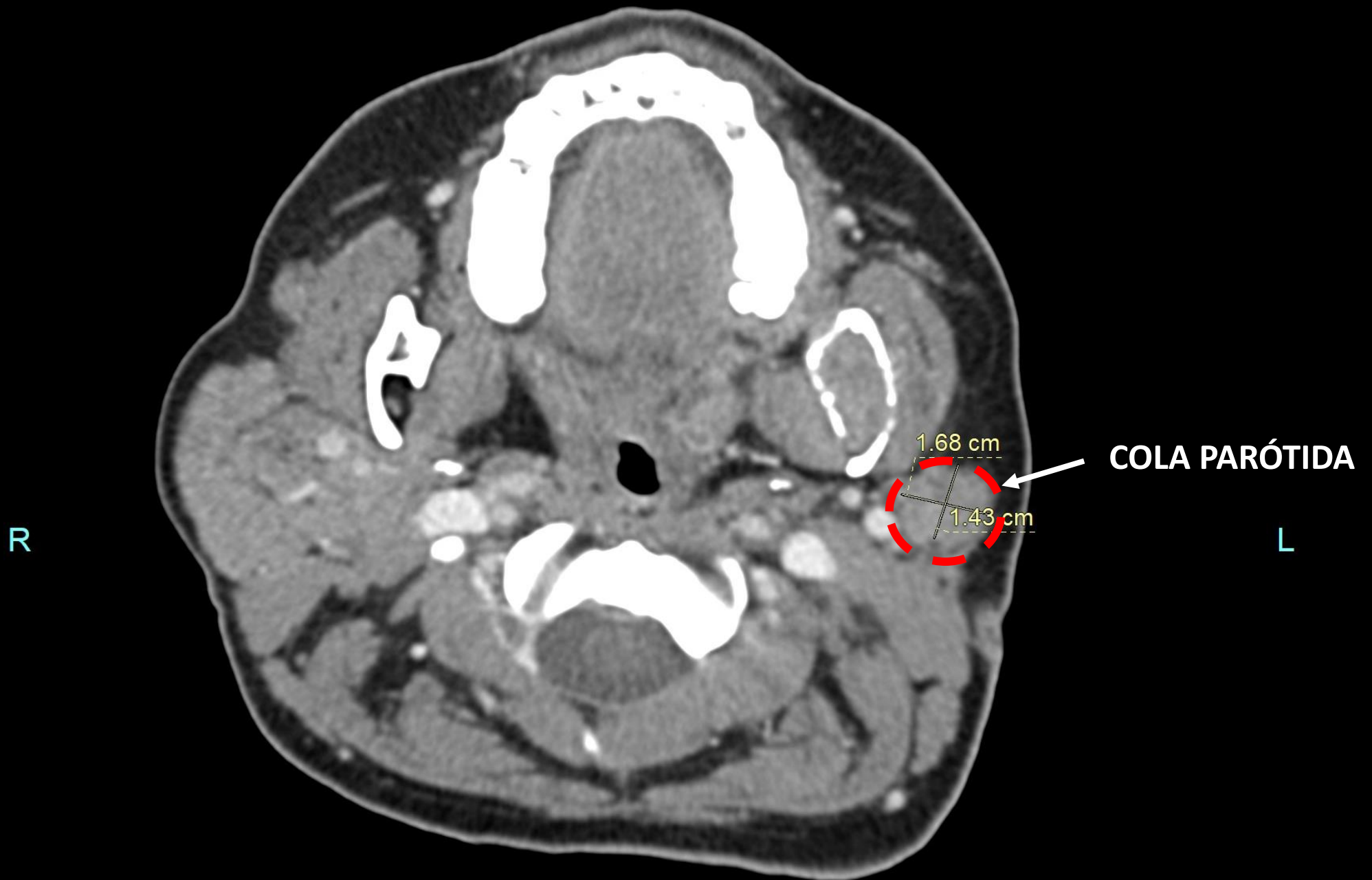
ORL

Seguimiento y control

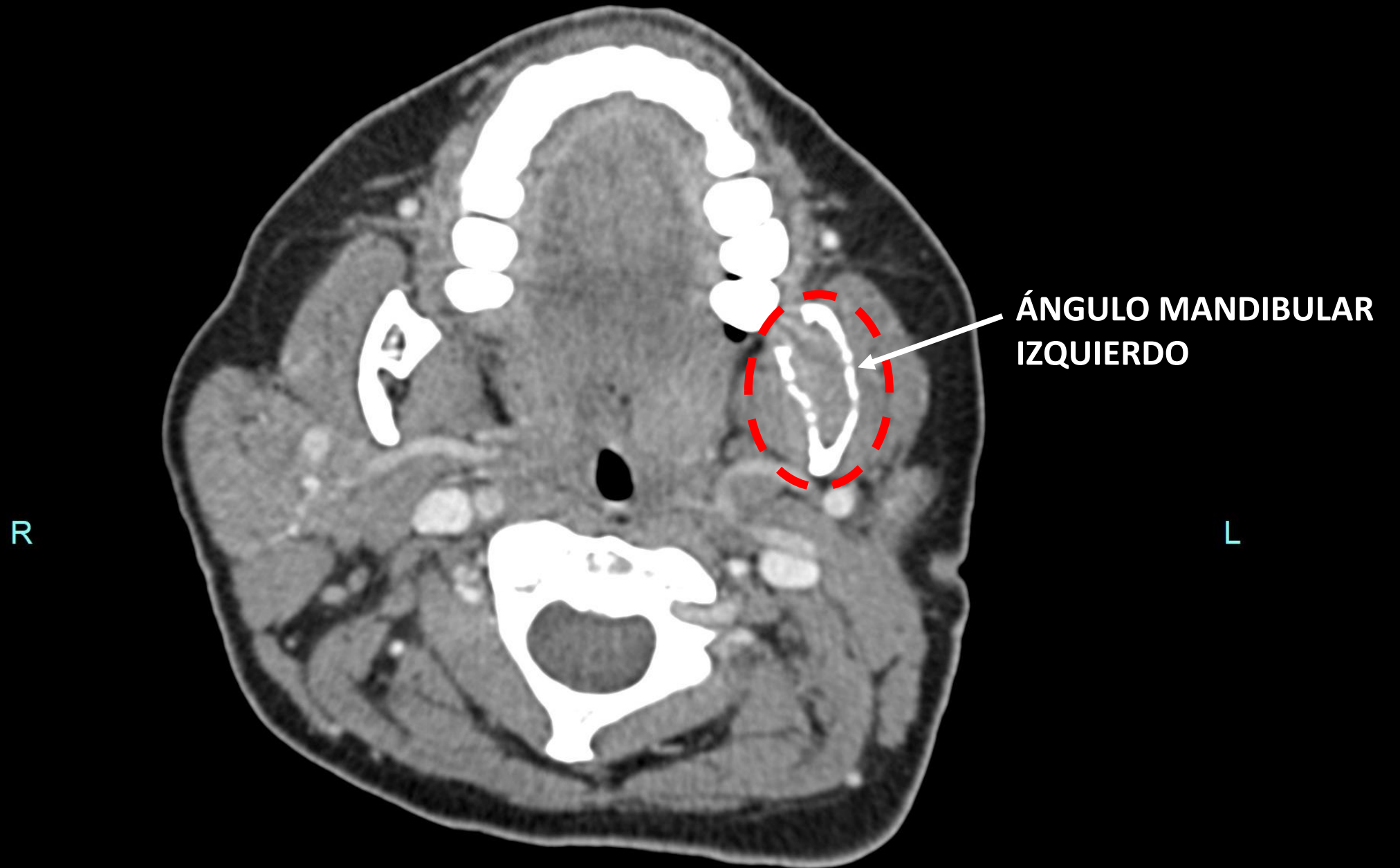
EXPLORACIONES COMPLEMENTARIAS: TC CUELLO



EXPLORACIONES COMPLEMENTARIAS: TC CUELLO

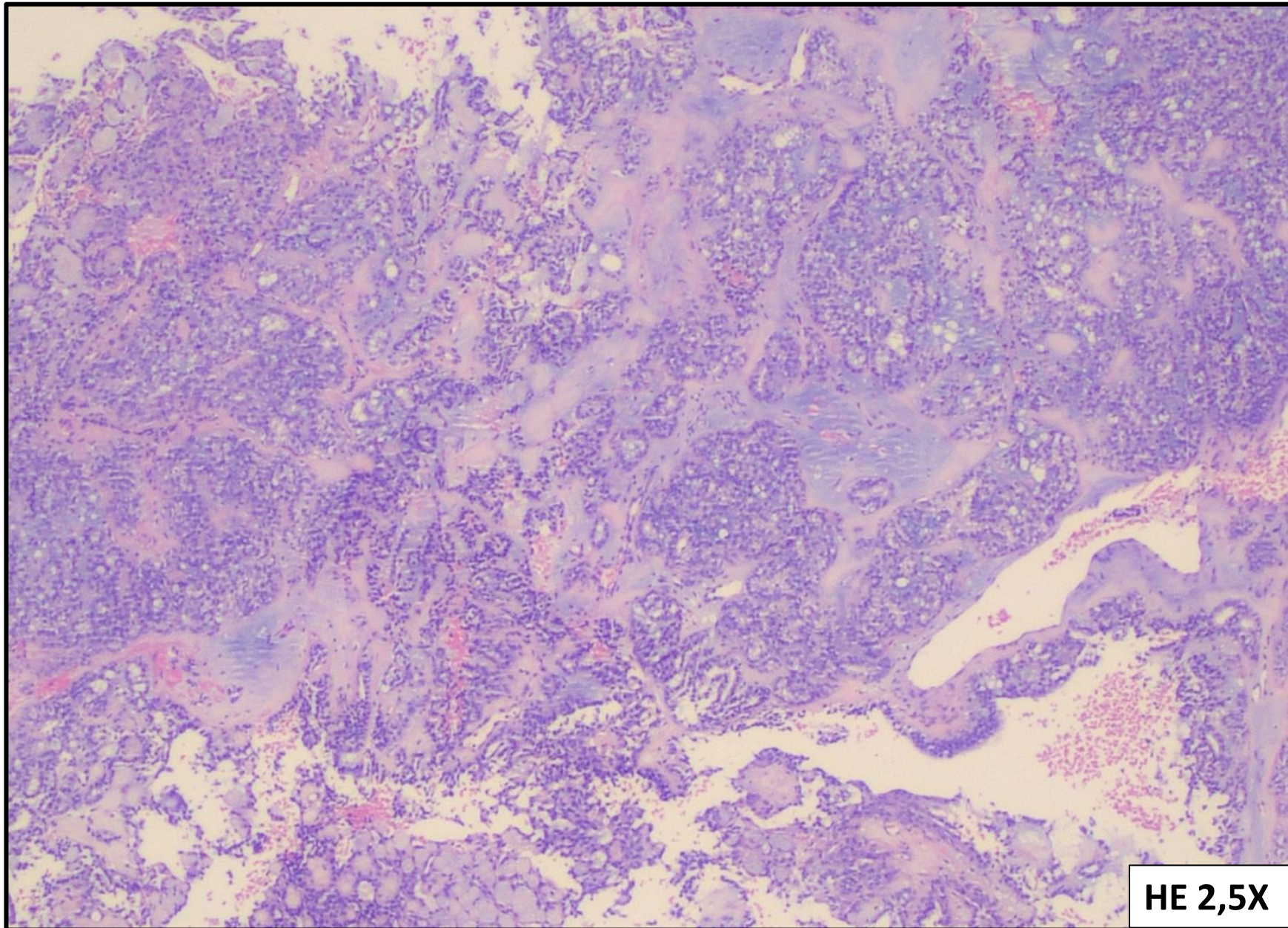


EXPLORACIONES COMPLEMENTARIAS: TC CUELLO

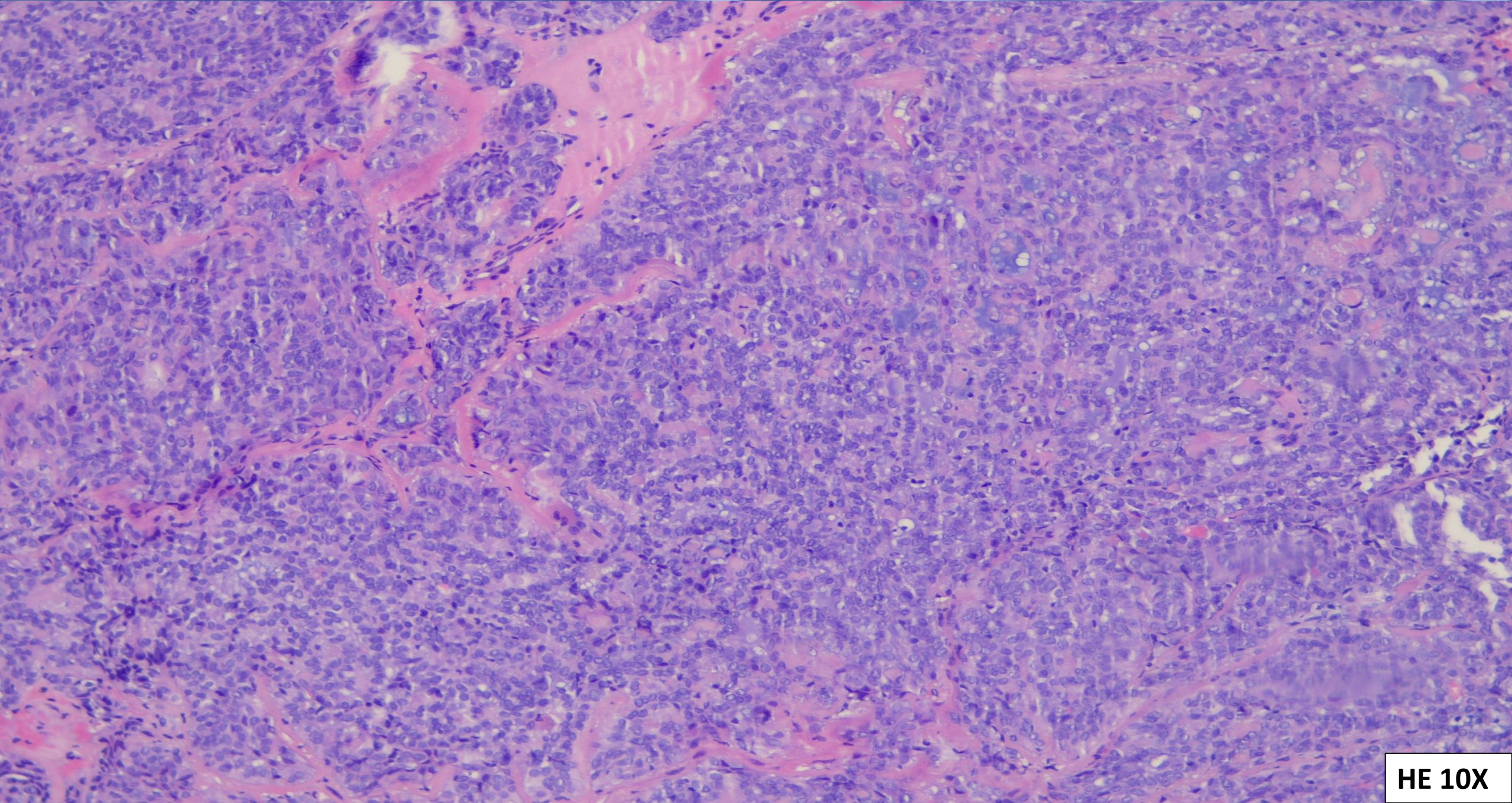


BIOPSIA DE LESIÓN ÁNGULO MANDIBULAR IZQUIERDA

Macroscopia: Múltiples fragmentos irregulares pardo-grisáceos que agrupados miden 2 x 2 cm.



PATRONES ARQUITECTURALES

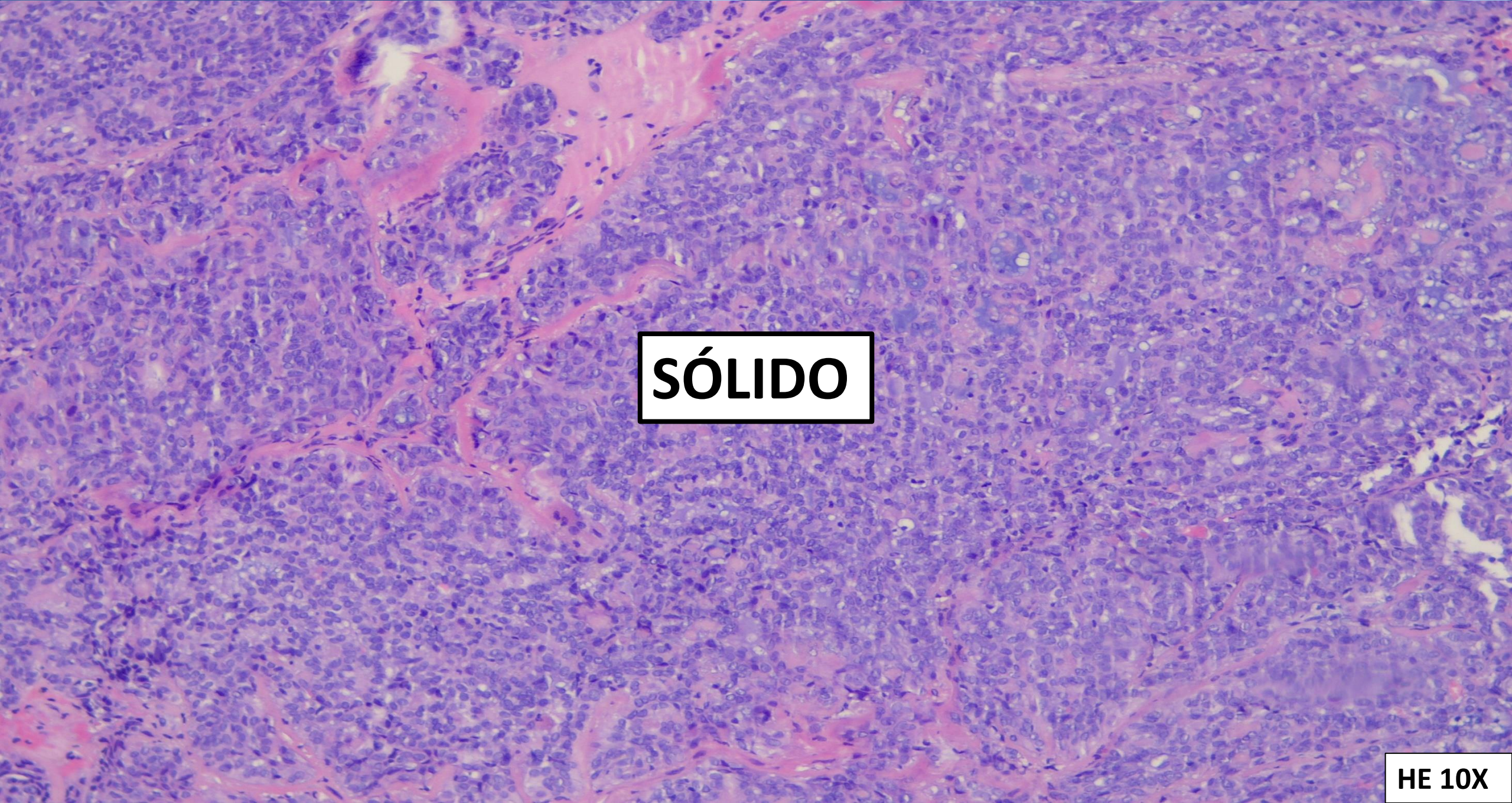


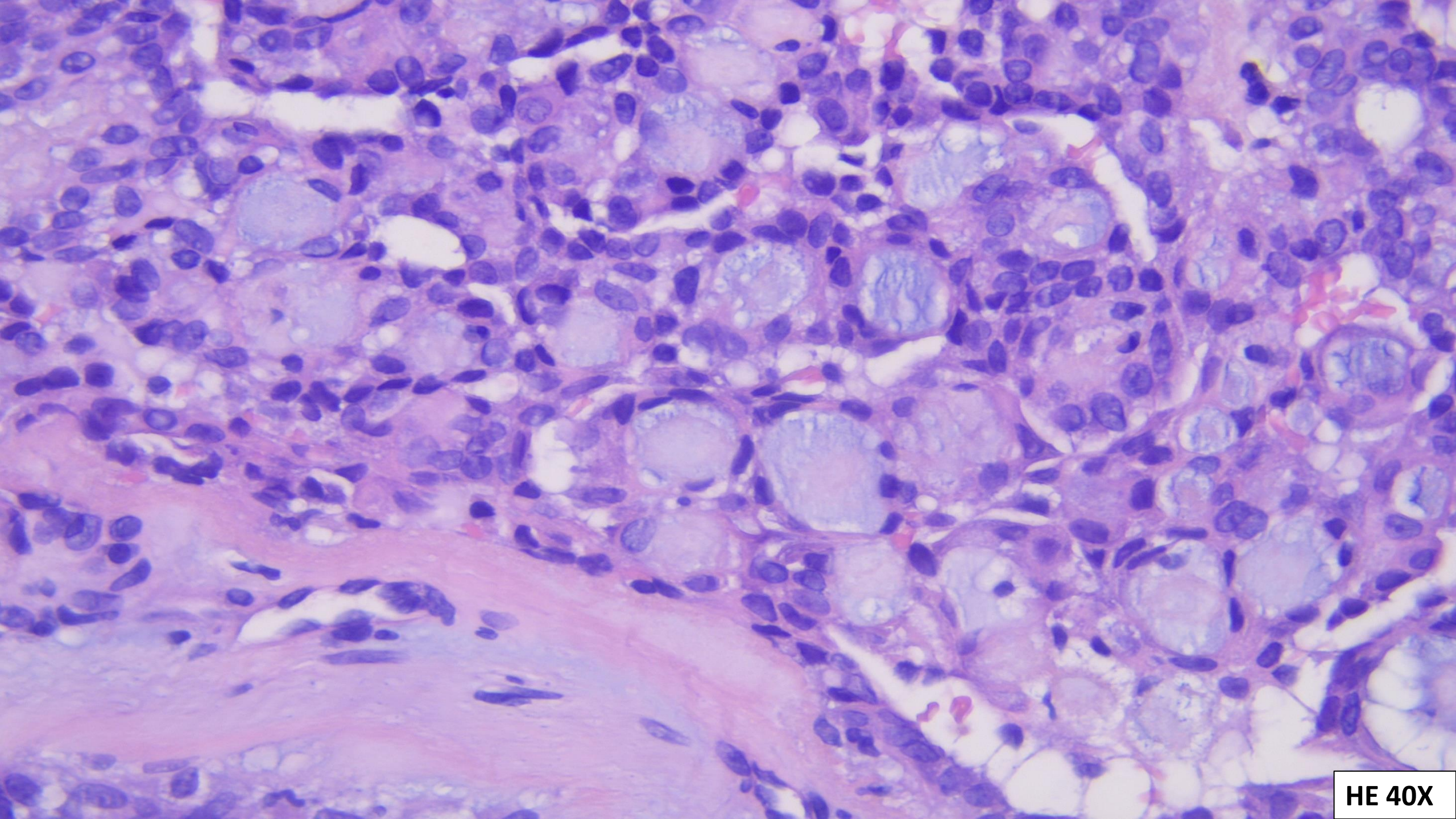
HE 10X

PATRONES ARQUITECTURALES

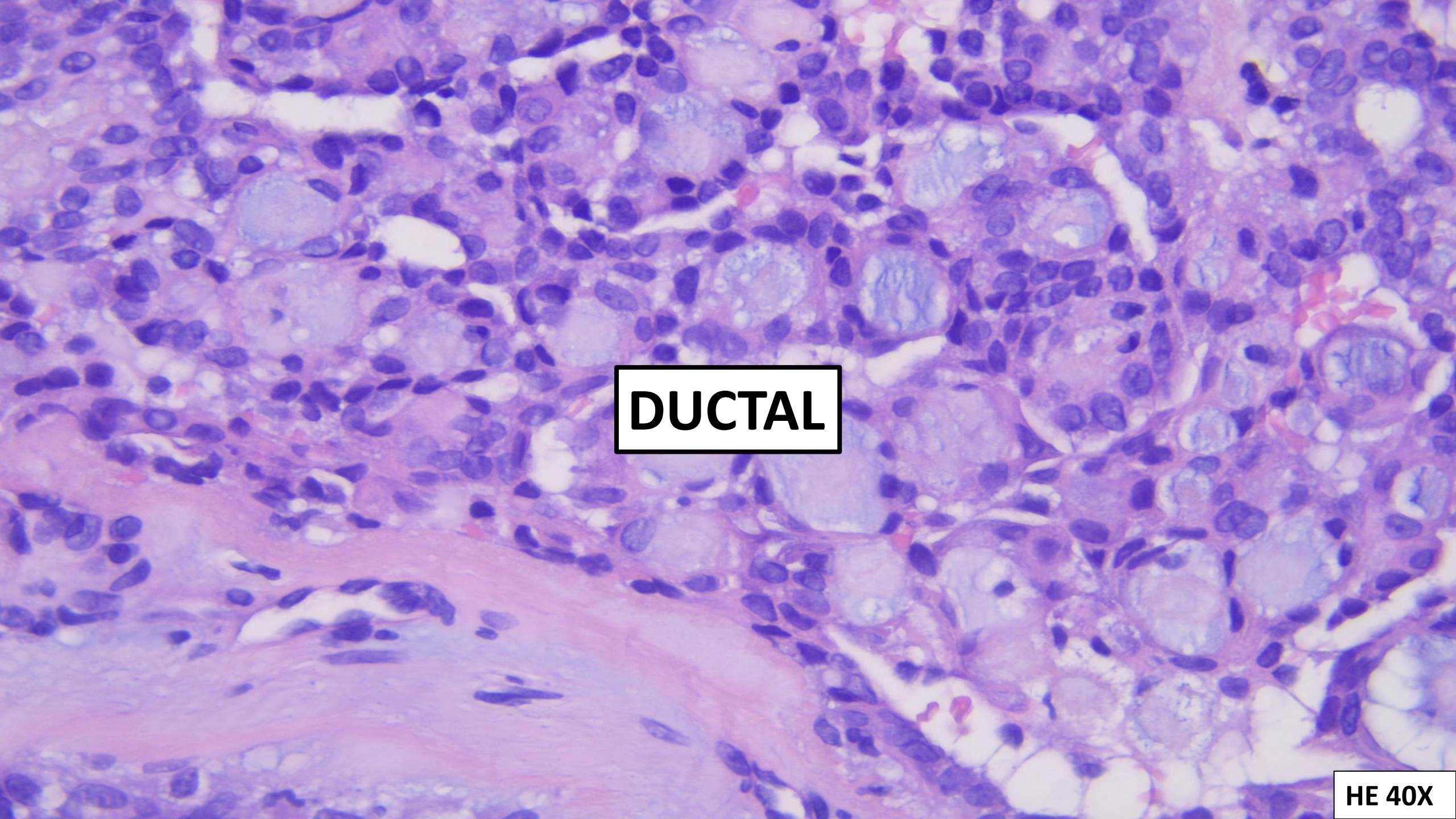
SÓLIDO

HE 10X

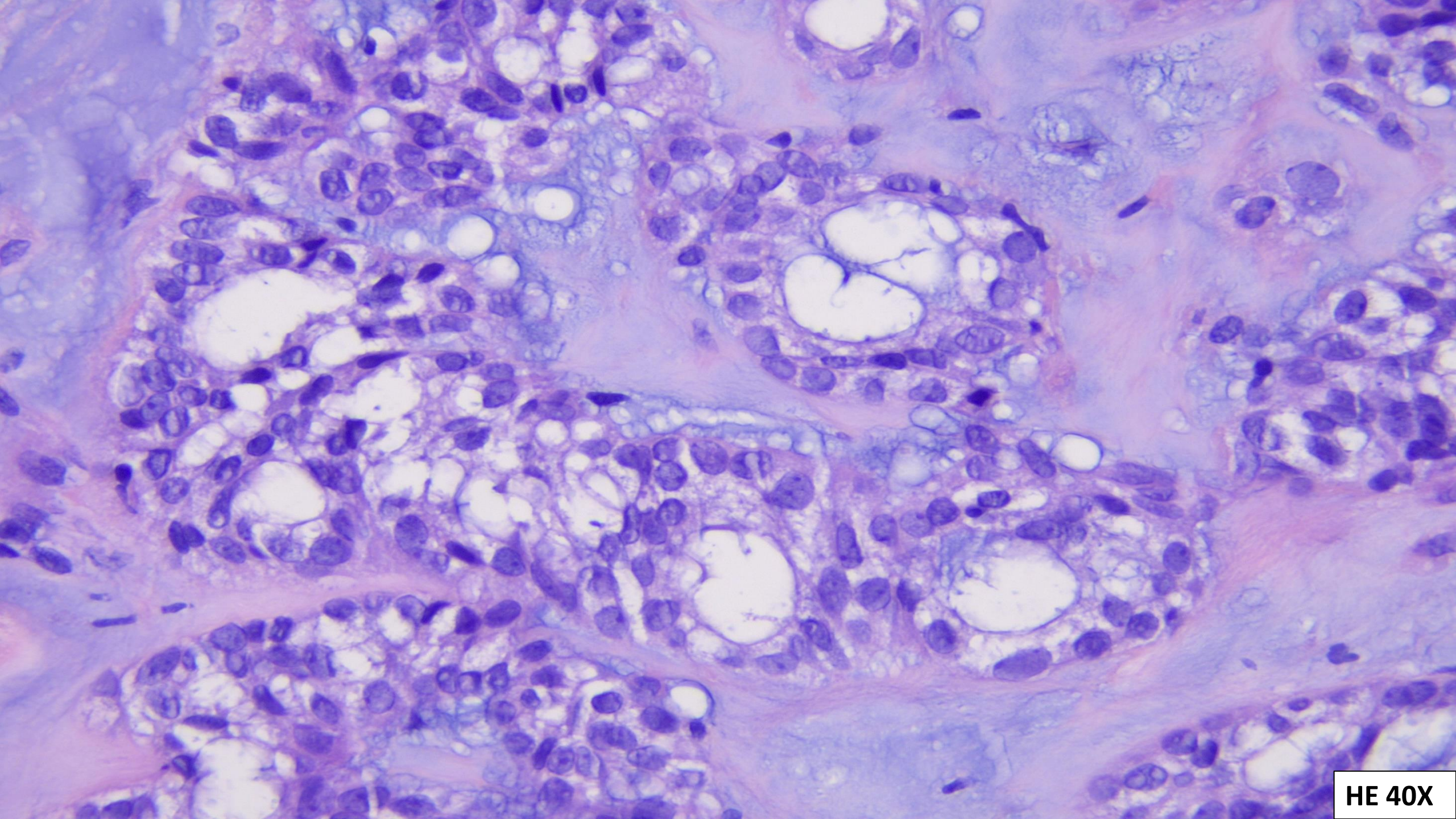




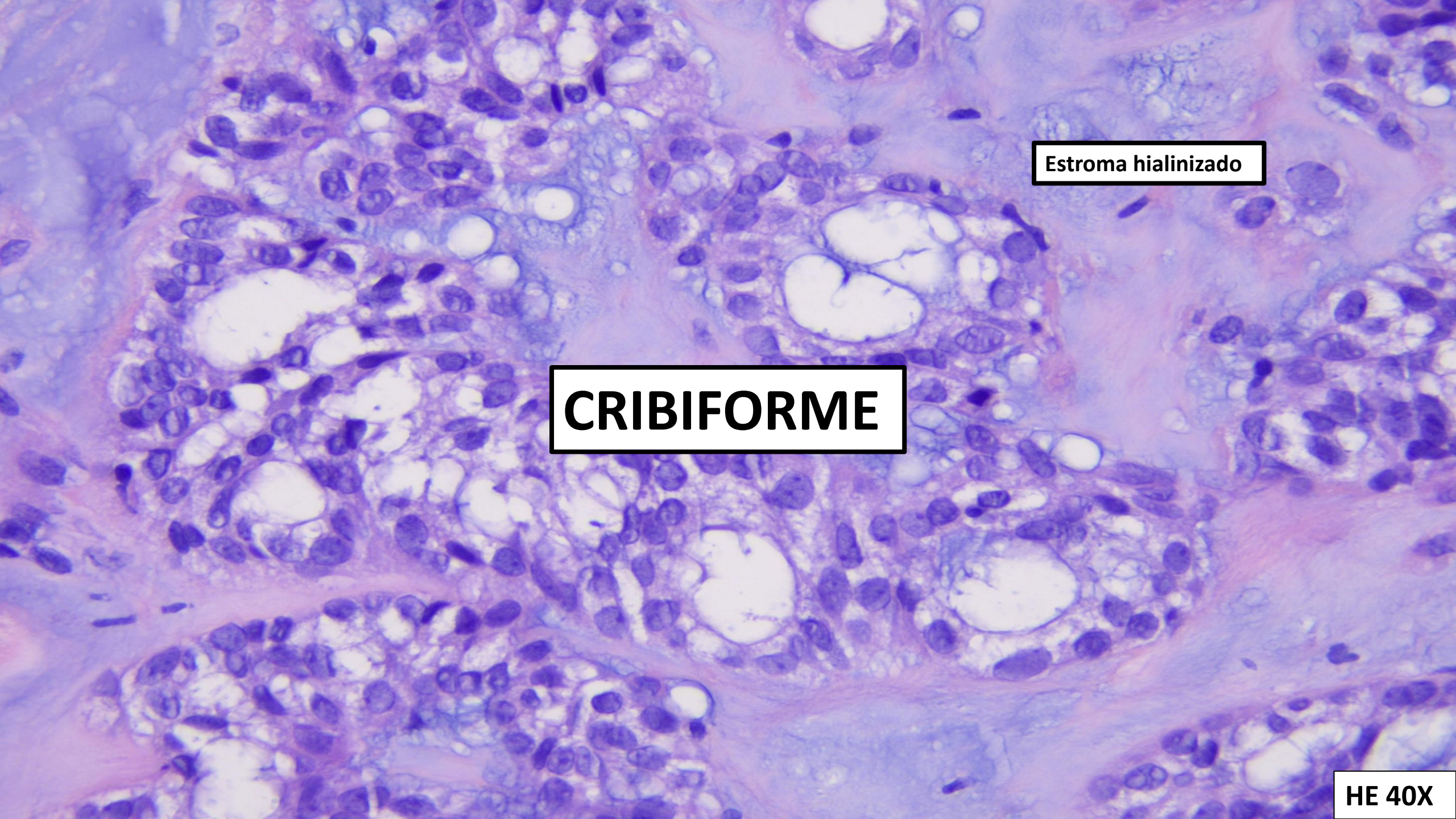
HE 40X



DUCTAL



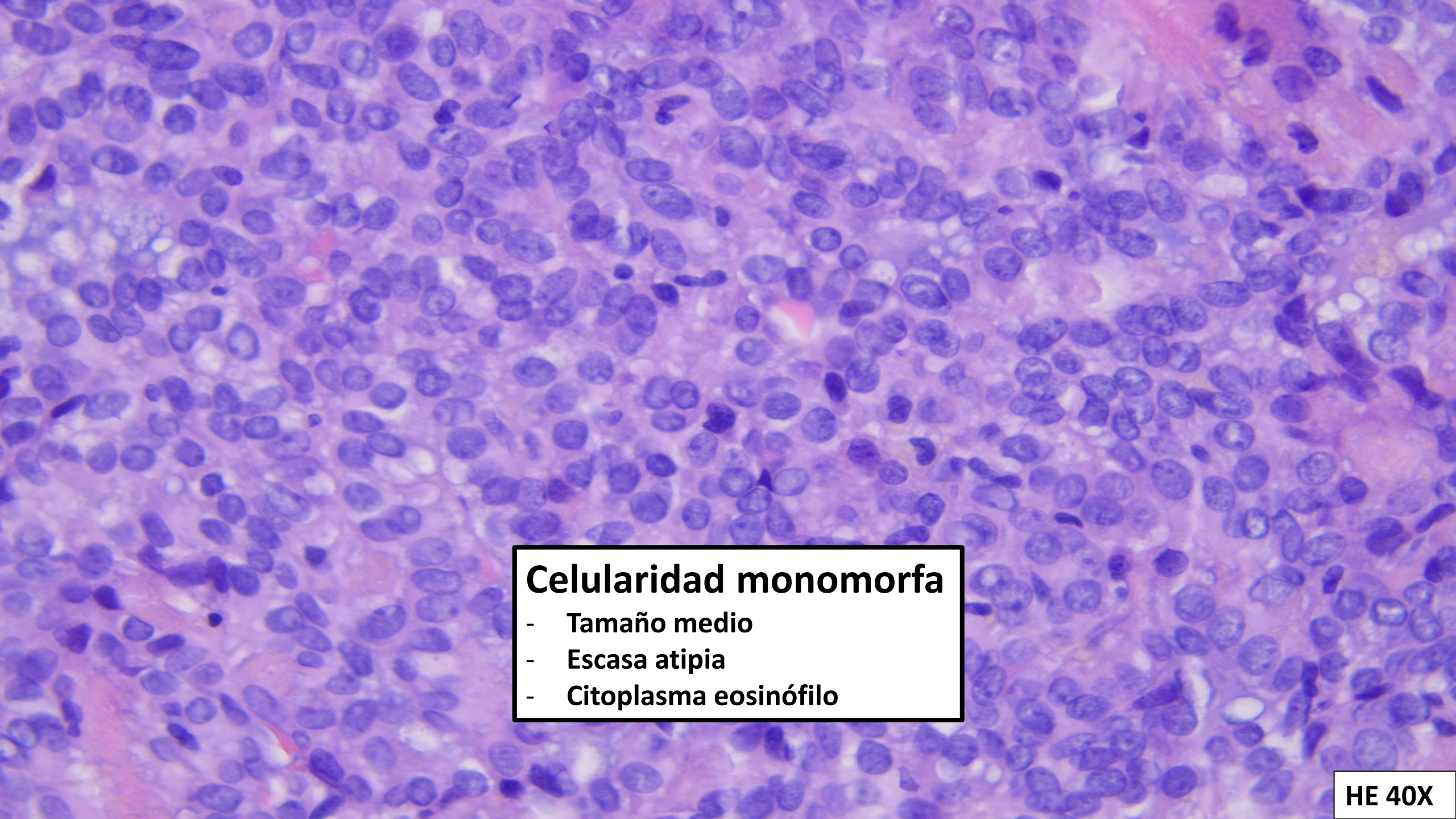
HE 40X



Estroma hialinizado

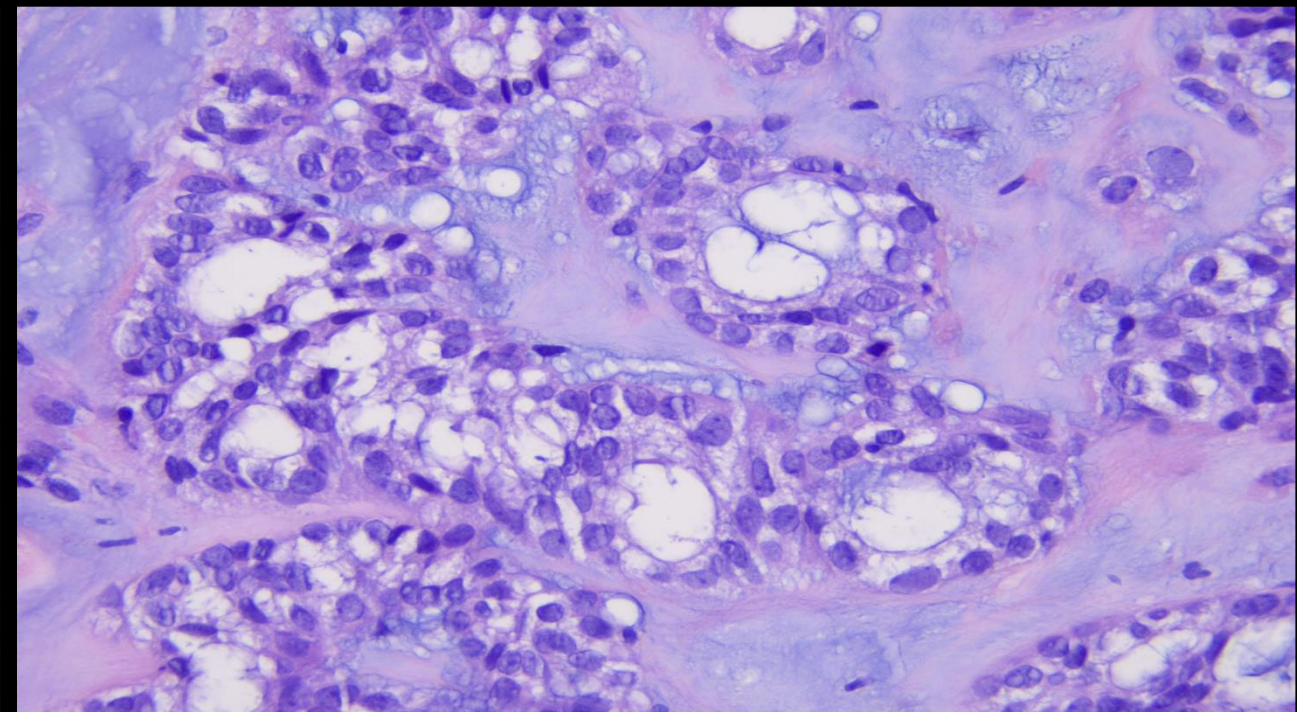
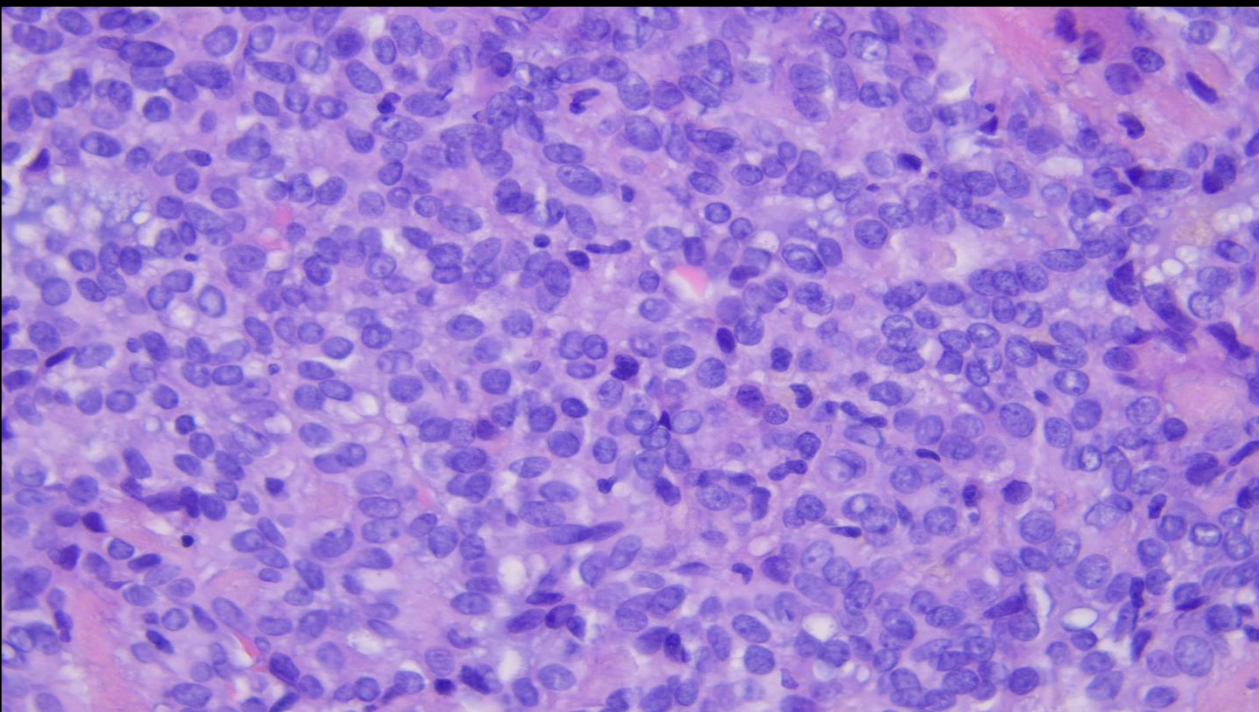
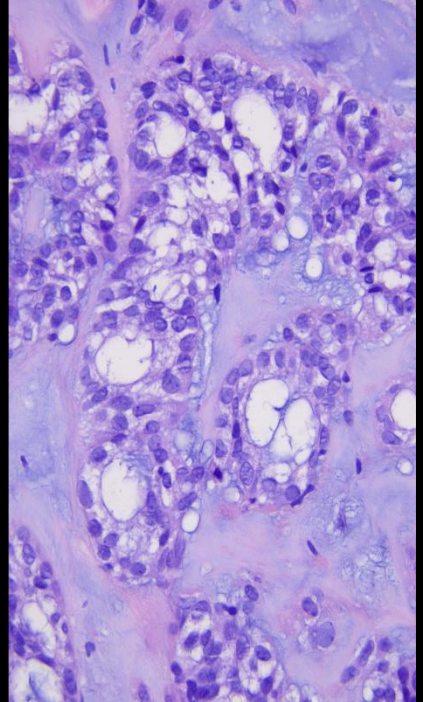
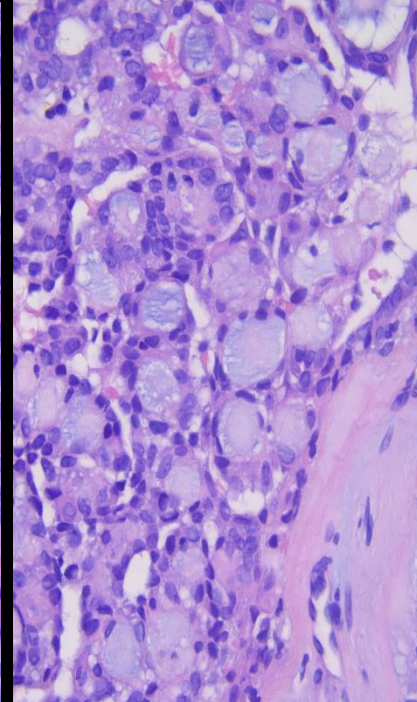
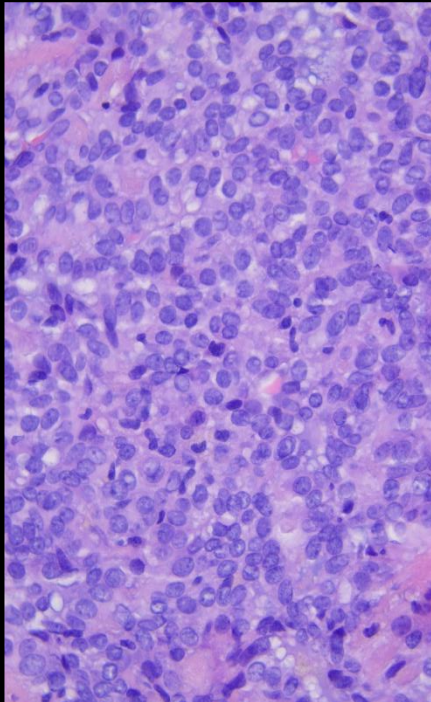
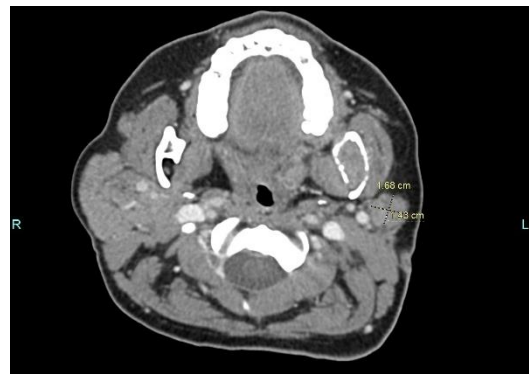
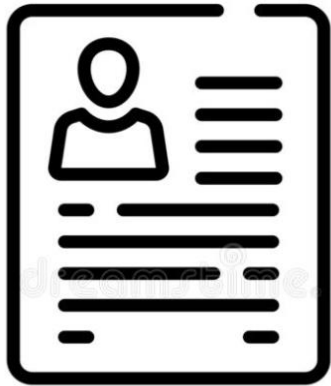
CRIBIFORME

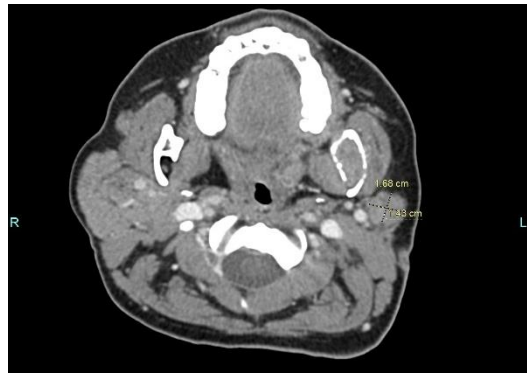
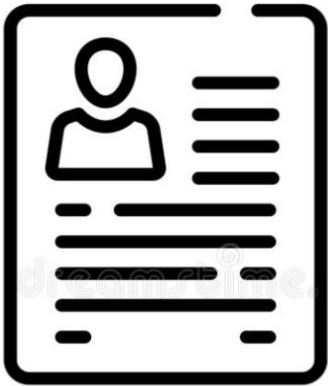
HE 40X



Celularidad monomorfa

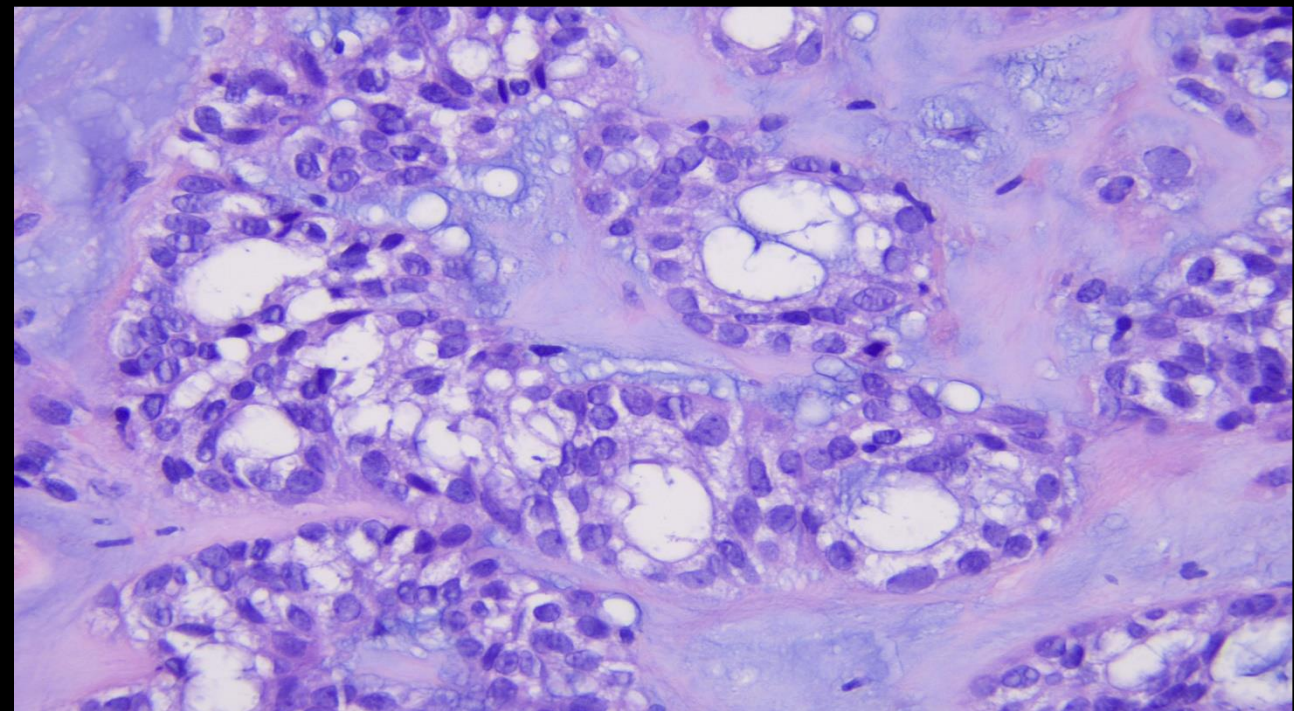
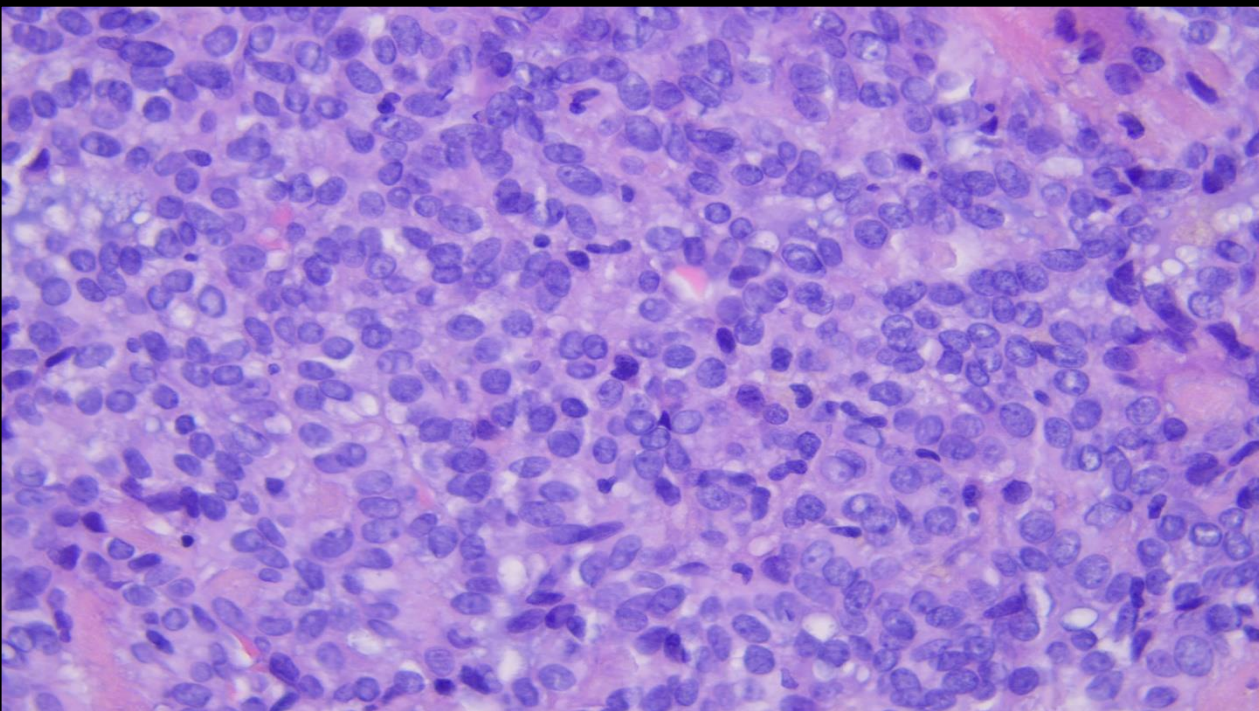
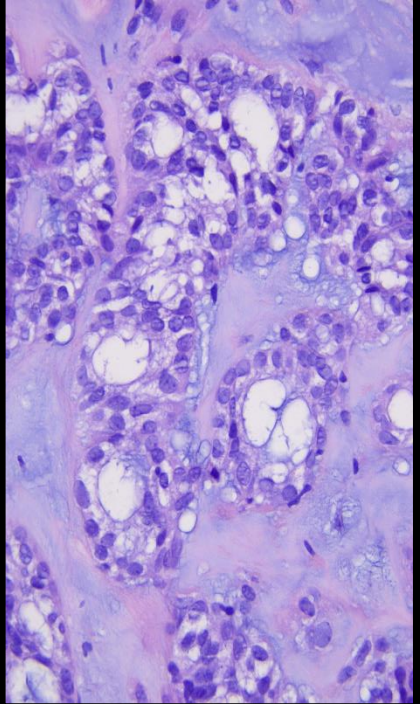
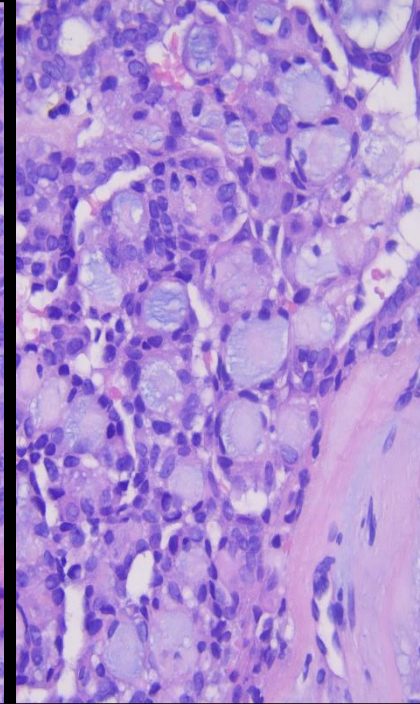
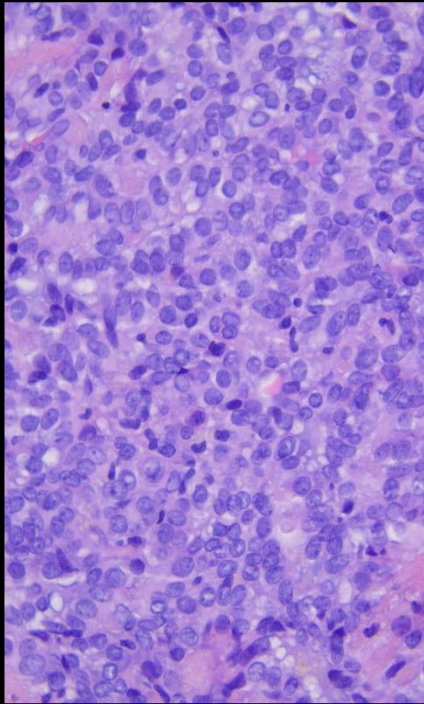
- Tamaño medio
- Escasa atipia
- Citoplasma eosinófilo

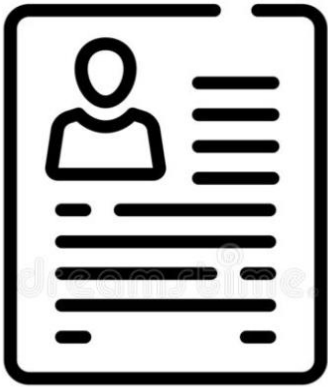




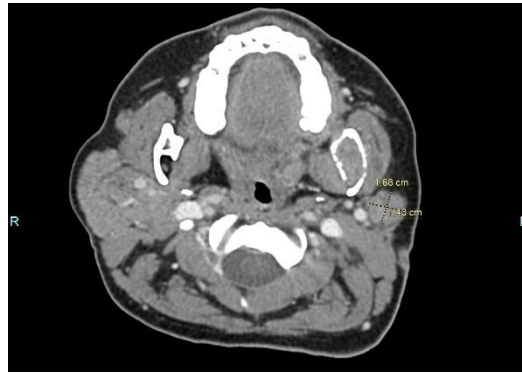
ANTECEDENTE
"CARCINOMA" EN
PAROTIDA IZQ

- LESIÓN ÁNGULO
MANDIBULAR IZQUIERDO
- LESIÓN COLA PARÓTIDA

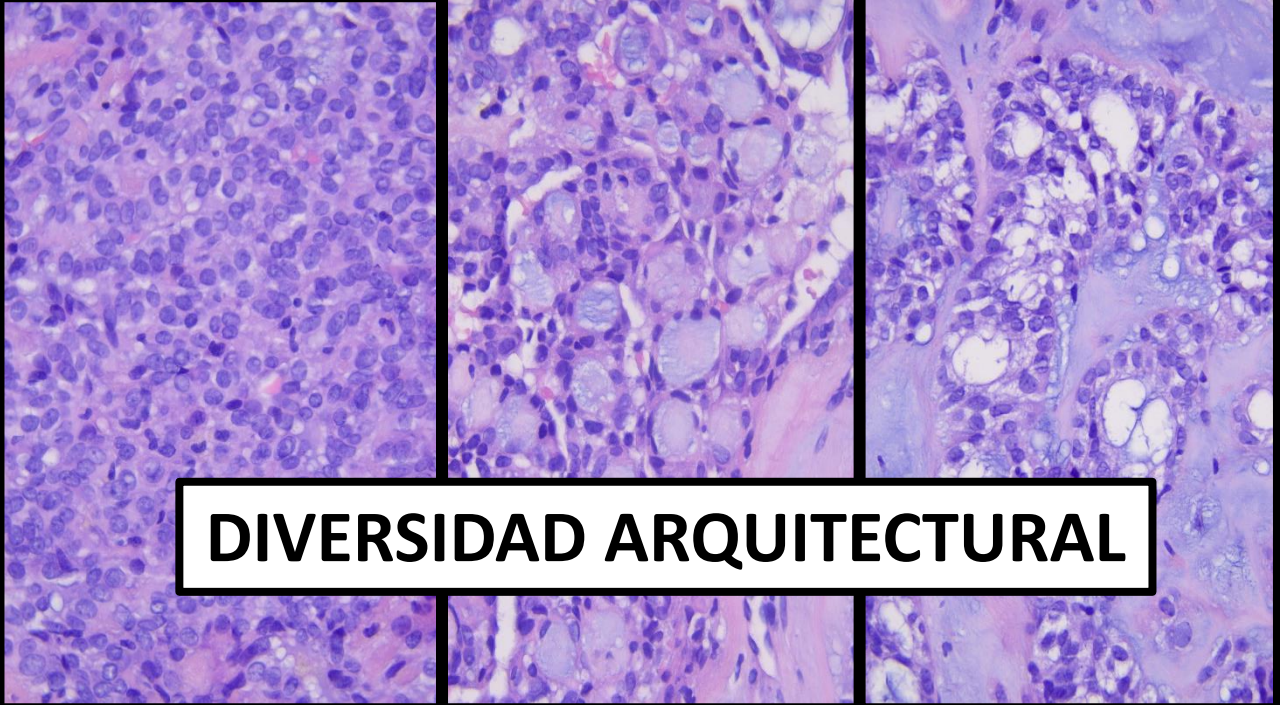




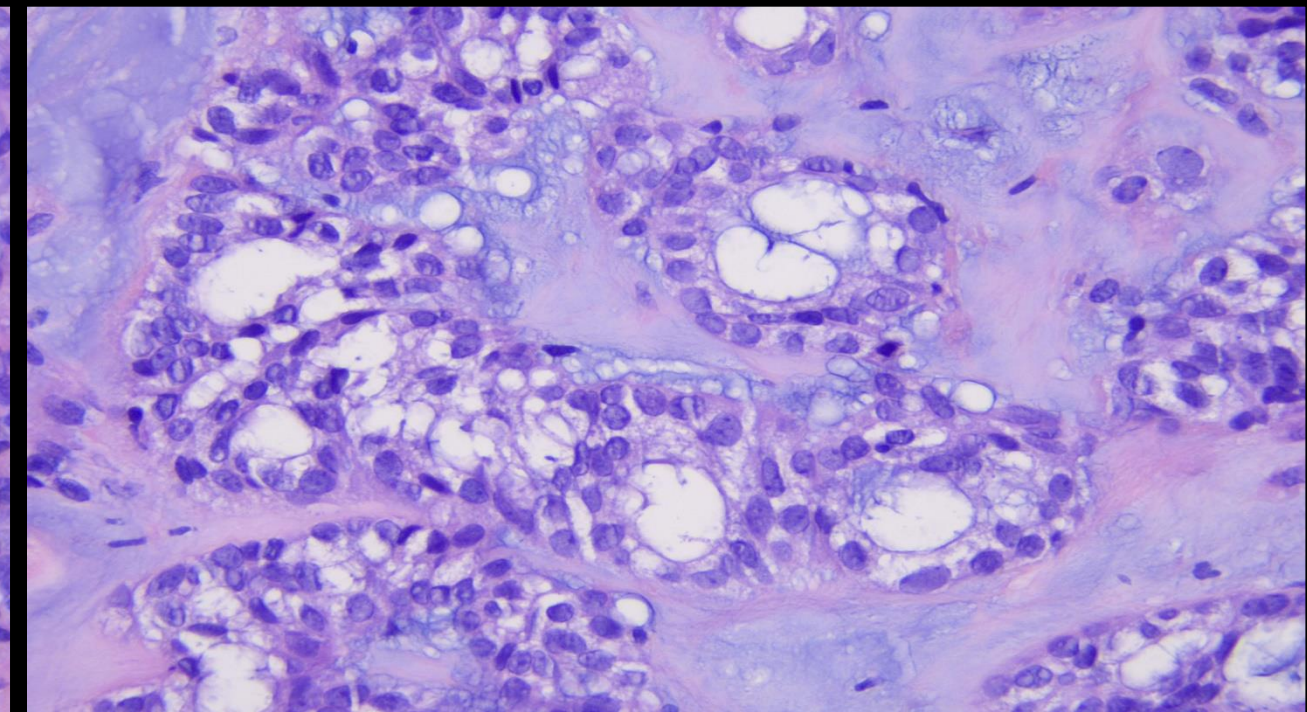
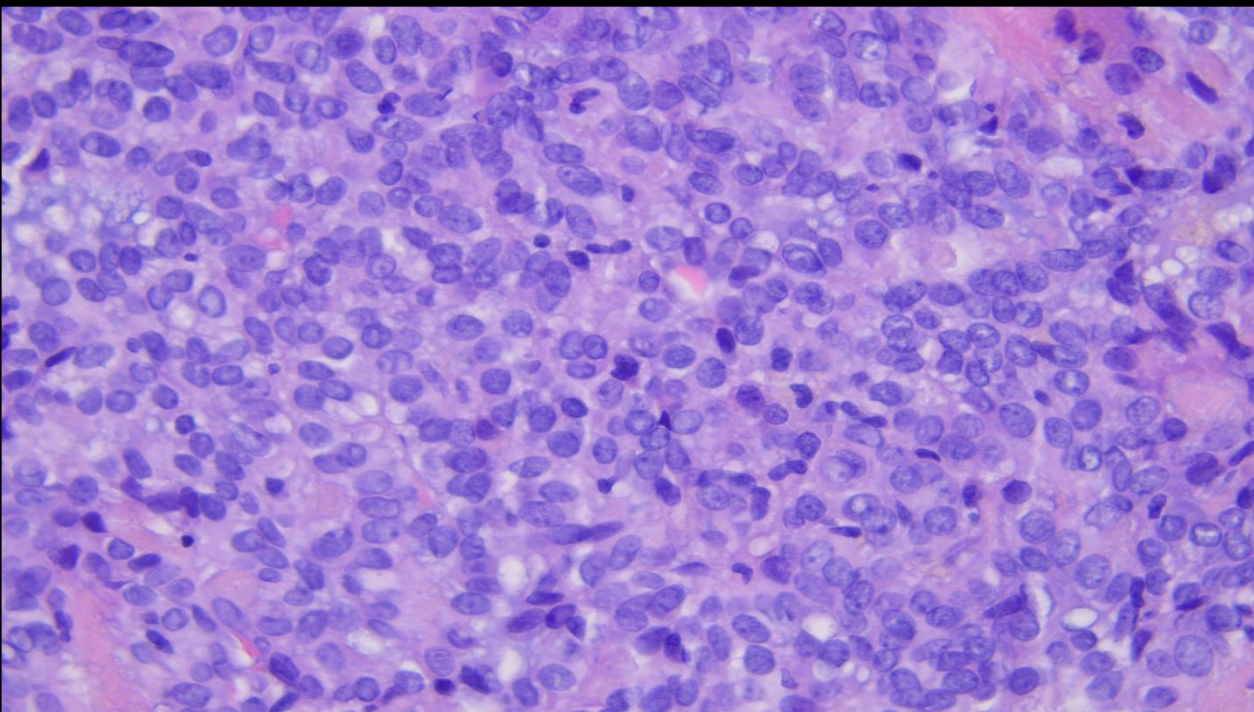
ANTECEDENTE
"CARCINOMA" EN
PAROTIDA IZQ

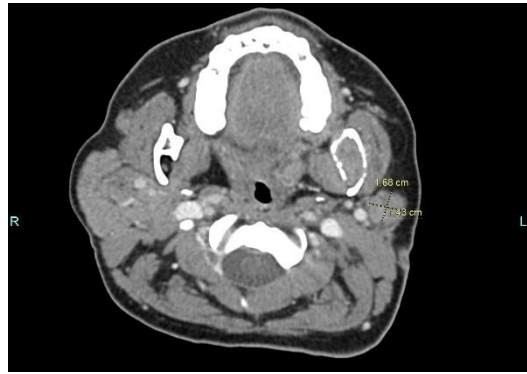


- LESIÓN ÁNGULO
MANDIBULAR IZQUIERDO
- LESIÓN COLA PARÓTIDA



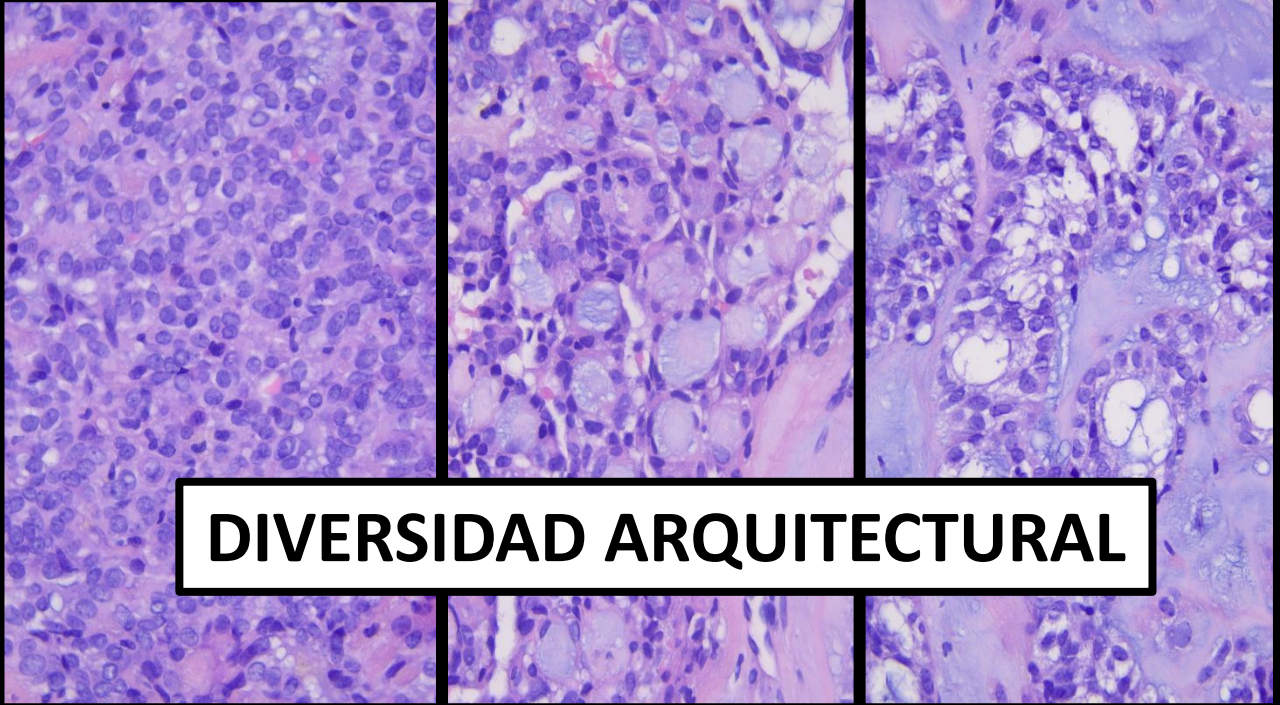
DIVERSIDAD ARQUITECTURAL



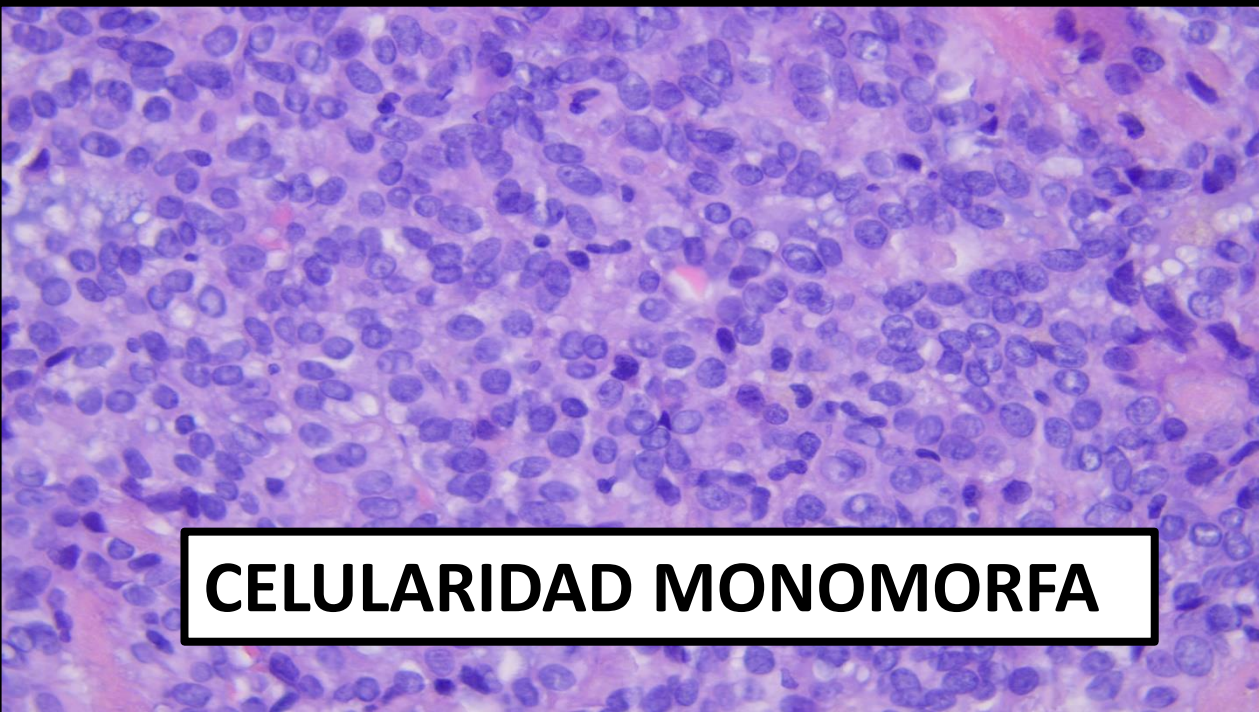

ANTECEDENTE
"CARCINOMA" EN
PAROTIDA IZQ

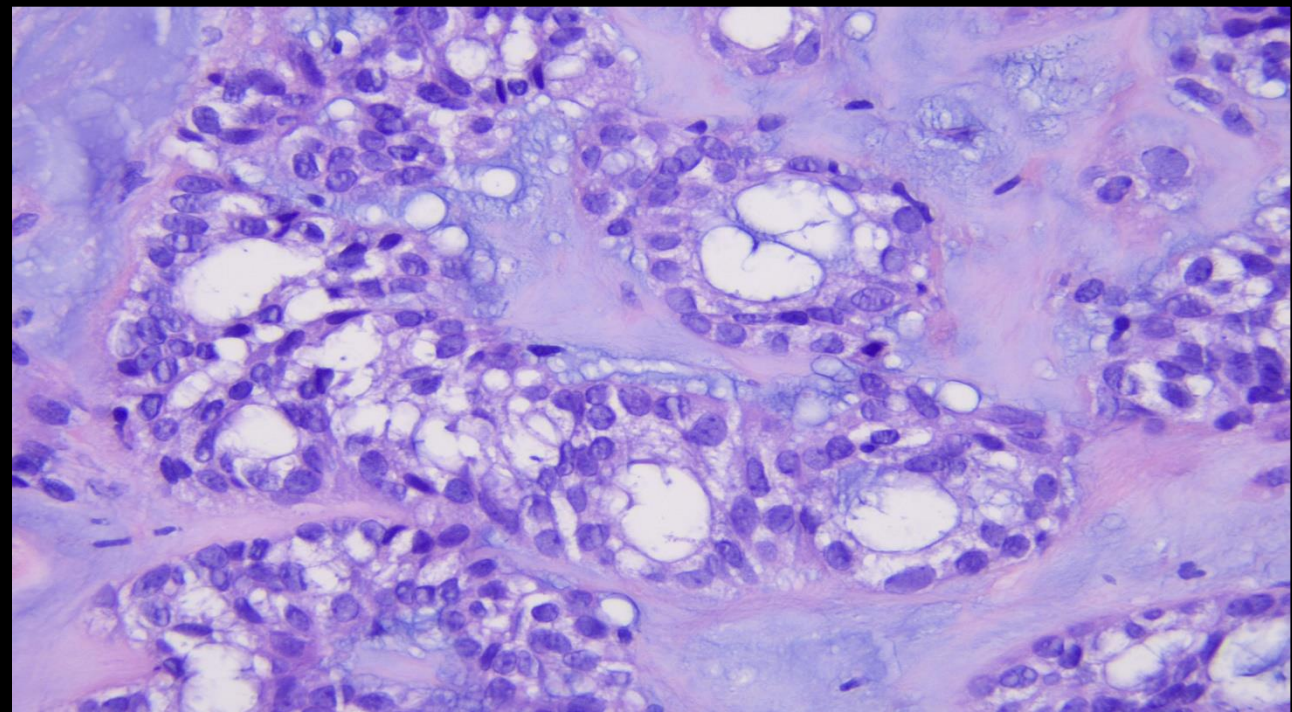
- LESIÓN ÁNGULO
MANDIBULAR IZQUIERDO
- LESIÓN COLA PARÓTIDA

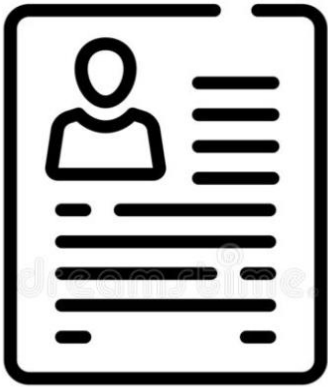


DIVERSIDAD ARQUITECTURAL

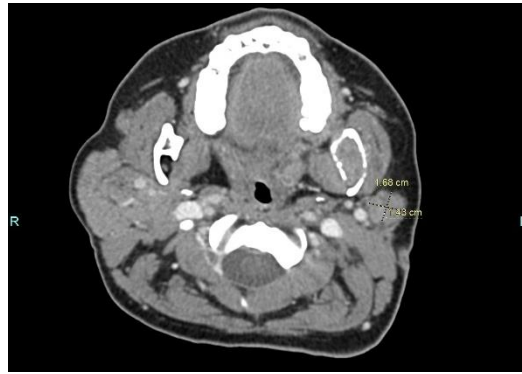


CELULARIDAD MONOMORFA

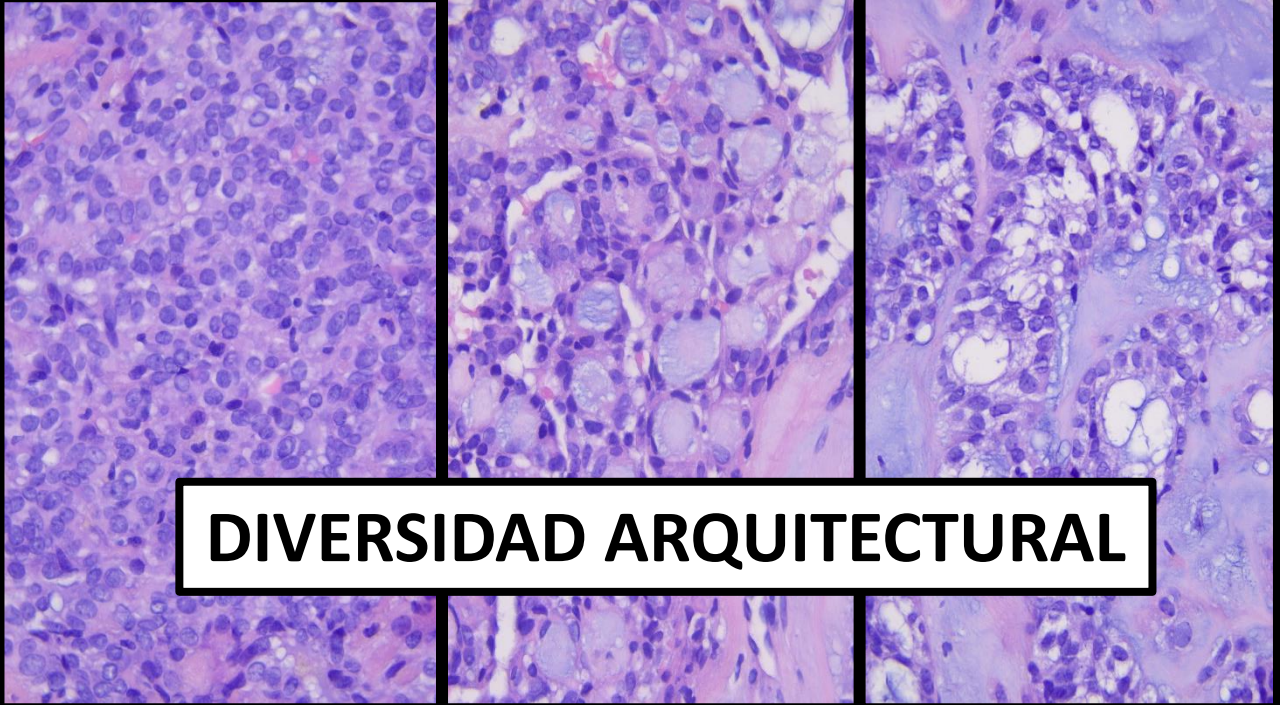




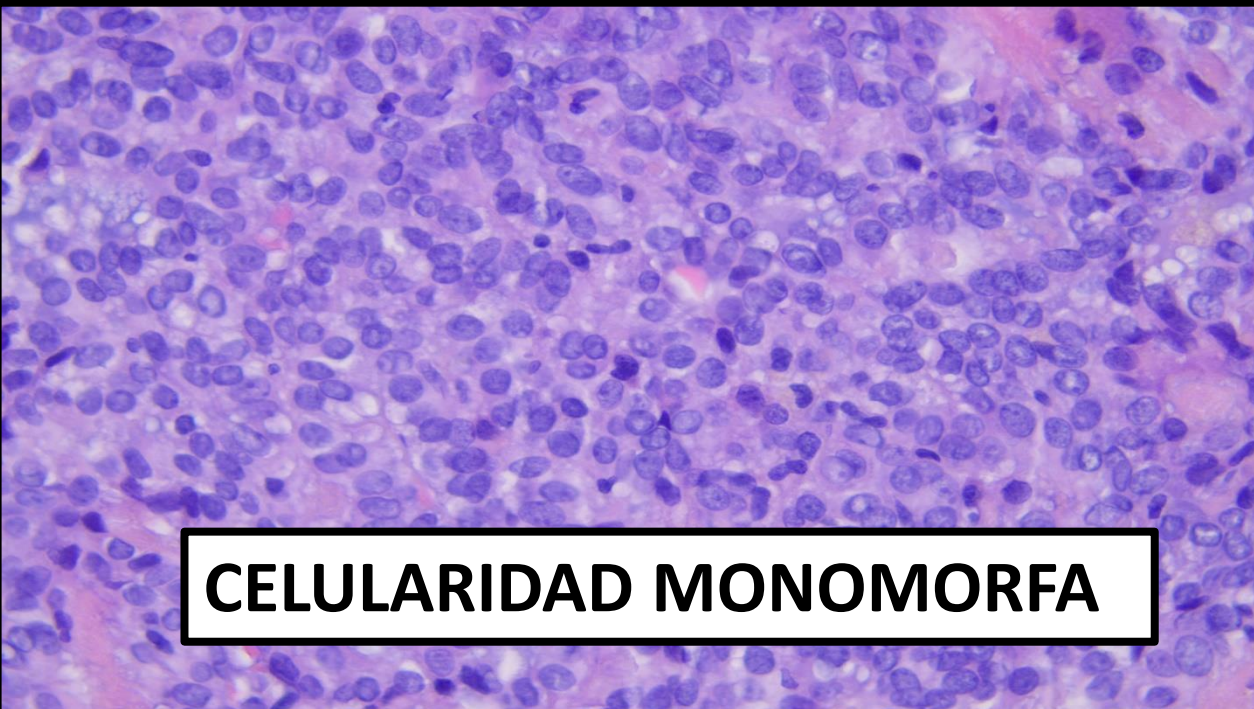ANTECEDENTE
"CARCINOMA" EN
PAROTIDA IZQ



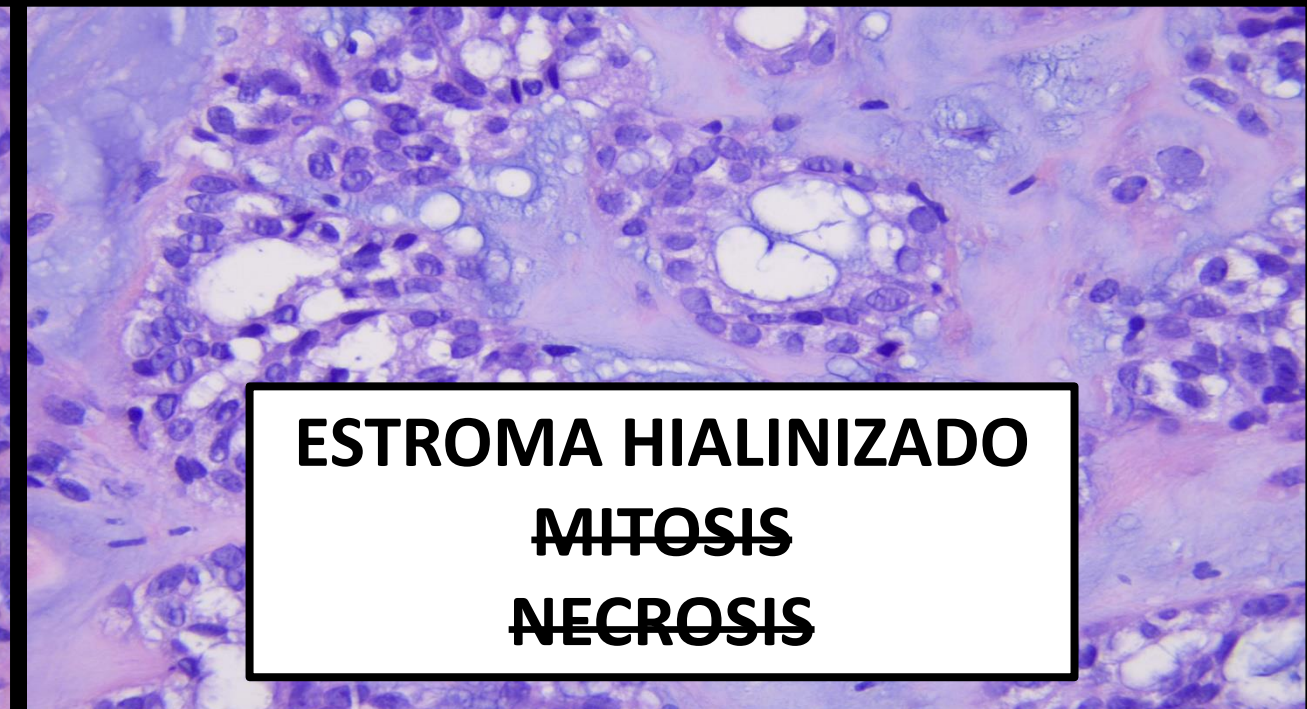- LESIÓN ÁNGULO
MANDIBULAR IZQUIERDO
- LESIÓN COLA PARÓTIDA



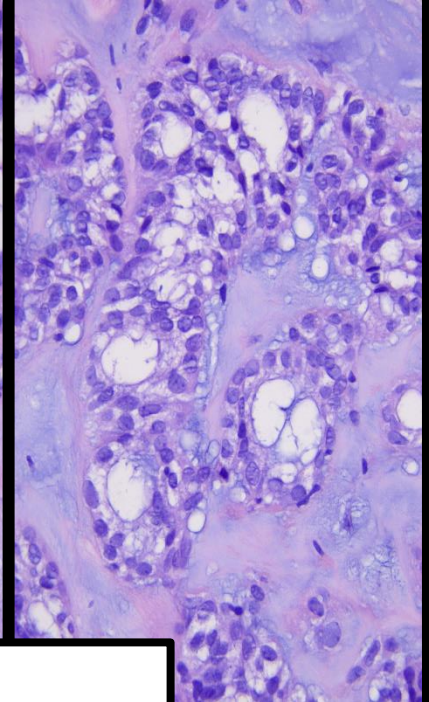
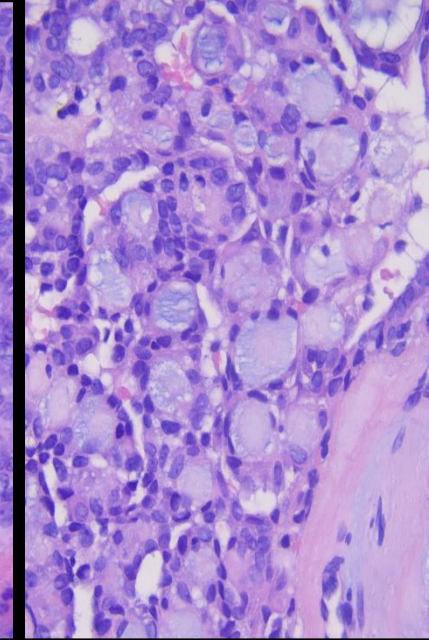
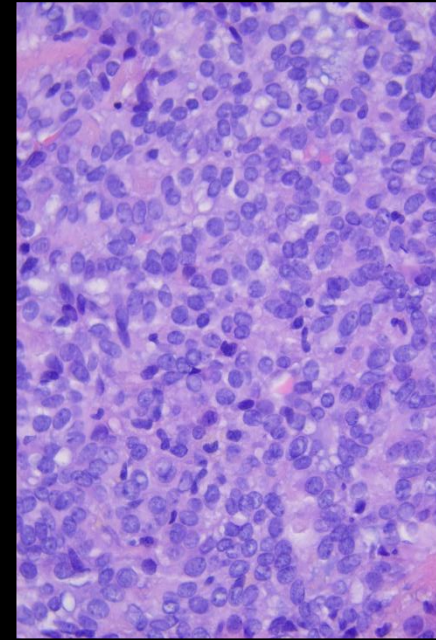
DIVERSIDAD ARQUITECTURAL



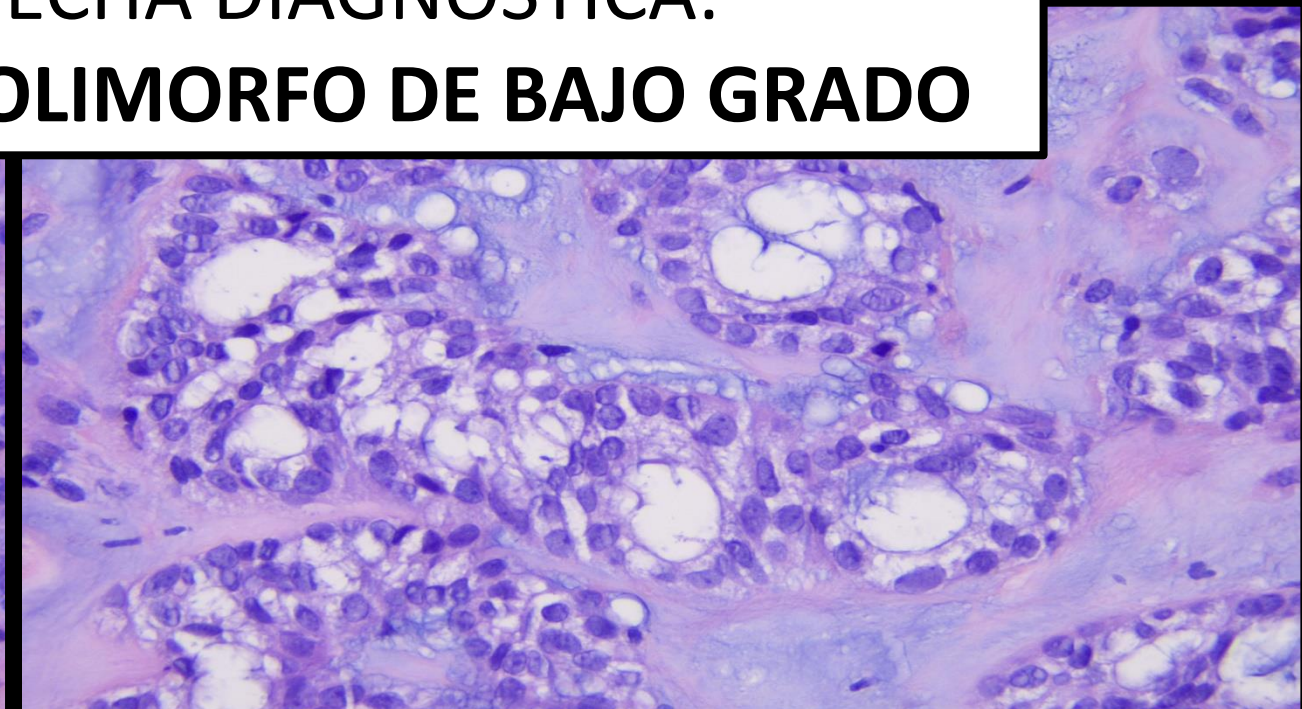
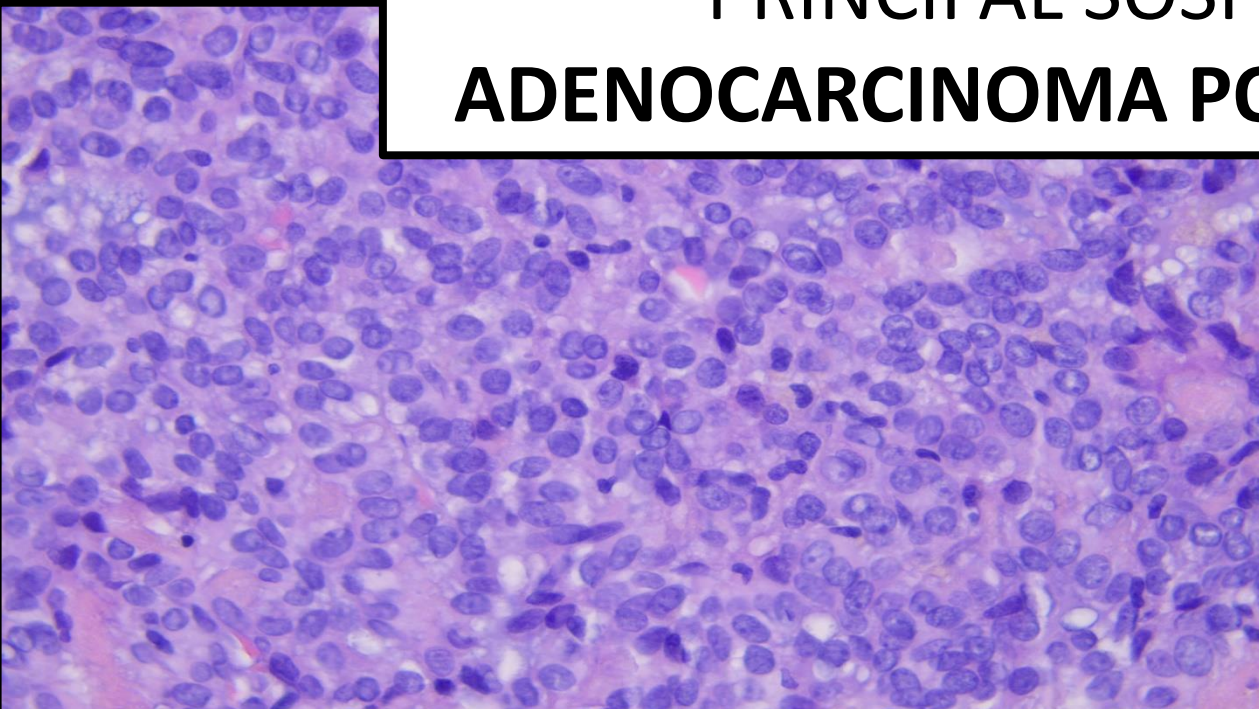
CELULARIDAD MONOMORFA



ESTROMA HIALINIZADO
MITOSIS
NECROSIS

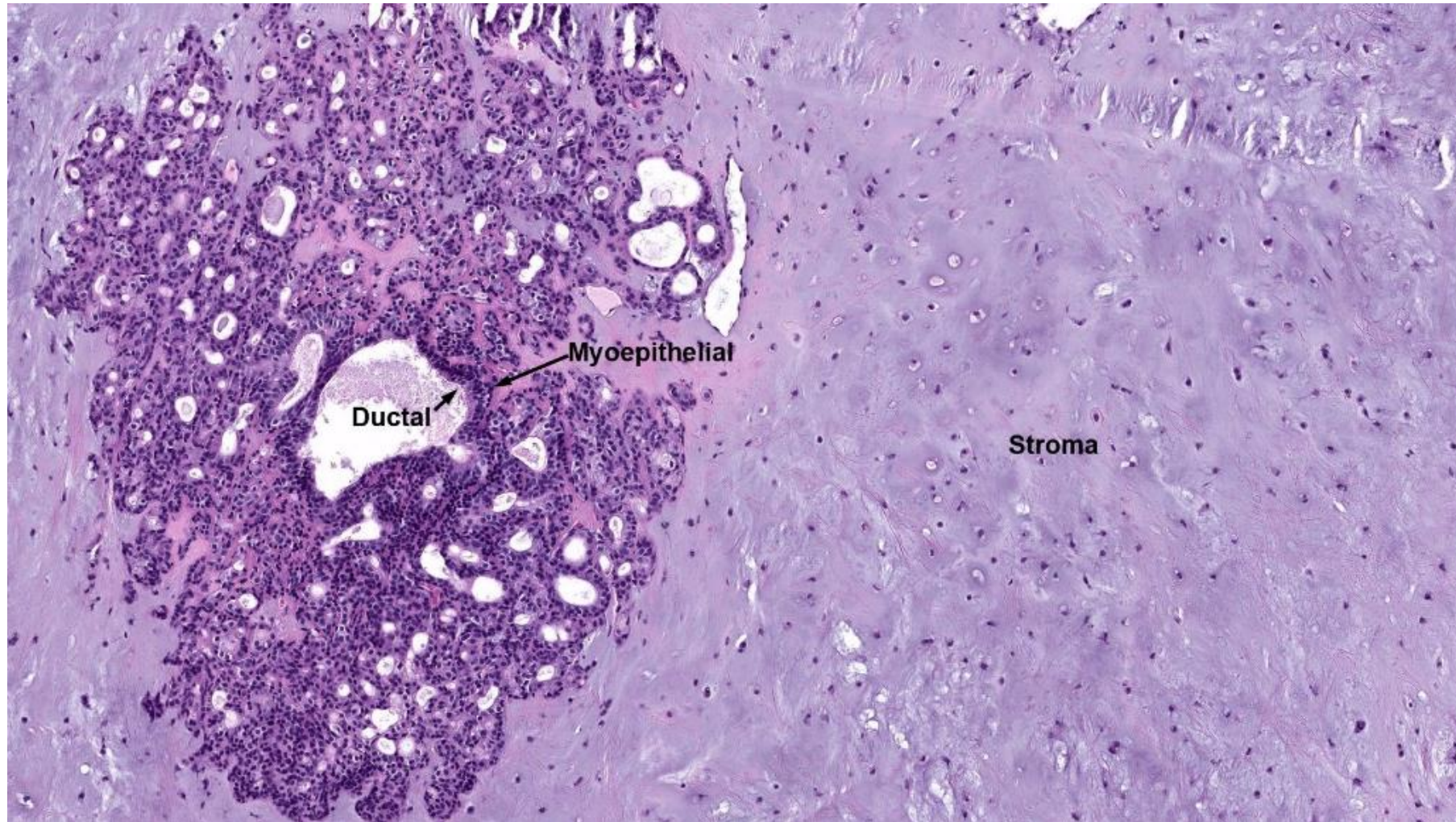


**PRINCIPAL SOSPECHA DIAGNÓSTICA:
ADENOCARCINOMA POLIMORFO DE BAJO GRADO**



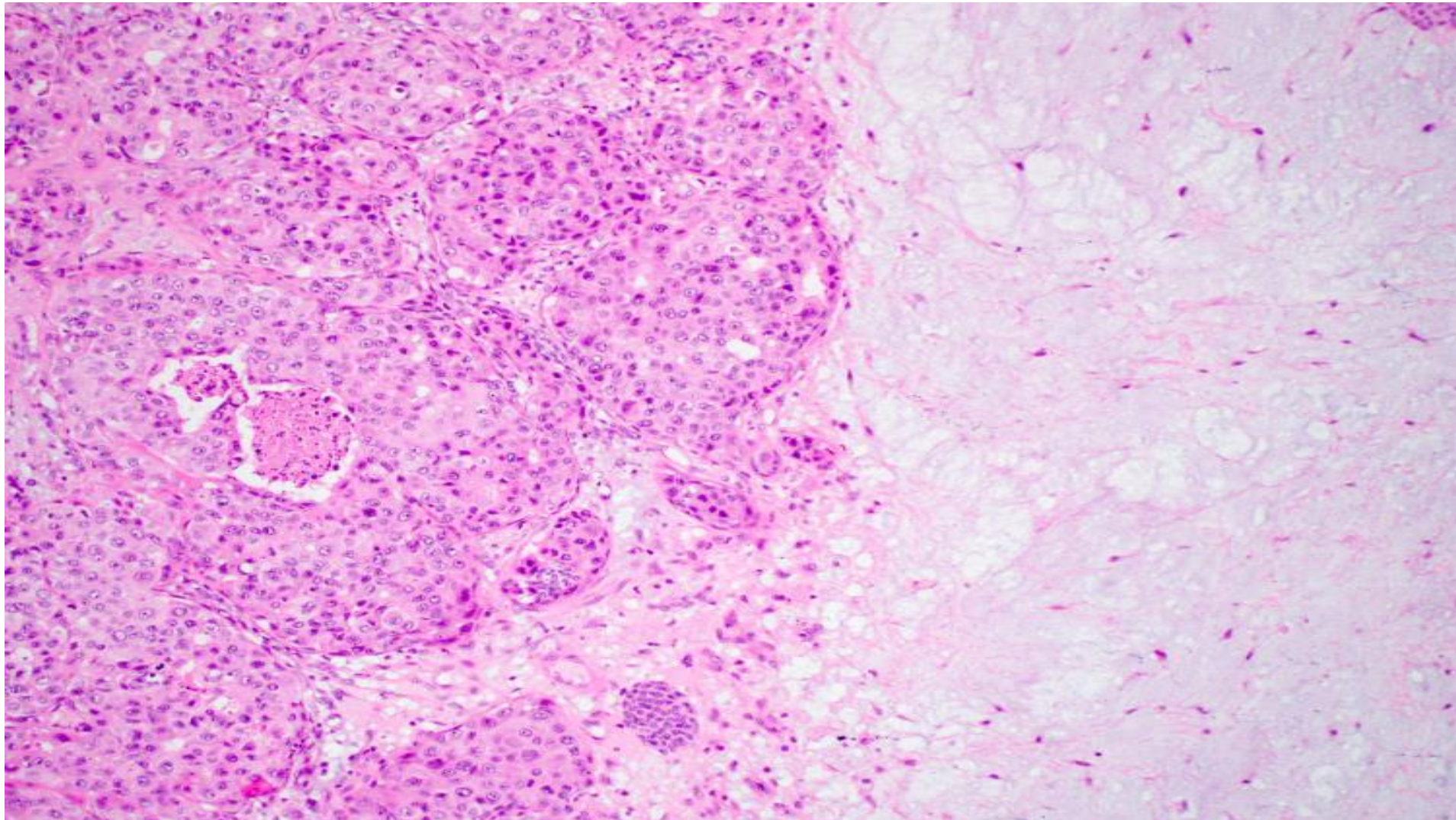
- 1. ADENOMA PLEOMÓRFICO**
- 2. CARCINOMA EX-ADENOMA PLEOMÓRFICO**
- 3. CARCINOMA ADENOIDE QUÍSTICO**
- 4. CARCINOMA MIOEPITELIAL**

ADENOMA PLEOMÓRFICO

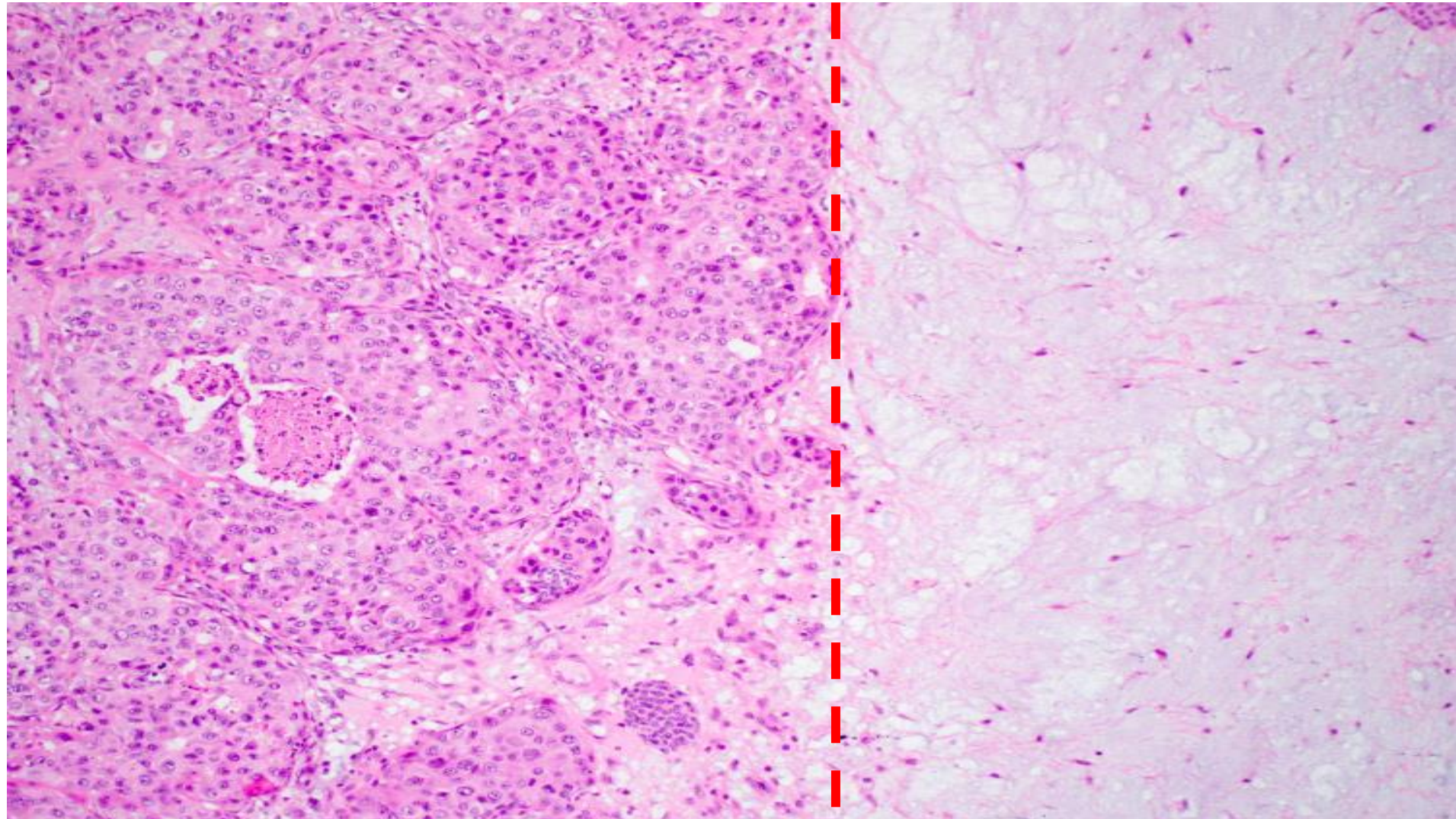


1. Componente epitelial ductal
2. Componente mioepitelial
3. Componente estromal mixoide/condroide/hialinizado.

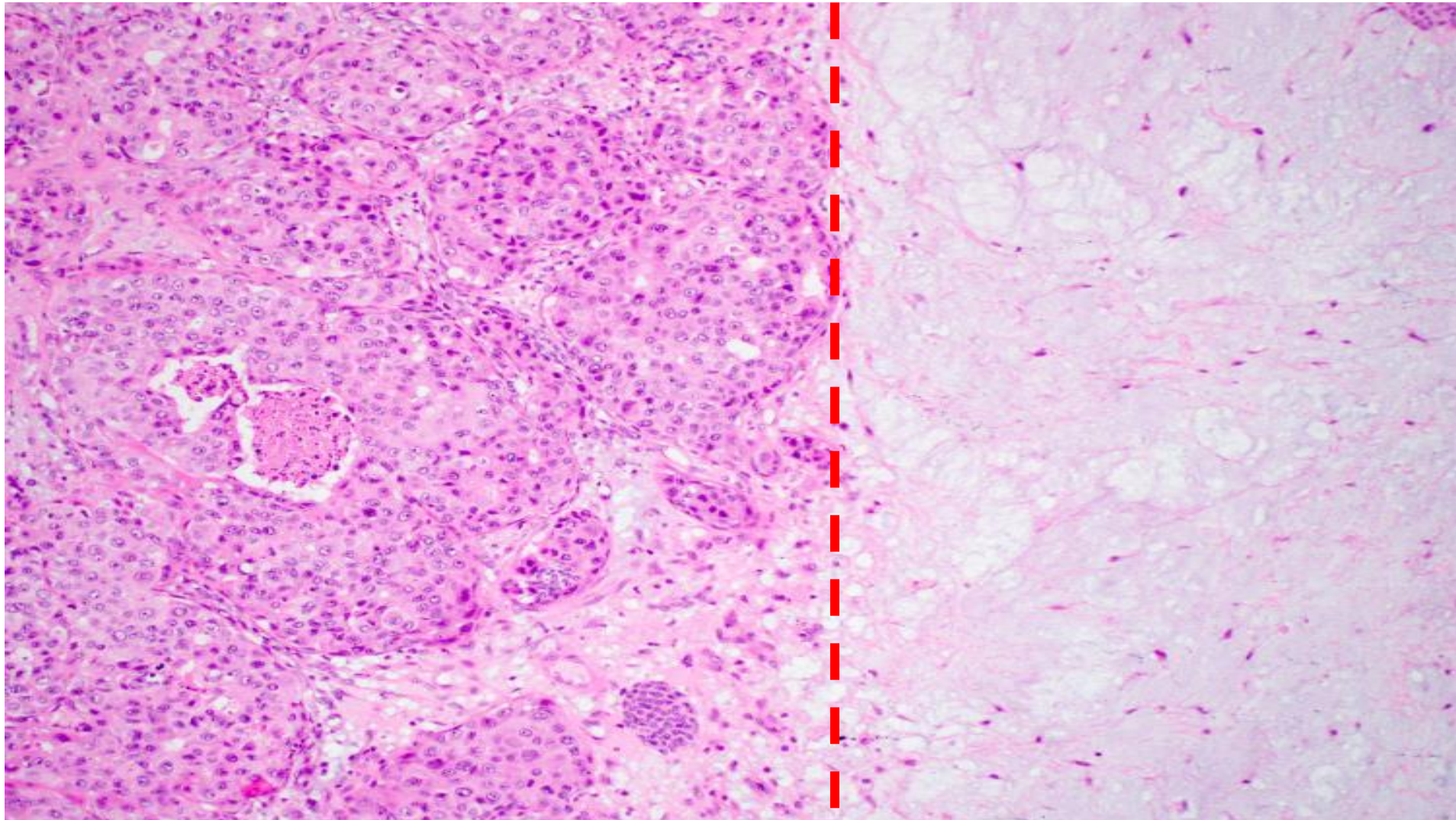
CARCINOMA EX-ADENOMA PLEOMÓRFICO



CARCINOMA EX-ADENOMA PLEOMÓRFICO



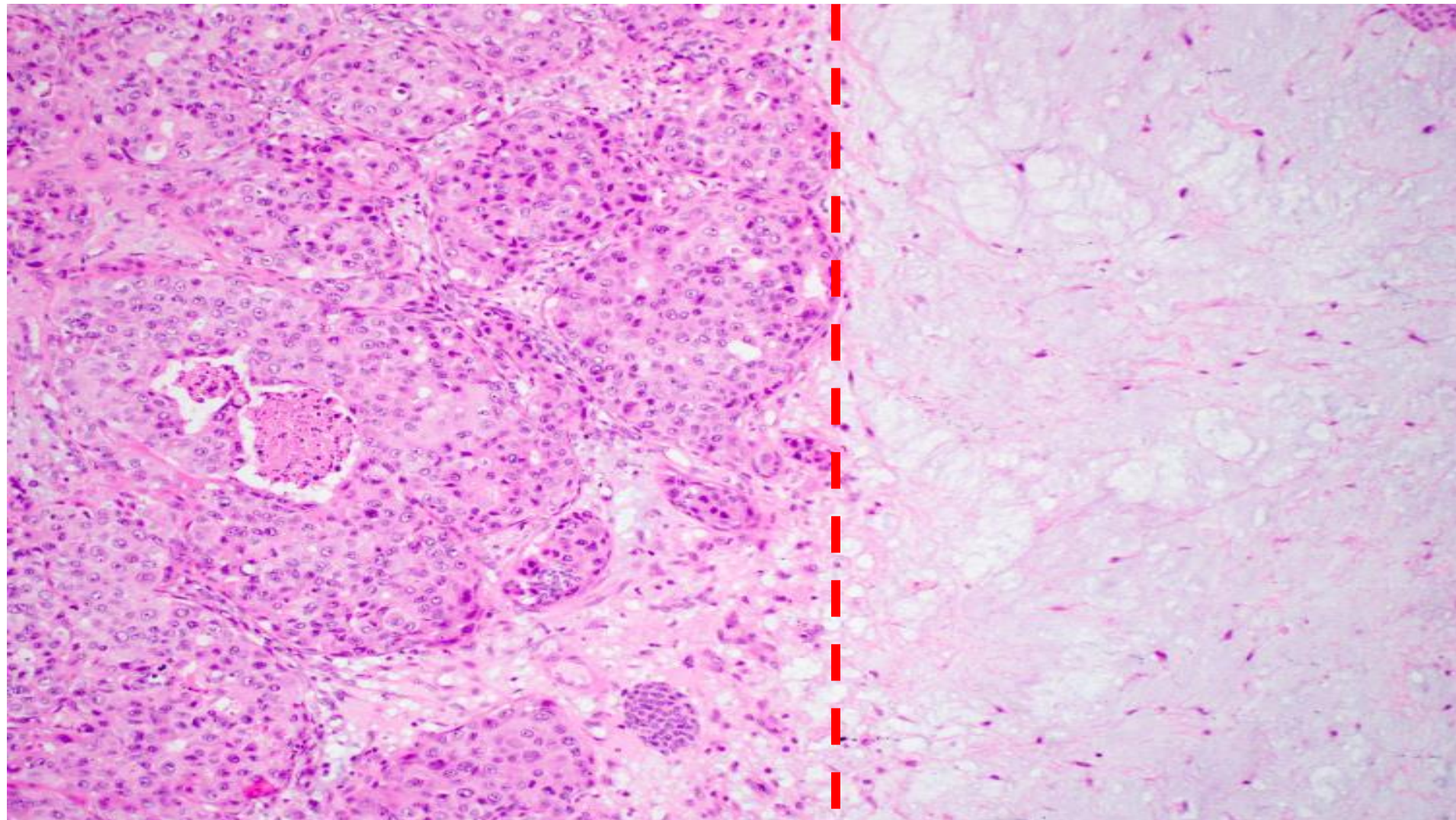
CARCINOMA EX-ADENOMA PLEOMÓRFICO



CARCINOMA

- Epitelial
- Mioepitelial

CARCINOMA EX-ADENOMA PLEOMÓRFICO



CARCINOMA

- Epitelial
- Mioepitelial

ADENOMA PLEOMÓRFICO

CARCINOMA ADENOIDE QUÍSTICO



ARQUITECTURA SÓLIDA

This histological image shows a solid architecture of adenoid cystic carcinoma. The tumor cells are arranged in a dense, solid sheet, with a characteristic cribriform pattern of small, rounded spaces. The cells are stained with hematoxylin and eosin (H&E), showing purple nuclei and pink cytoplasm and extracellular matrix.



ARQUITECTURA CRIBIFORME

This histological image shows a cribriform architecture of adenoid cystic carcinoma. The tumor cells are arranged in a cribriform pattern, characterized by a honeycomb-like structure with numerous small, rounded spaces. The cells are stained with hematoxylin and eosin (H&E), showing purple nuclei and pink cytoplasm and extracellular matrix.



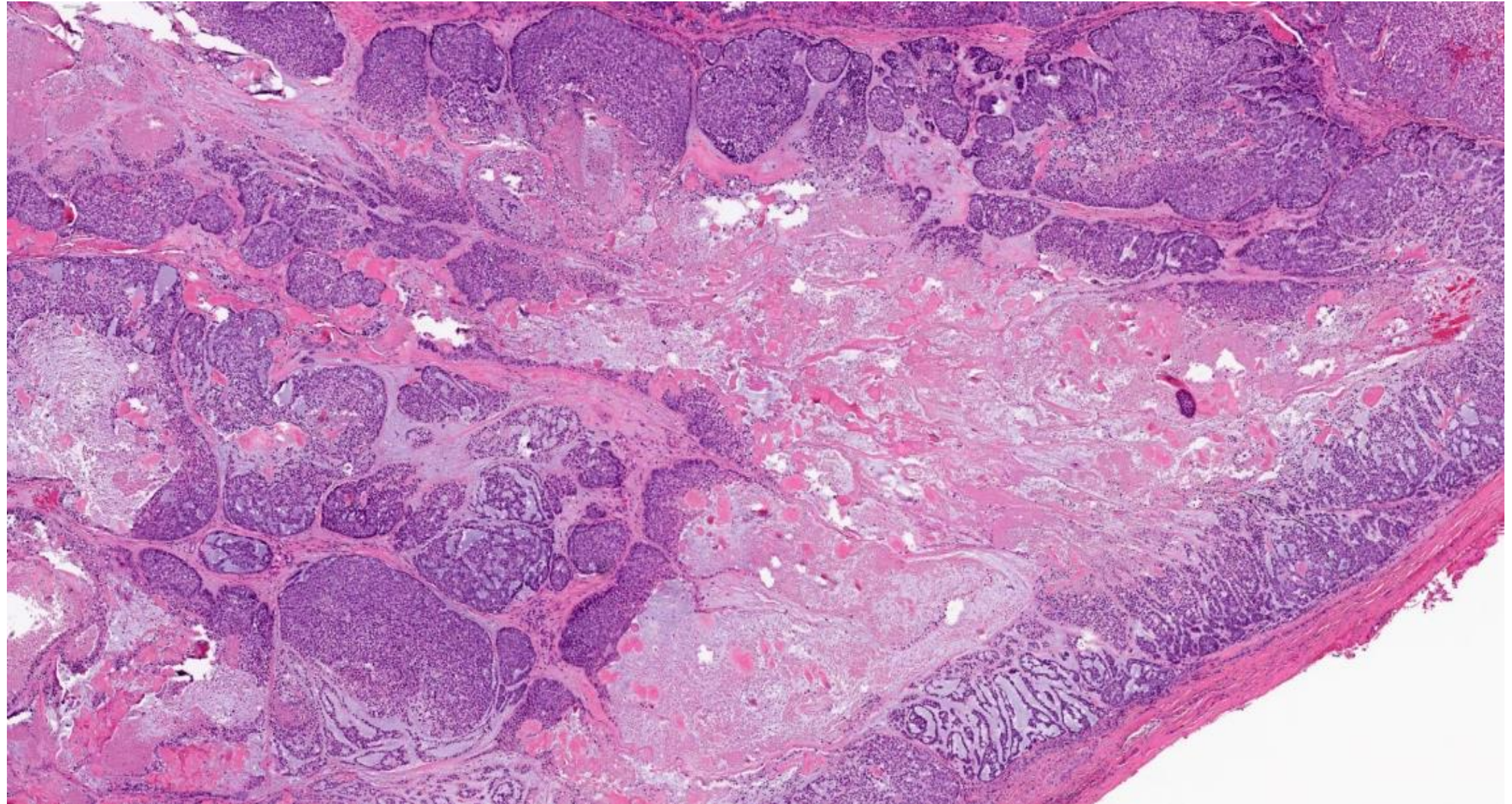
ARQUITECTURA TUBULAR

This histological image shows a tubular architecture of adenoid cystic carcinoma. The tumor cells are arranged in a tubular pattern, characterized by the formation of irregular, glandular-like structures. The cells are stained with hematoxylin and eosin (H&E), showing purple nuclei and pink cytoplasm and extracellular matrix.

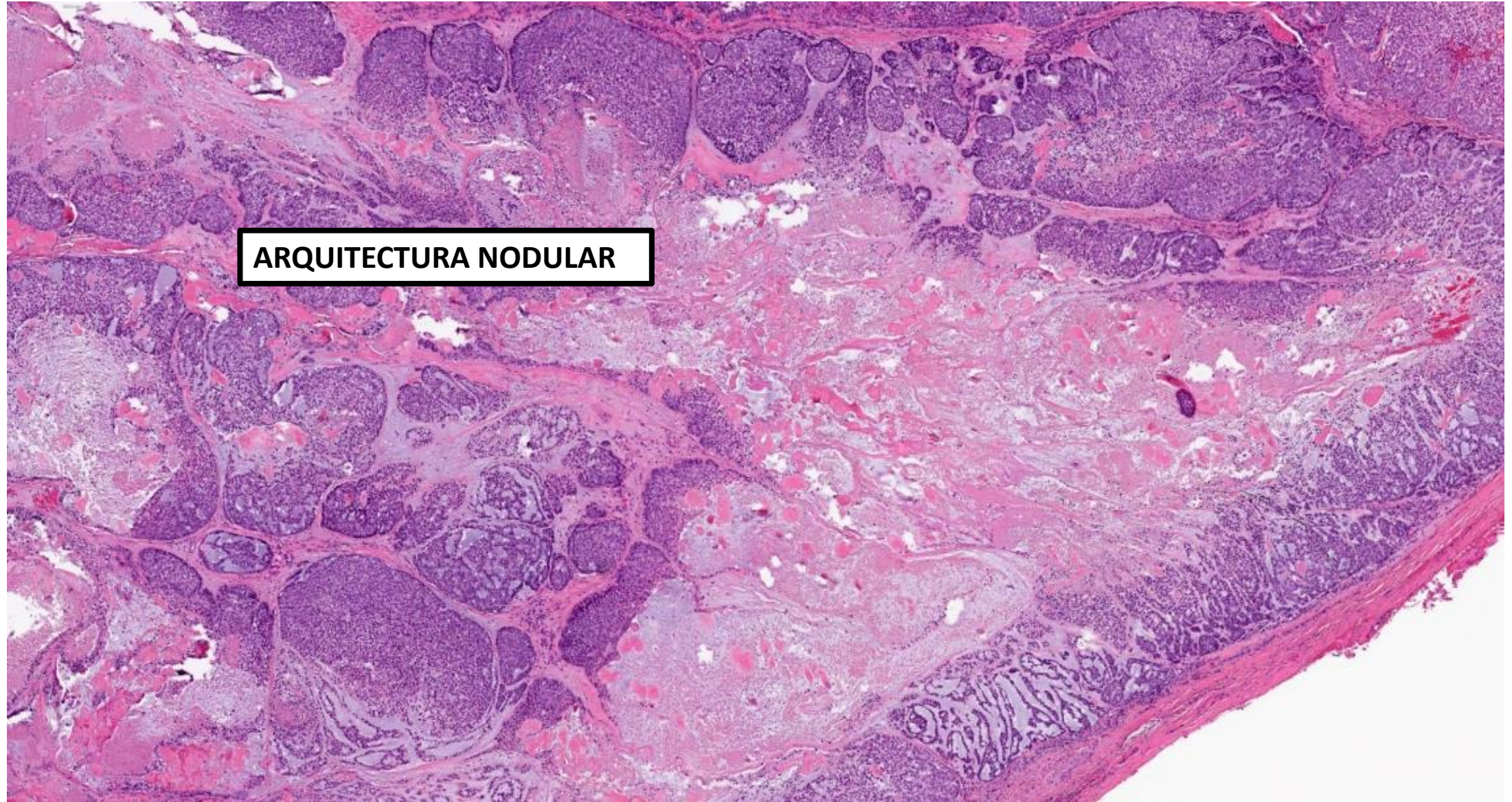
TUMOR BIFÁSICO:

1. Diferenciación ductal (epitelial).
2. Diferenciación mioepitelial.

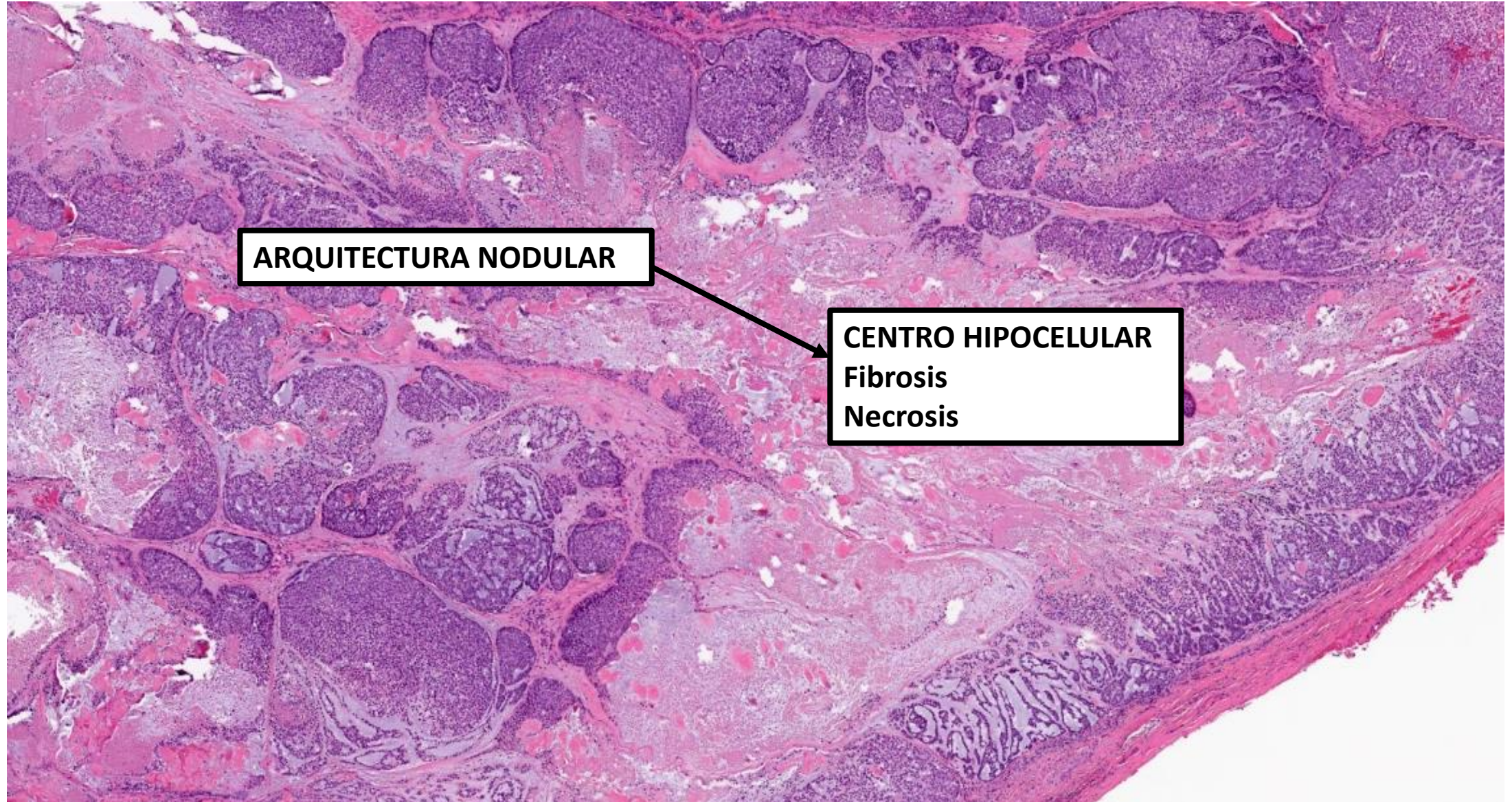
CARCINOMA MIOEPITELIAL



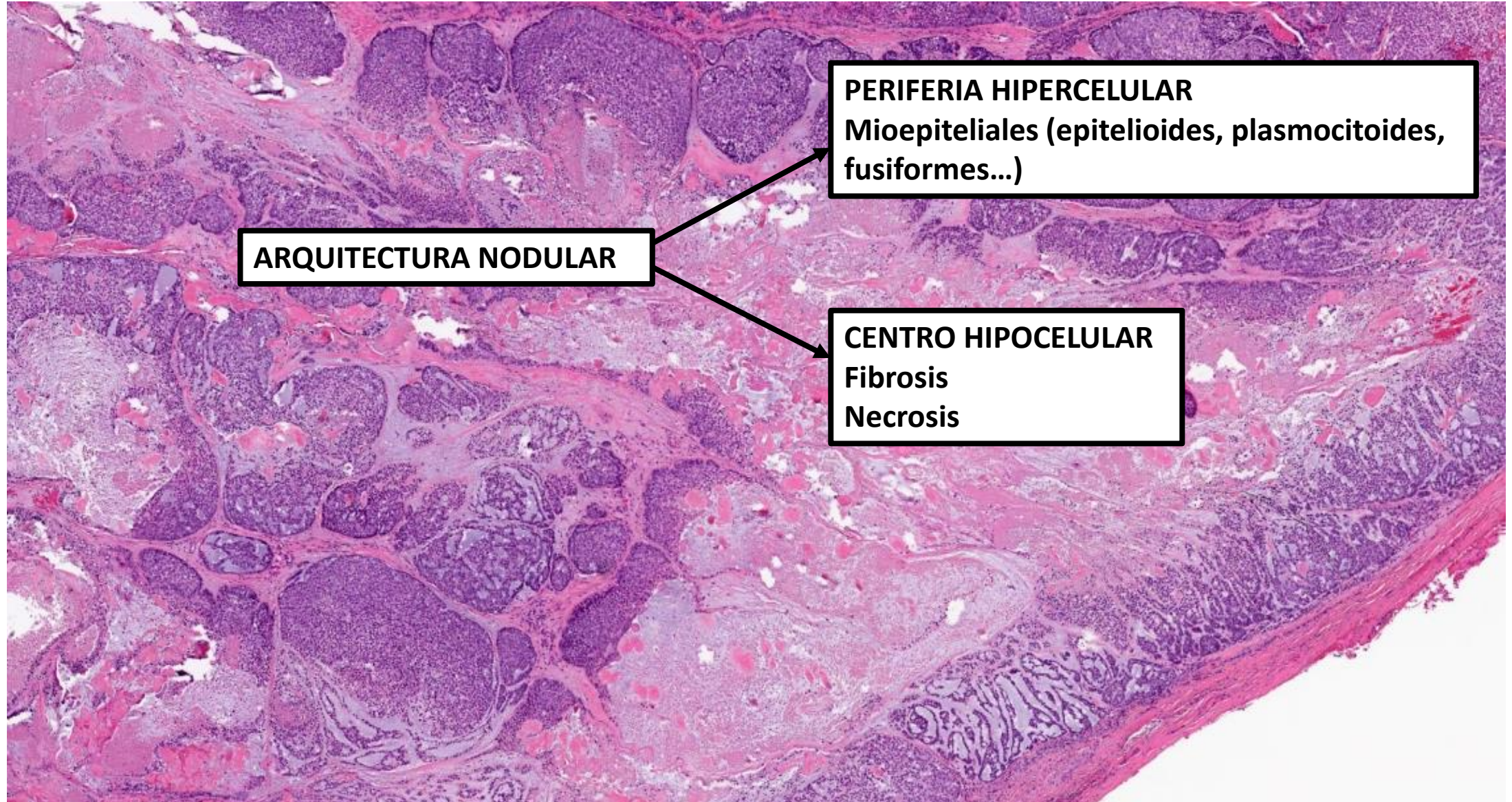
CARCINOMA MIOEPIHELIAL



CARCINOMA MIOEPIHELIAL



CARCINOMA MIOEPIHELIAL



ARQUITECTURA NODULAR

PERIFERIA HIPERCELULAR

Mioepiteliales (epitelioides, plasmocitoides, fusiformes...)

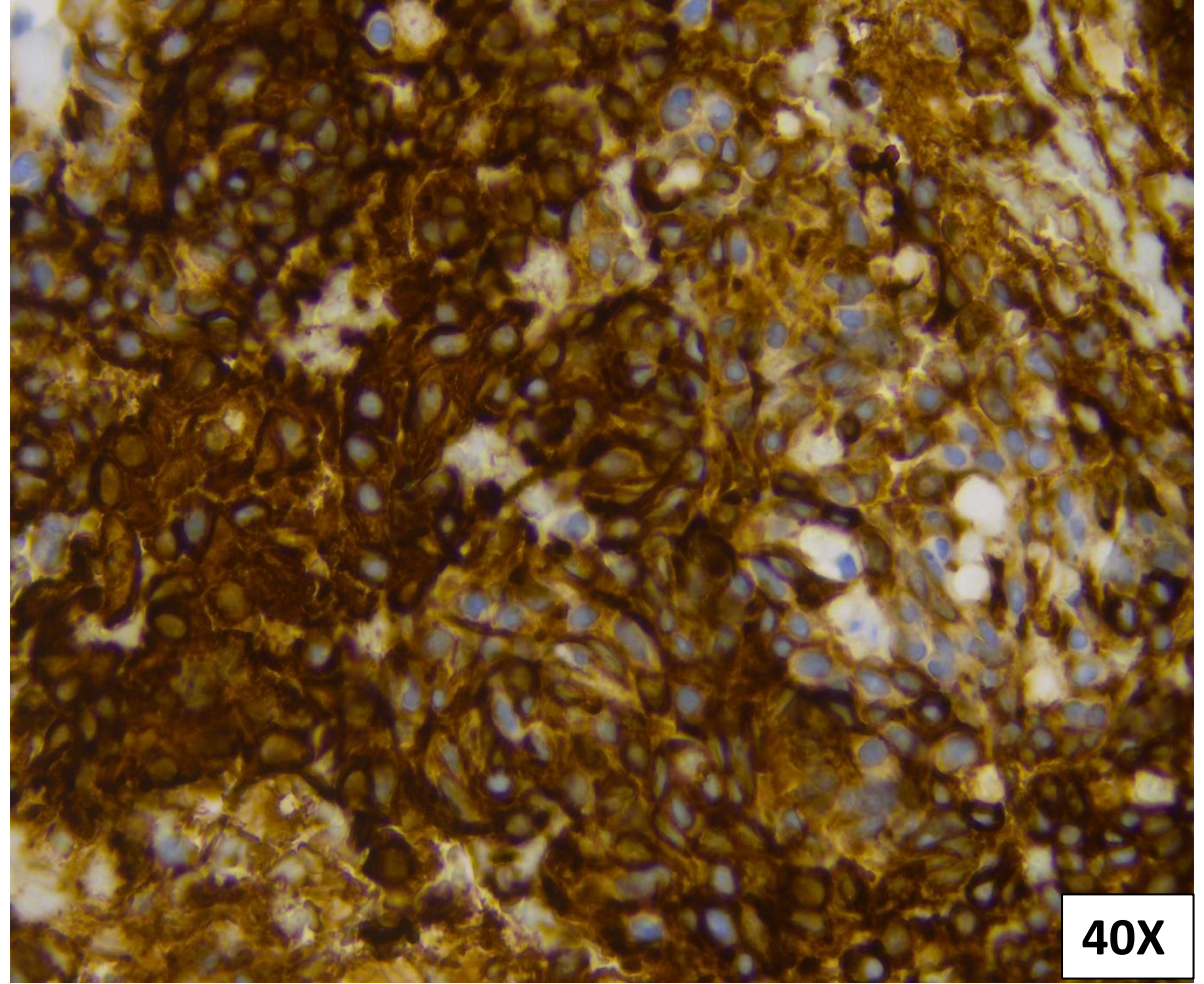
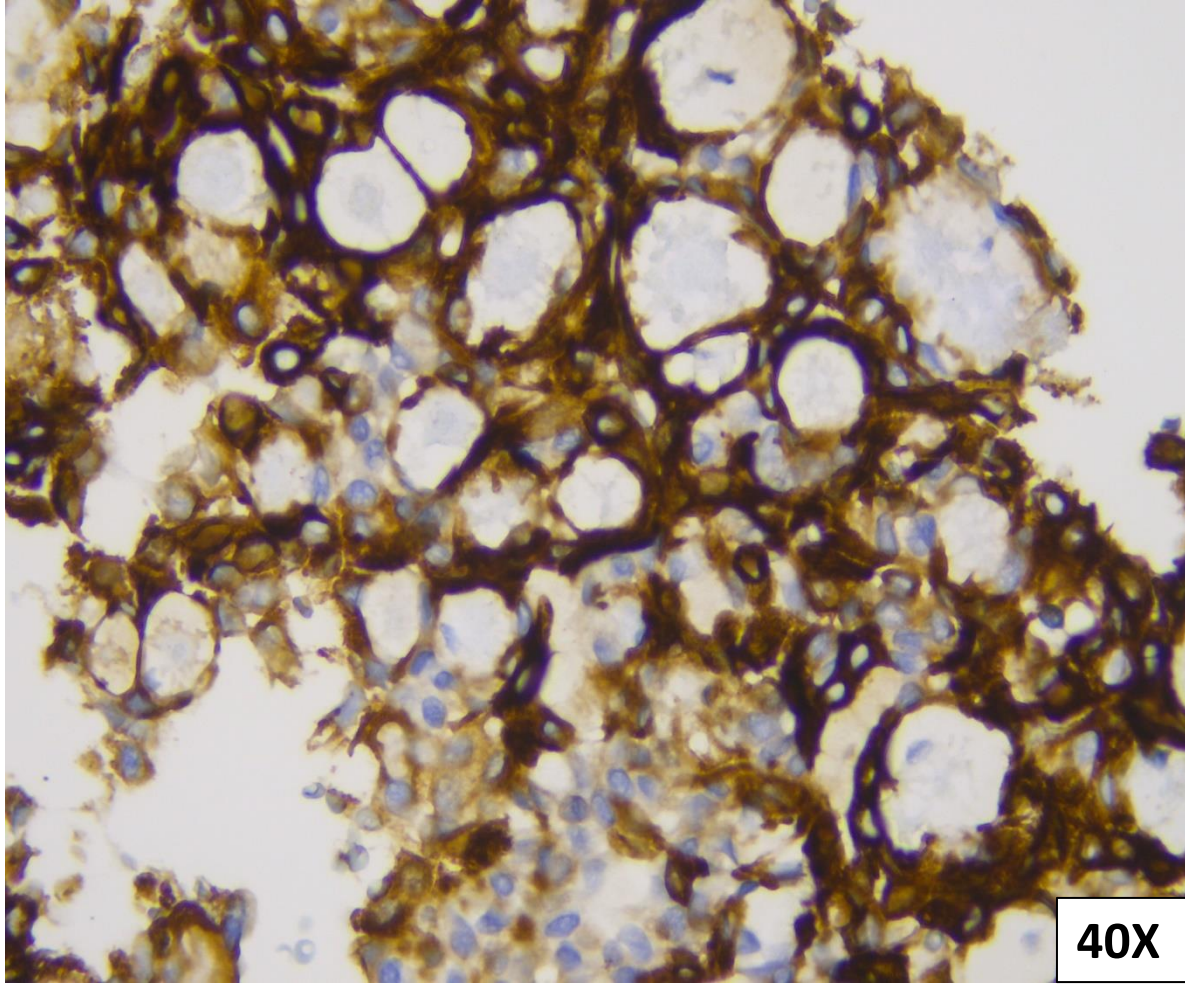
CENTRO HIPOCELULAR

Fibrosis
Necrosis

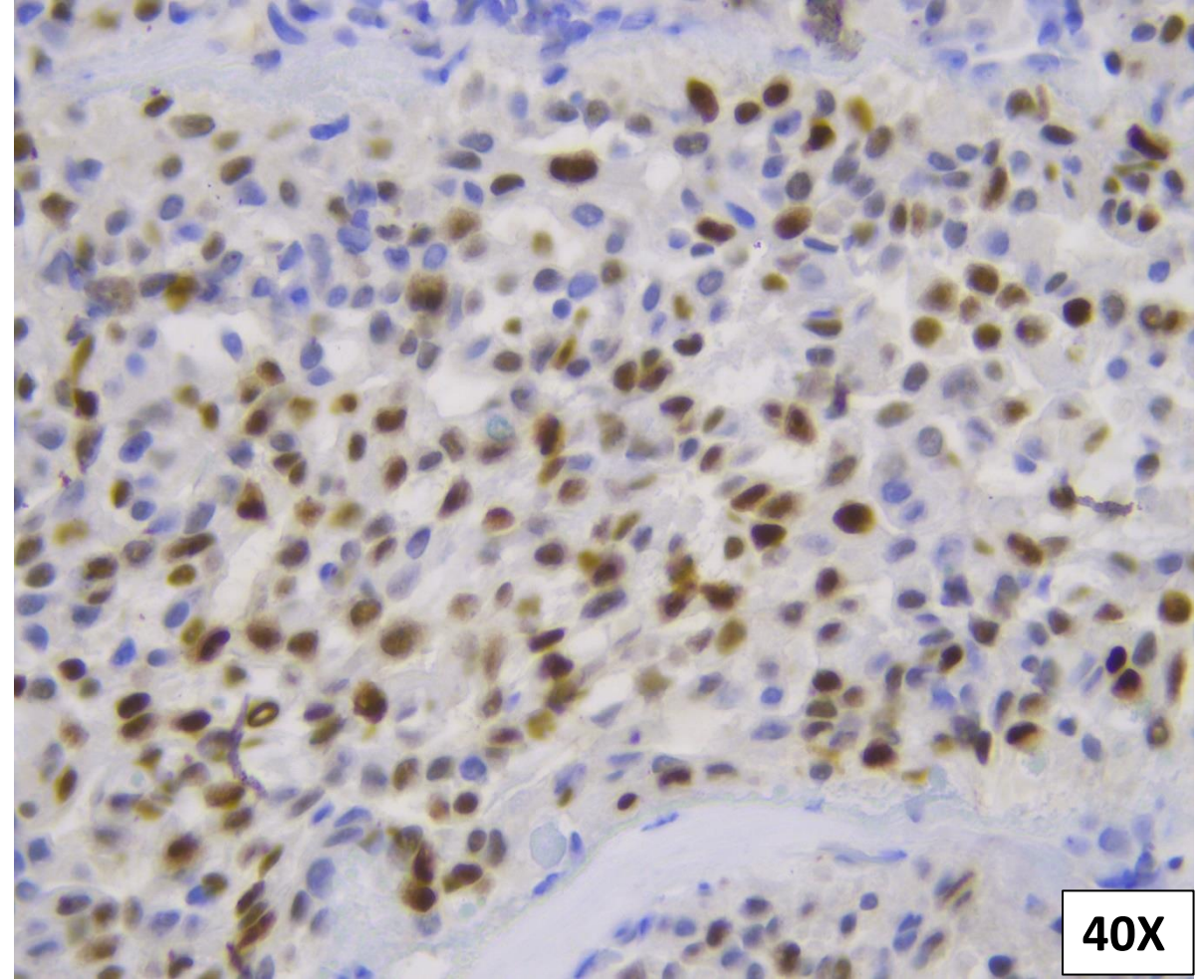
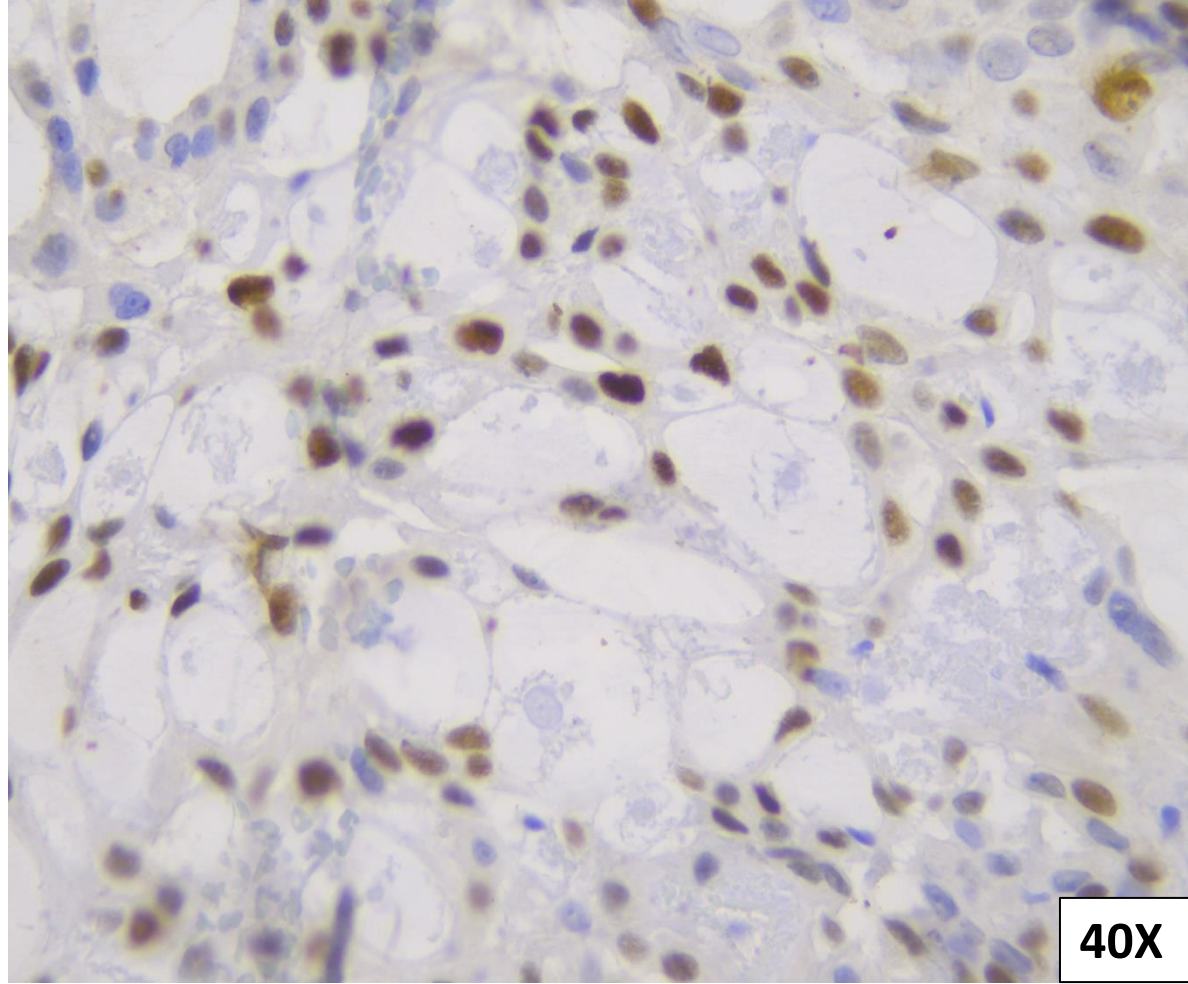
ESTUDIO INMUNOHISTOQUÍMICO

	P63	P40	GFAP	ACTINA ML
ADENOCARCINOMA POLIMORFO DE BAJO GRADO	+	-	-	-
ADENOMA PLEOMÓRFICO (Componente mioepitelial)	+	+	+	+
CARCINOMA EX-ADENOMA PLEOMÓRFICO (Componente mioepitelial)	+	+	+	+
CARCINOMA ADENOIDE QUÍSTICO (Componente mioepitelial)	+	+	+	+
CARCINOMA MIOEPITELIAL	+	+	+	+

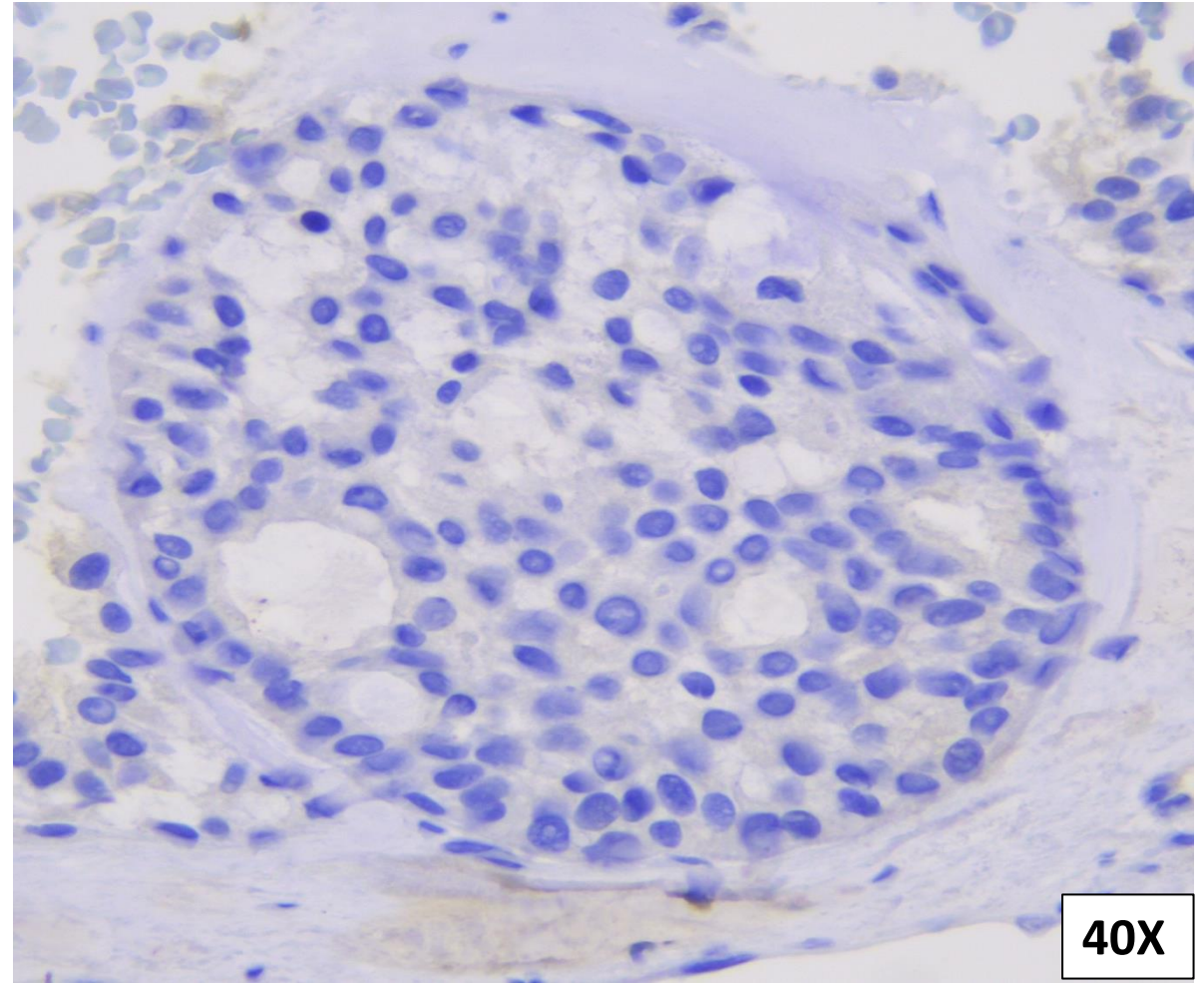
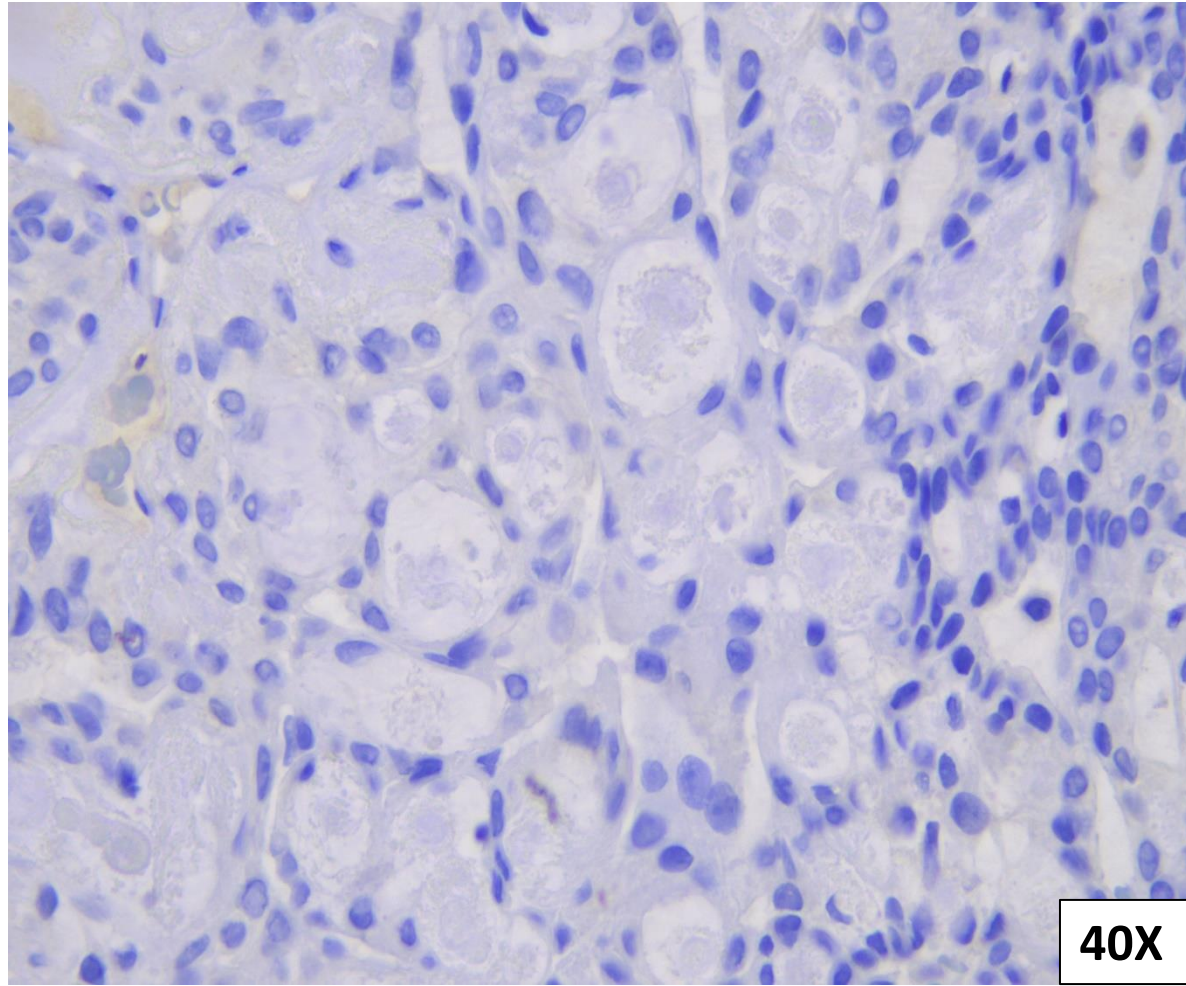
CK7



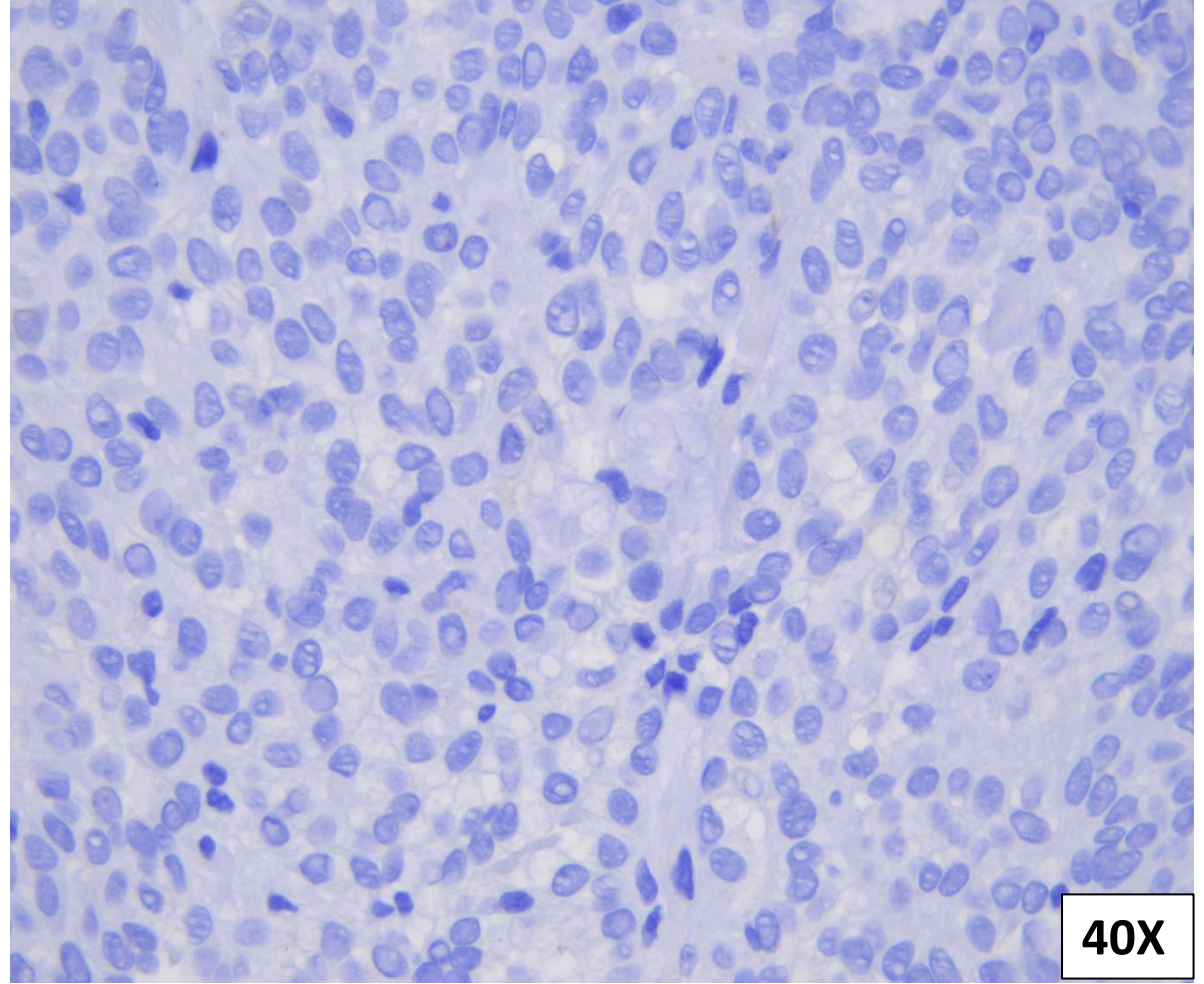
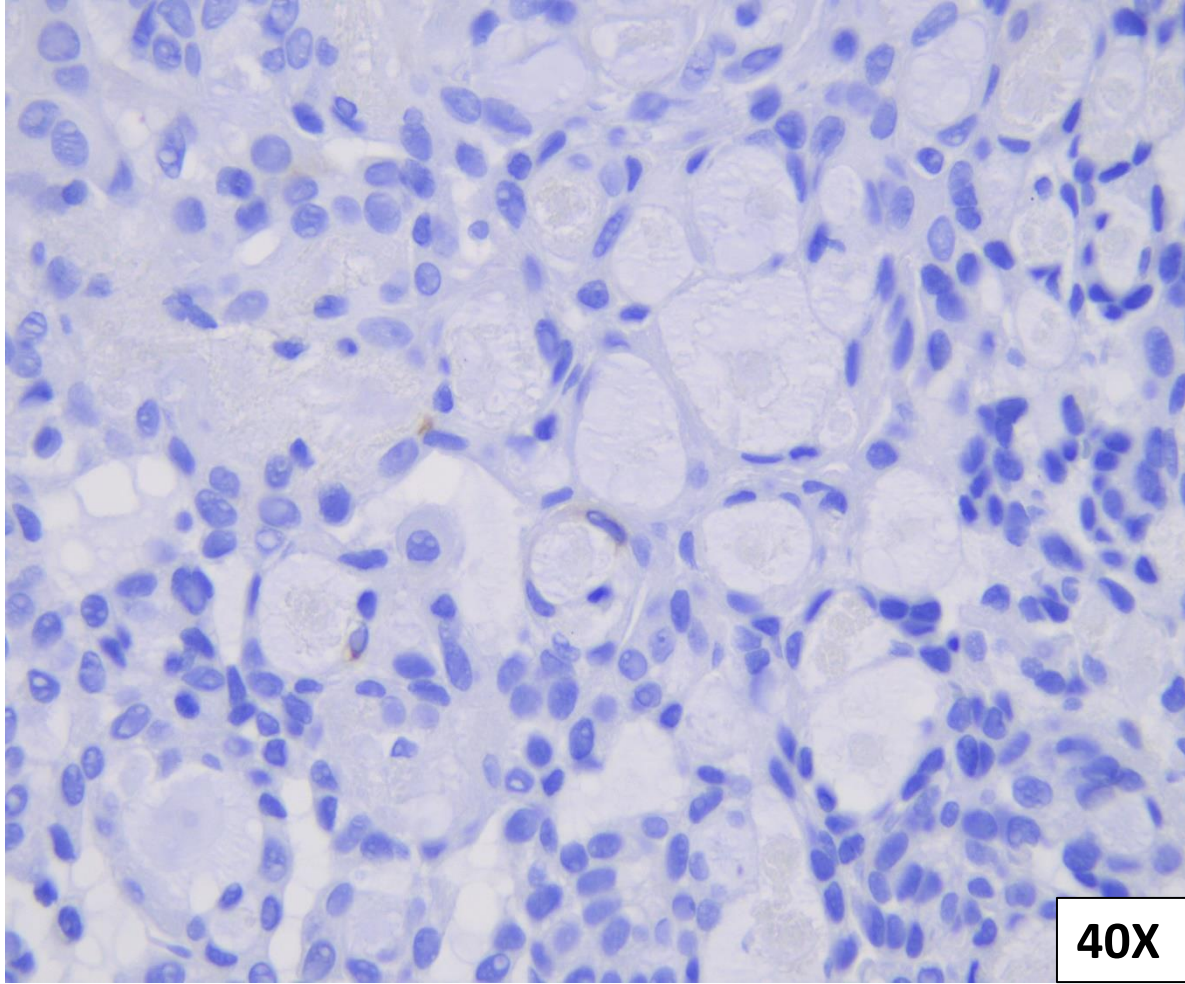
P63



P40



GFAP



ESTUDIO INMUNOHISTOQUÍMICO

	P63	P40	GFAP	ACTINA ML
ADENOCARCINOMA POLIMORFO DE BAJO GRADO	+	-	-	-
ADENOMA PLEOMÓRFICO (Componente mioepitelial)	+	+	+	+
CARCINOMA EX-ADENOMA PLEOMÓRFICO (Componente mioepitelial)	+	+	+	+
CARCINOMA ADENOIDE QUÍSTICO (Componente mioepitelial)	+	+	+	+
CARCINOMA MIOEPITELIAL	+	+	+	+

ADENOCARCINOMA POLIMORFO DE BAJO GRADO

MUCHAS GRACIAS POR SU ATENCIÓN