Hombre de 59 años con lesiones cutáneas y alteraciones hematológicas

Paula Toro Soto, Sonia Cigüenza Sancho, Miguel Trigueros Mateos, Ana Teruel del Valle, F. Ignacio Aranda López
Servicio de Anatomía Patológica
Hospital General Universitario de Alicante

- Hombre, 59 años
- Linfocitopenia + lesiones maculopapulares en abdomen y extremidades

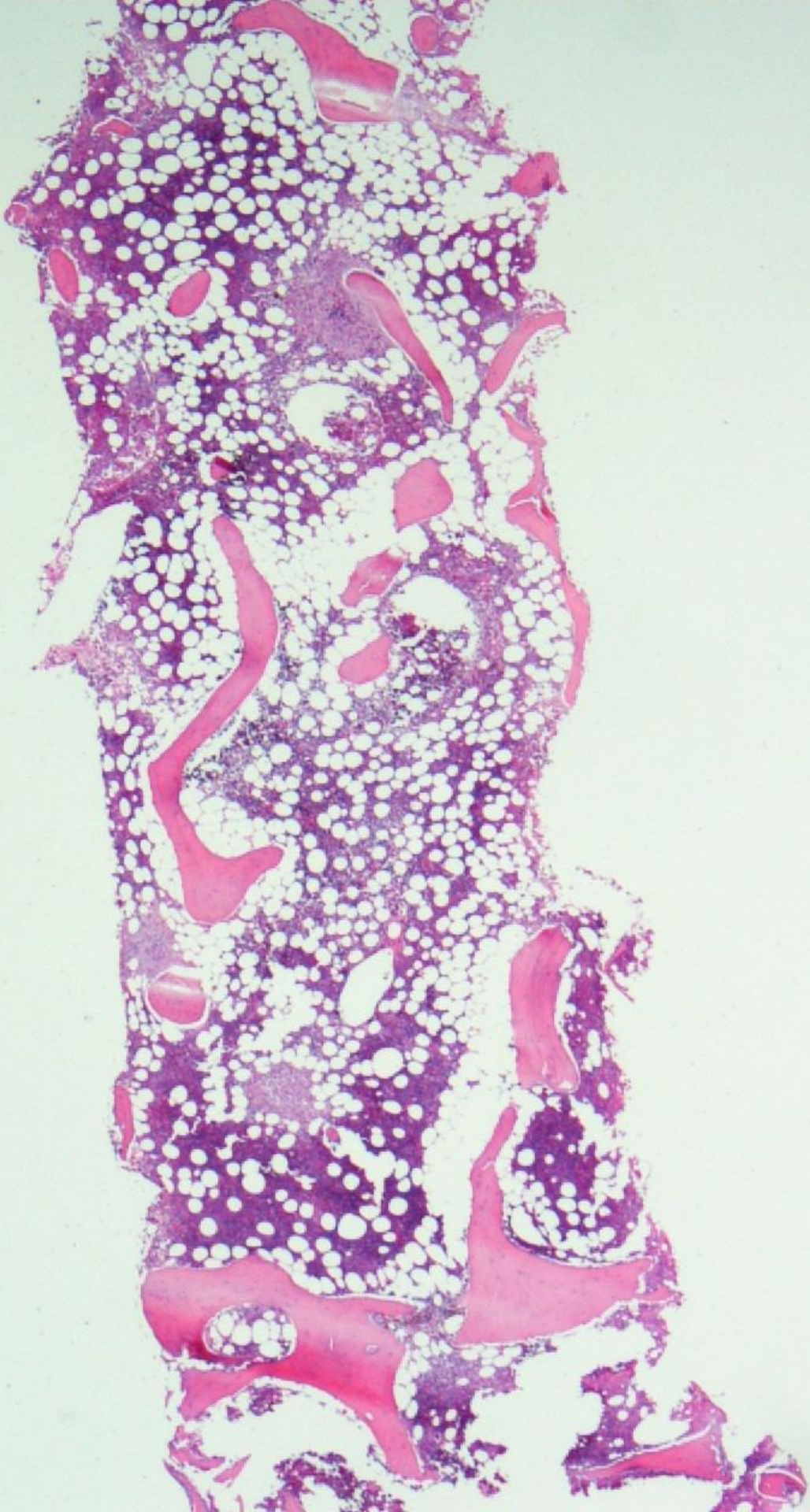

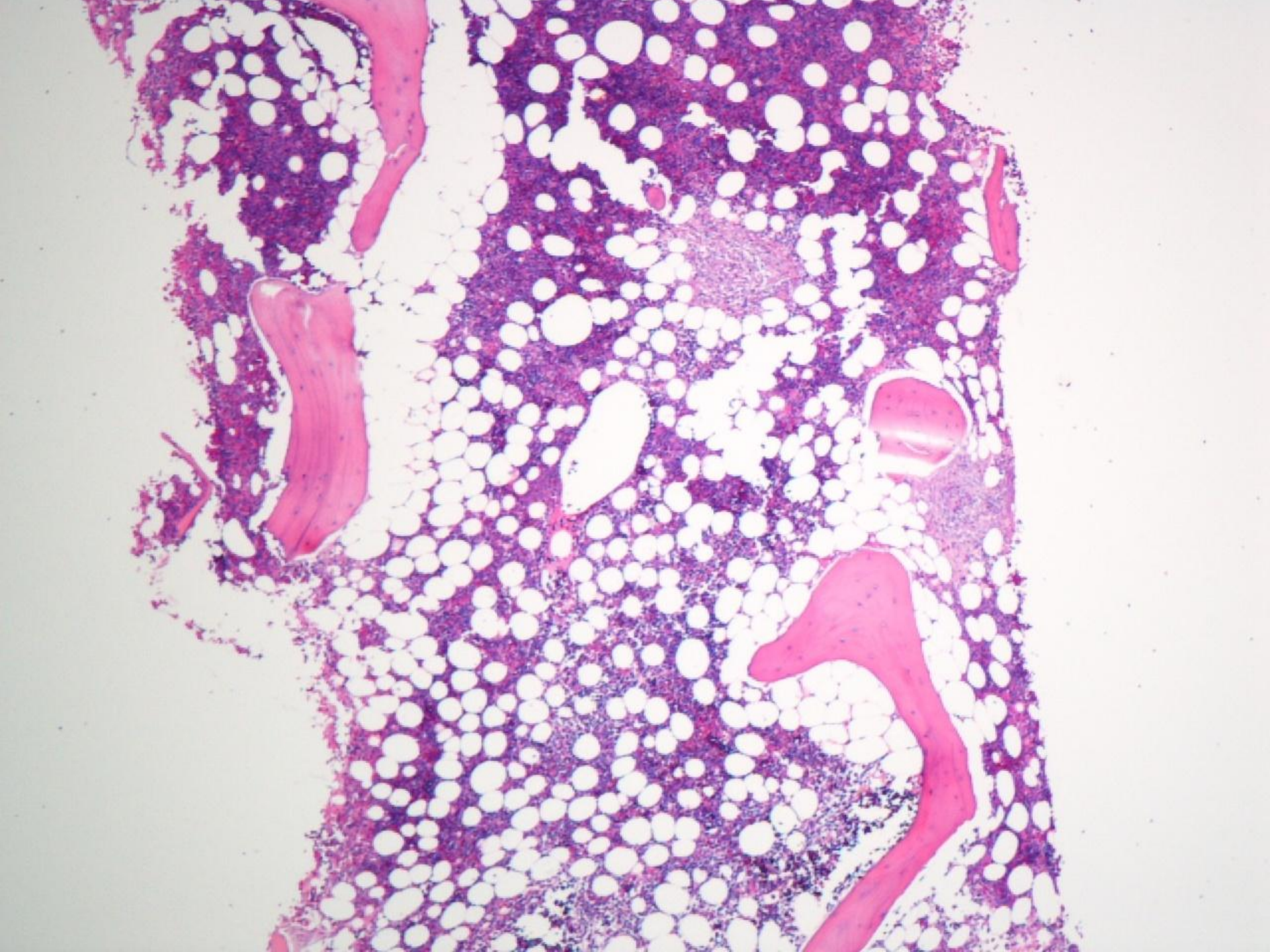

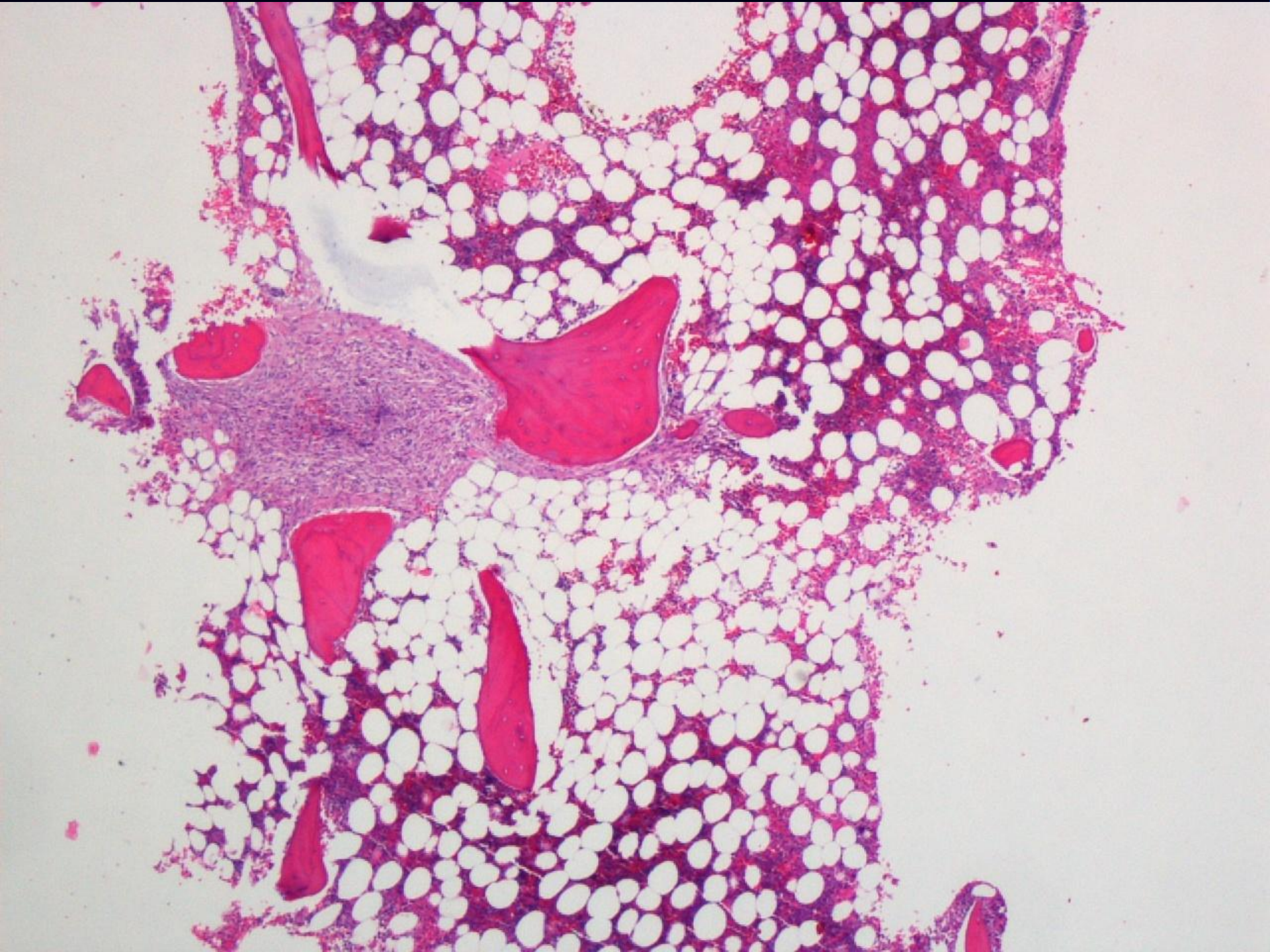

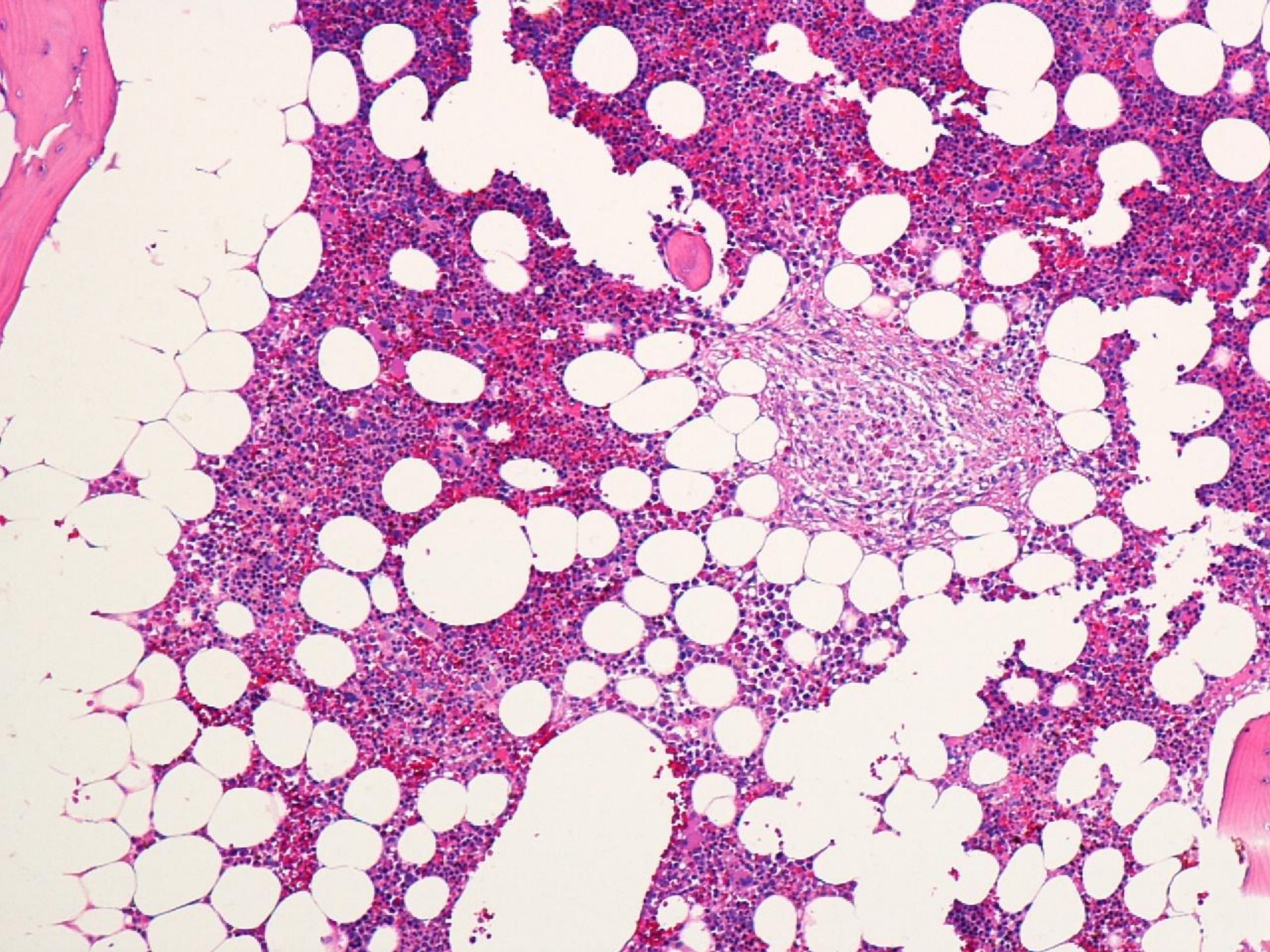

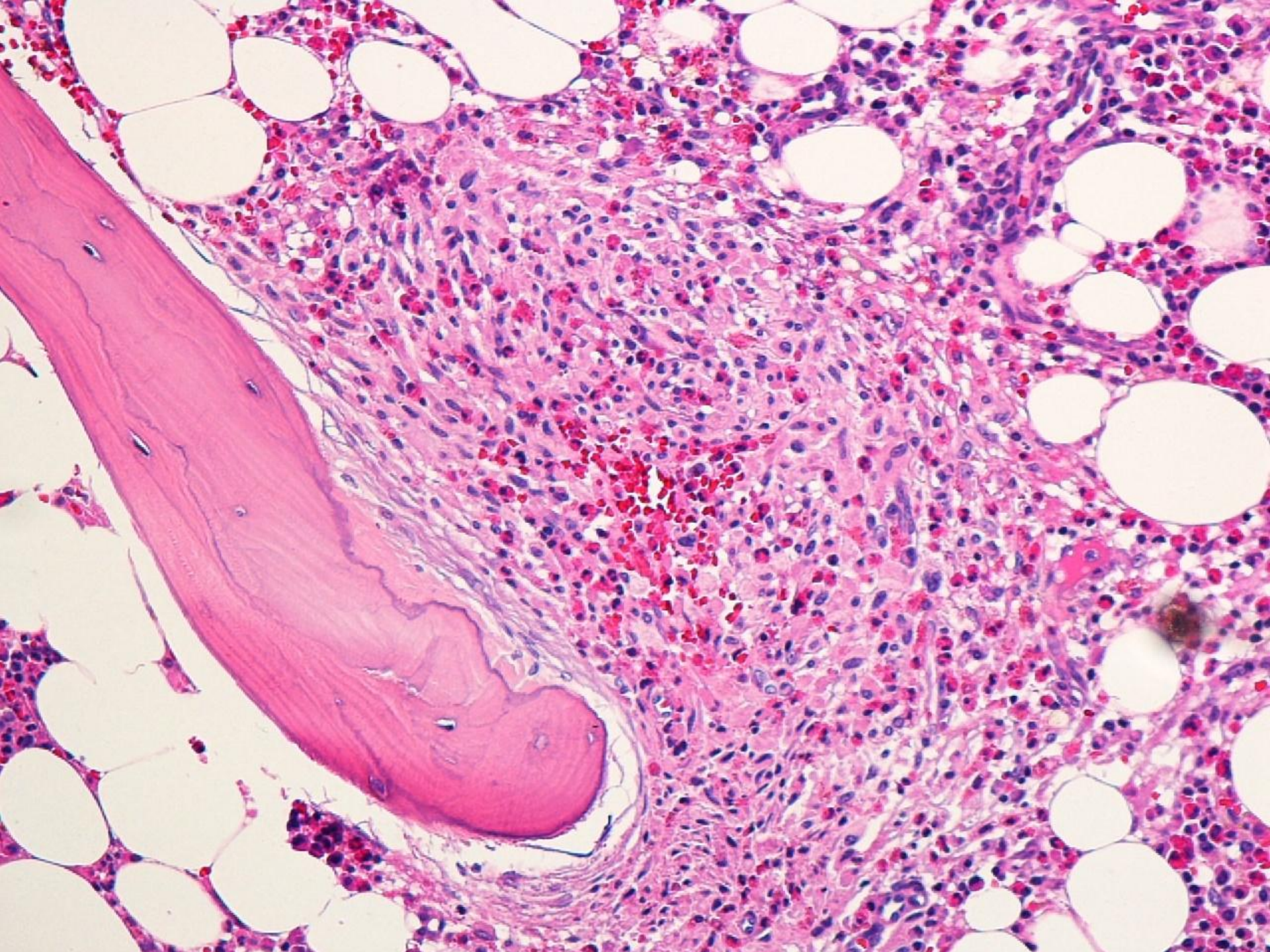

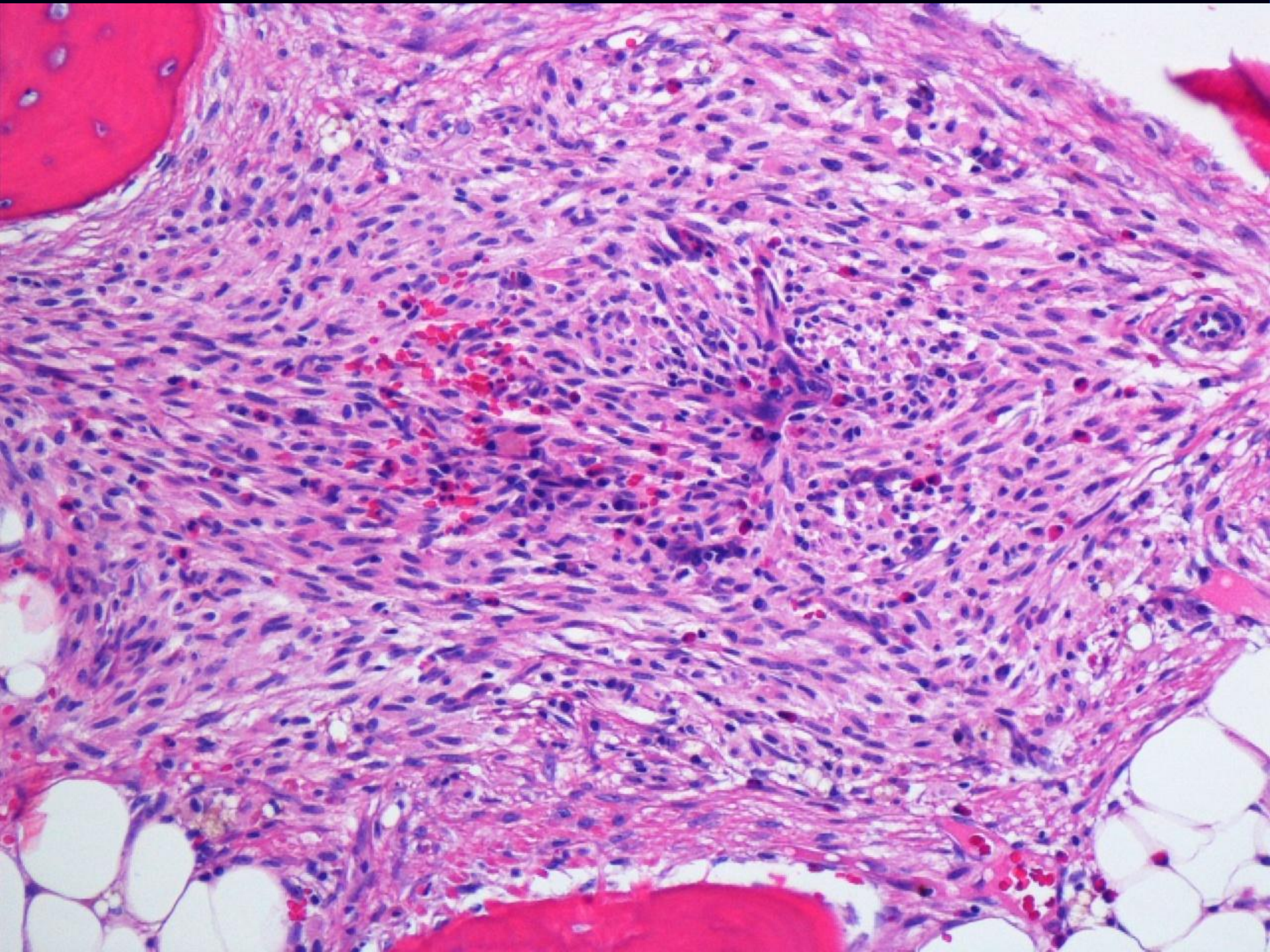

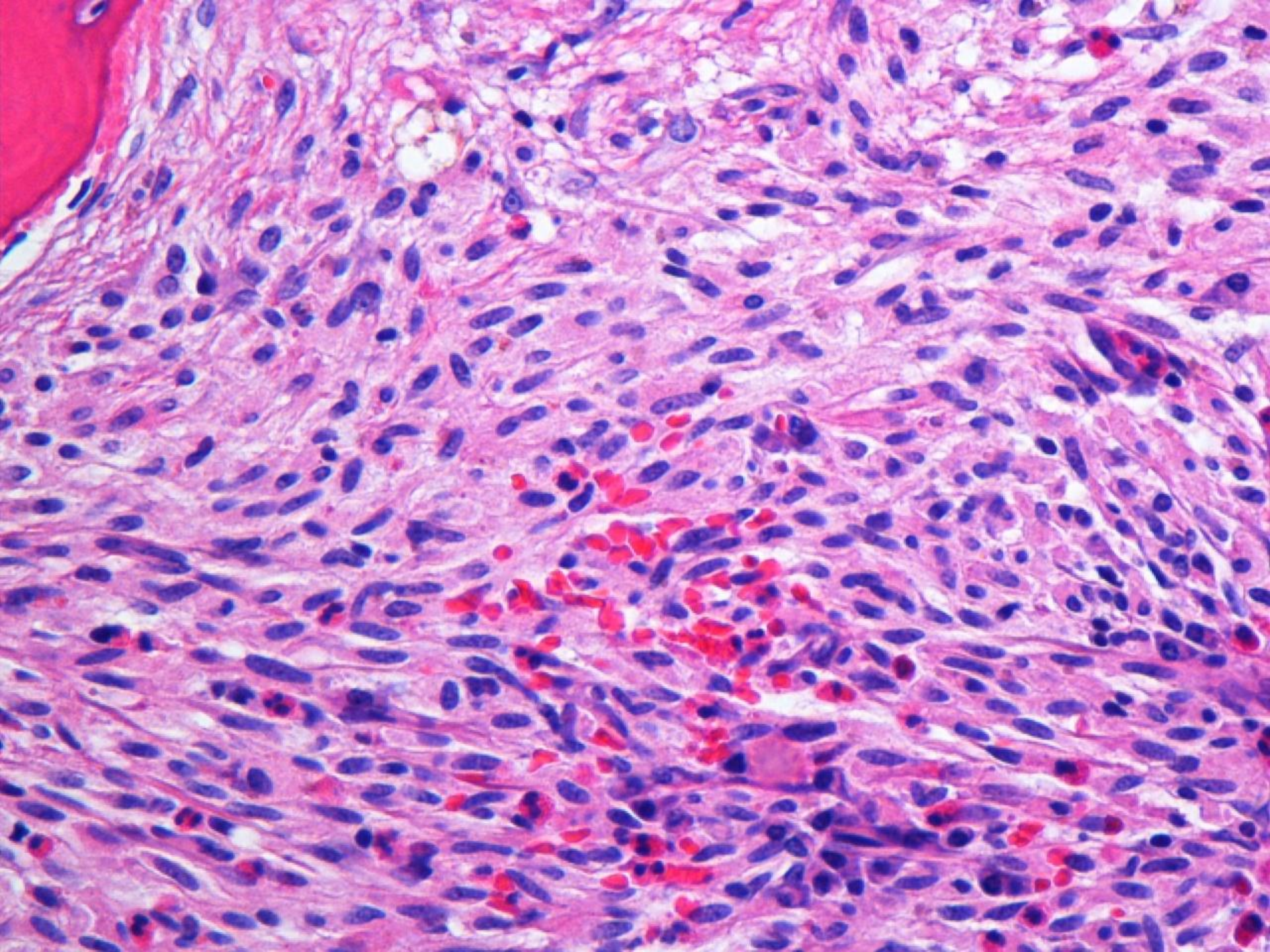

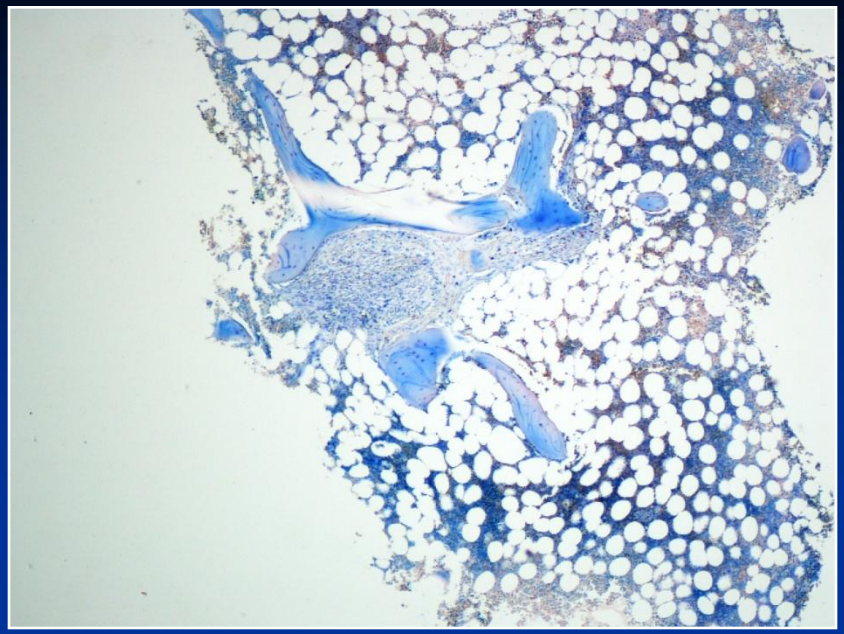

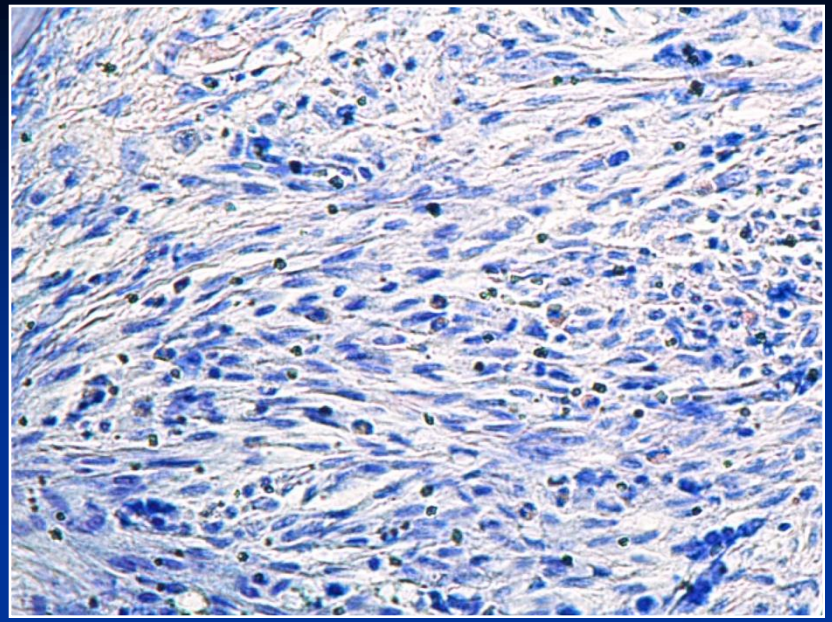

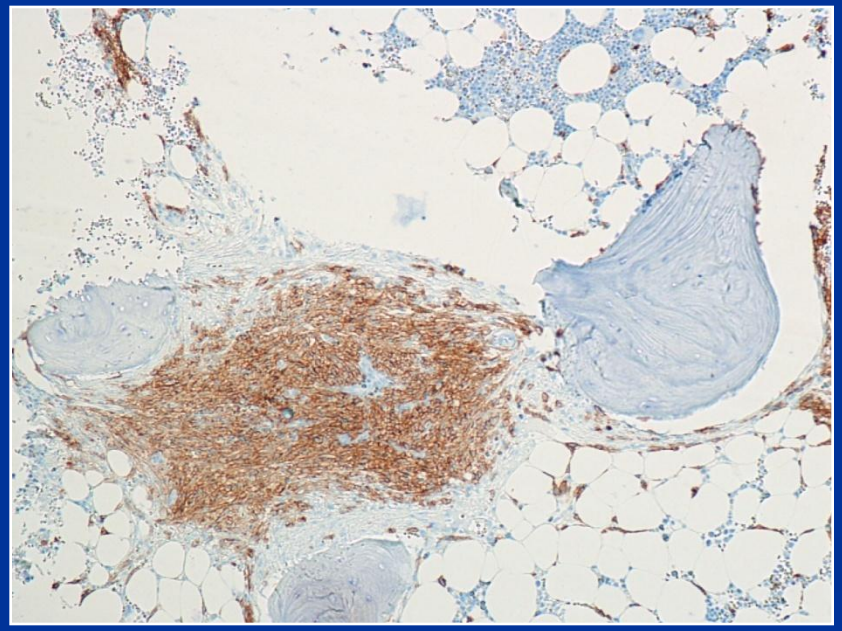

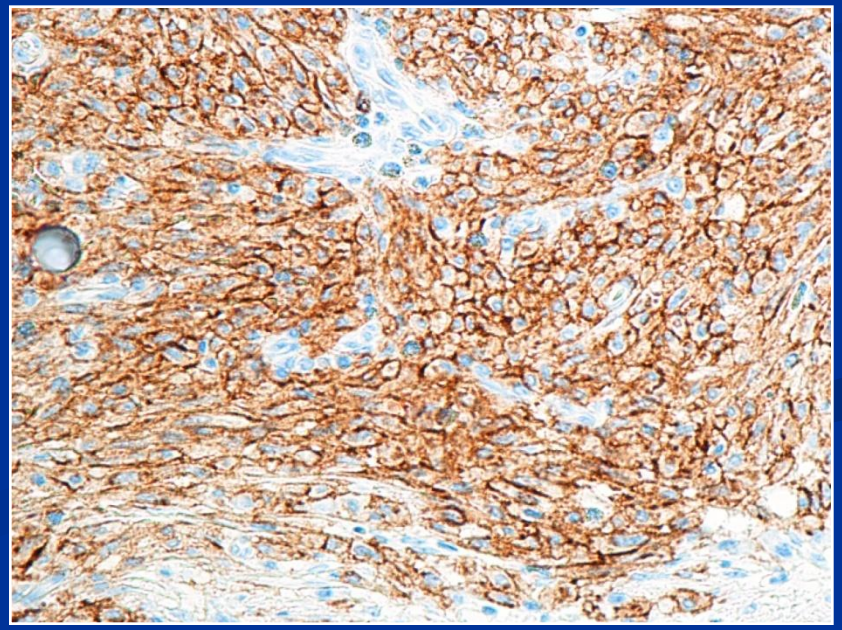

Mastocitosis: Dx diferencial

- ✓ Condiciones reactivas: hiperplasia de mastocitos
- ✓ Neoplasias: leucemia mielomastocítica, leucemia basofílica crónica

Table 1 WHO criteria for systemic mastocytosis

Major criterion	*Minor criteria*
Multifocal, dense aggregates of mast cells (15 or more) detected in sections of bone marrow and confirmed by tryptase immunohistochemistry or other special stains	a. In biopsy section, more than 25% of the masts cells in the infiltrate have atypical morphology, or, of all the mast cells in the aspirate smear, more than 25% are immature or atypical b. Mast cells co-express CD117 with CD2 and/or CD25 c. Detection of *KIT* point mutation at codon 816 in bone marrow, blood, or other extracutaneous organs d. Serum total tryptase persistently >20 ng/ml (not a valid criteria in cases of systemic mastocytosis with associated clonal hematologic non-mast-cell lineage disease)

Diagnosis may be rendered if one major plus one minor or three minor criteria are fulfilled.

Table 1 WHO criteria for systemic mastocytosis

Major criterion	*Minor criteria*
Multifocal, dense aggregates of mast cells (15 or more) detected in sections of bone marrow and confirmed by tryptase immunohistochemistry or other special stains	a. In biopsy section, more than 25% of the masts cells in the infiltrate have atypical morphology, or, of all the mast cells in the aspirate smear, more than 25% are immature or atypical b. Mast cells co-express CD117 with CD2 and/or CD25 c. Detection of *KIT* point mutation at codon 816 in bone marrow, blood, or other extracutaneous organs d. Serum total tryptase persistently >20 ng/ml (not a valid criteria in cases of systemic mastocytosis with associated clonal hematologic non-mast-cell lineage disease)

Diagnosis may be rendered if one major plus one minor or three minor criteria are fulfilled.

1

1

Table 1 WHO criteria for systemic mastocytosis

Major criterion	*Minor criteria*
Multifocal, dense aggregates of mast cells (15 or more) detected in sections of bone marrow and confirmed by tryptase immunohistochemistry or other special stains	a. In biopsy section, more than 25% of the masts cells in the infiltrate have atypical morphology, or, of all the mast cells in the aspirate smear, more than 25% are immature or atypical b. Mast cells co-express CD117 with CD2 and/or CD25 c. Detection of *KIT* point mutation at codon 816 in bone marrow, blood, or other extracutaneous organs d. Serum total tryptase persistently >20 ng/ml (not a valid criteria in cases of systemic mastocytosis with associated clonal hematologic non-mast-cell lineage disease)

Diagnosis may be rendered if one major plus one minor or three minor criteria are fulfilled.

0

3

Table 1 WHO criteria for systemic mastocytosis

Major criterion	*Minor criteria*
Multifocal, dense aggregates of mast cells (15 or more) detected in sections of bone marrow and confirmed by tryptase immunohistochemistry or other special stains	a. In biopsy section, more than 25% of the masts cells in the infiltrate have atypical morphology, or, of all the mast cells in the aspirate smear, more than 25% are immature or atypical b. Mast cells co-express CD117 with CD2 and/or CD25 c. Detection of *KIT* point mutation at codon 816 in bone marrow, blood, or other extracutaneous organs d. Serum total tryptase persistently >20 ng/ml (not a valid criteria in cases of systemic mastocytosis with associated clonal hematologic non-mast-cell lineage disease)

Diagnosis may be rendered if one major plus one minor or three minor criteria are fulfilled.

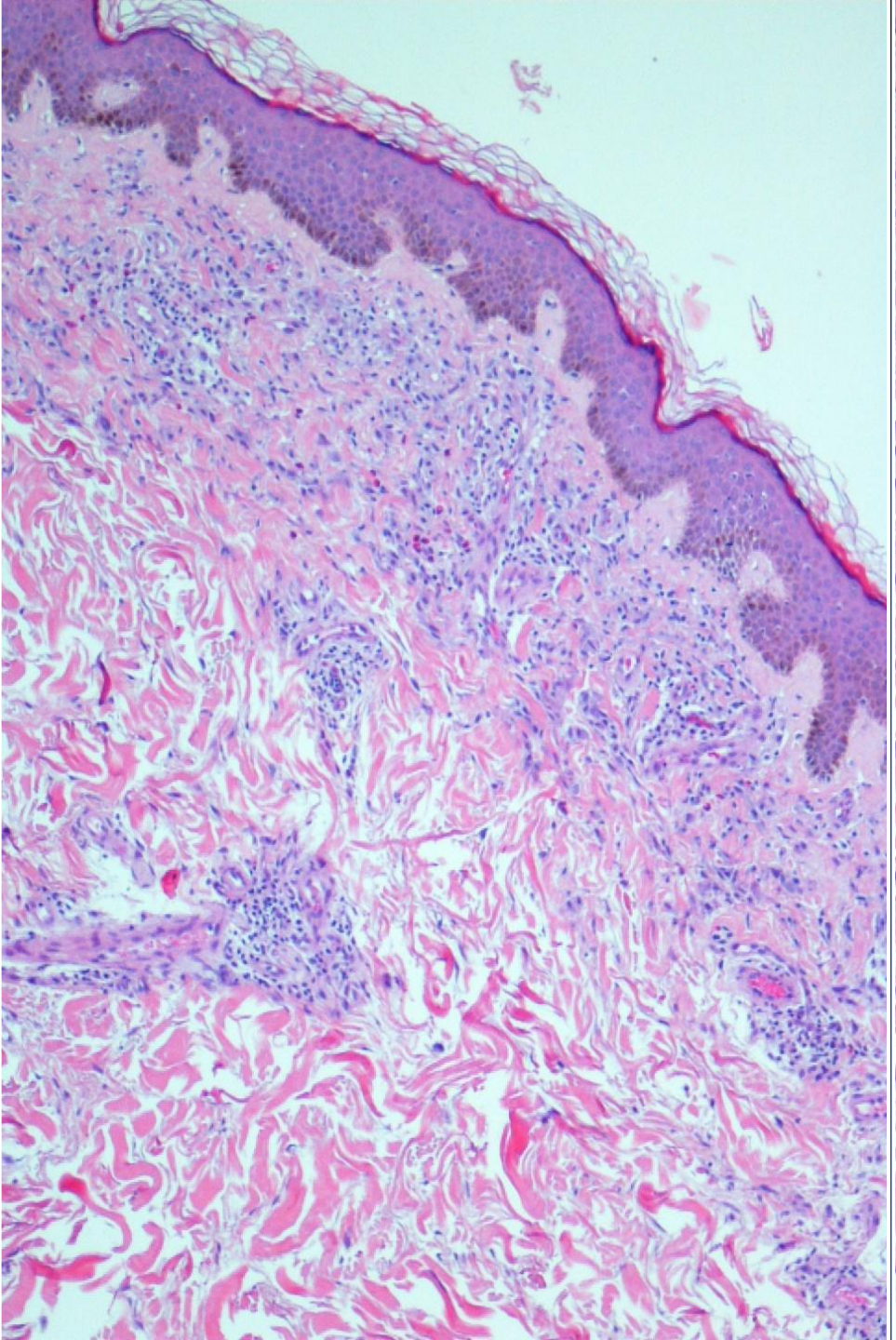

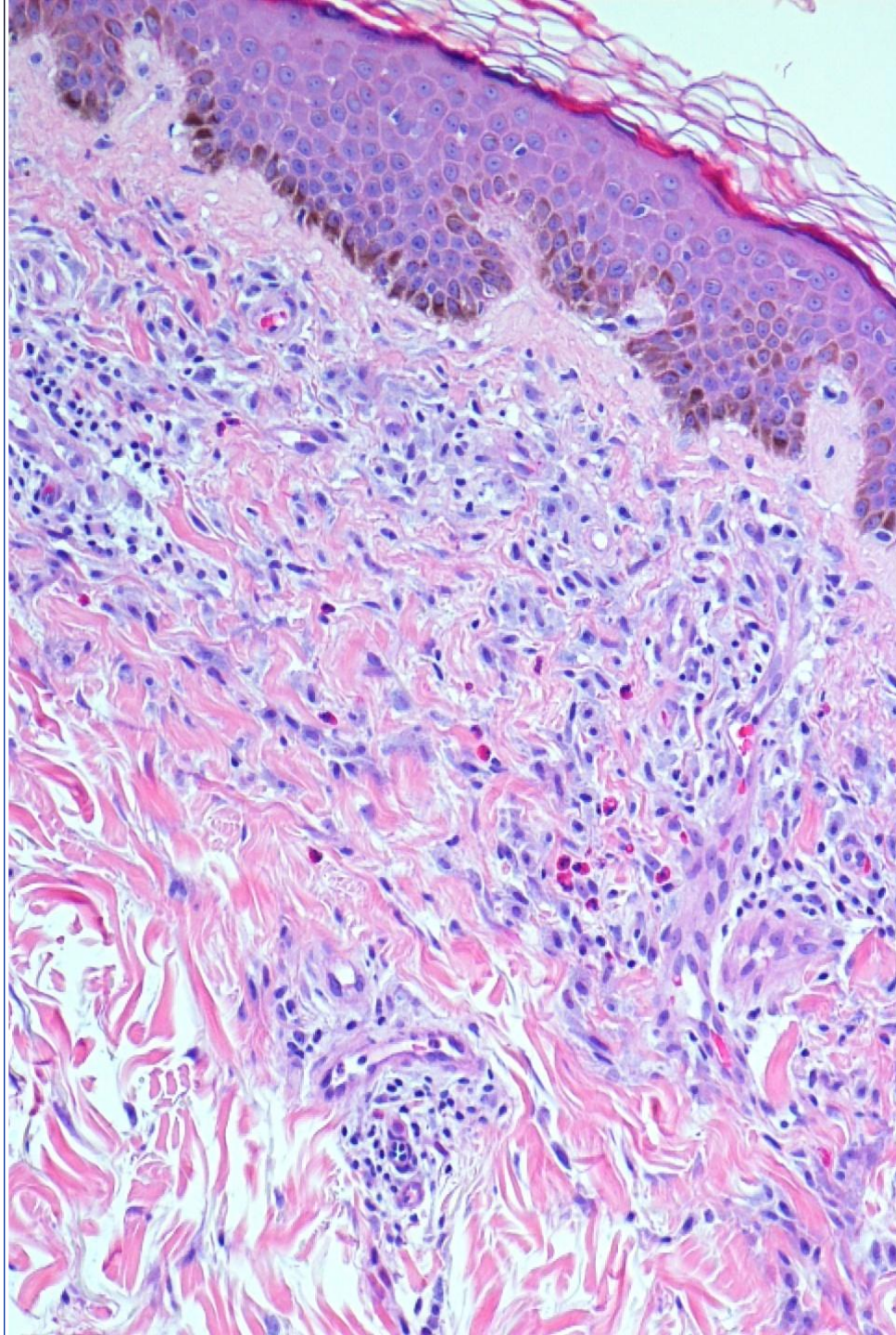

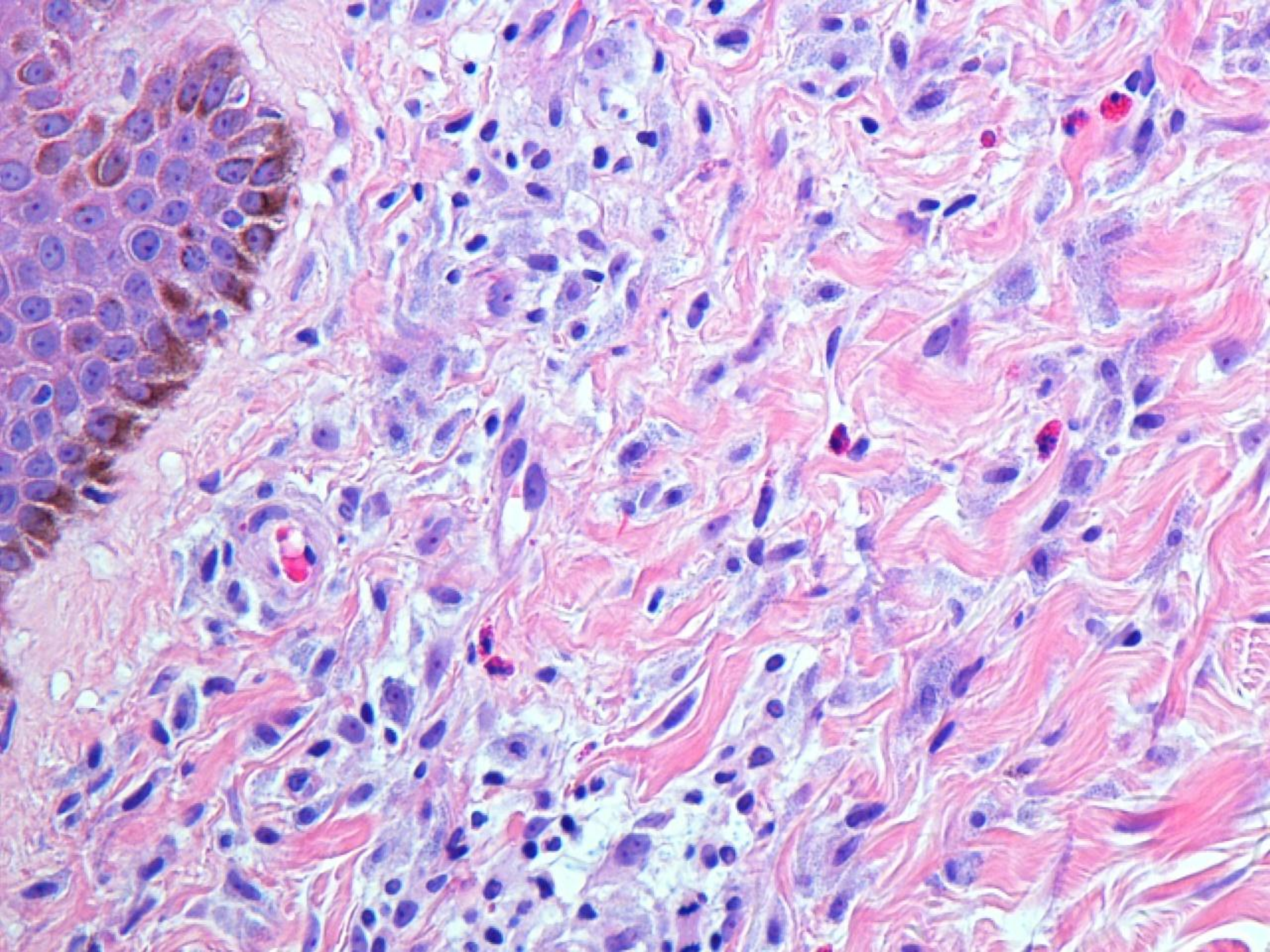

Mastocitosis: categorías OMS

1. Cutánea
2. Sistémica indolente
3. Sistémica con enf hematológica asociada
4. Sistémica agresiva
5. Leucemia de mastocitos
6. Sarcoma de mastocitos
7. Mastocitoma extracutáneo

Mastocitosis: categorías OMS

1. Cutánea
2. **Sistémica indolente**
3. Sistémica con enf hematológica asociada
4. Sistémica agresiva
5. Leucemia de mastocitos
6. Sarcoma de mastocitos
7. Mastocitoma extracutáneo

Problemas diagnósticos

- Morfología atípica: 70%
- Mutaciones de KIT en 2/3 (menor sensibilidad que inmunofenotipaje)
- Triptasa sérica

Systemic mastocytosis diagnostic criteria.

MR Johnson et al. Modern Pathology 2009